This is a digital copy of a book that was preserved for generations on library shelves before it was carefully scanned by Google as part of a project to make the world's books discoverable online.

It has survived long enough for the copyright to expire and the book to enter the public domain. A public domain book is one that was never subject to copyright or whose legal copyright term has expired. Whether a book is in the public domain may vary country to country. Public domain books are our gateways to the past, representing a wealth of history, culture and knowledge that's often difficult to discover.

Marks, notations and other marginalia present in the original volume will appear in this file - a reminder of this book's long journey from the publisher to a library and finally to you.

Usage guidelines

Google is proud to partner with libraries to digitize public domain materials and make them widely accessible. Public domain books belong to the public and we are merely their custodians. Nevertheless, this work is expensive, so in order to keep providing this resource, we have taken steps to prevent abuse by commercial parties, including placing technical restrictions on automated querying.

We also ask that you:

+ *Make non-commercial use of the files* We designed Google Book Search for use by individuals, and we request that you use these files for personal, non-commercial purposes.
+ *Refrain from automated querying* Do not send automated queries of any sort to Google's system: If you are conducting research on machine translation, optical character recognition or other areas where access to a large amount of text is helpful, please contact us. We encourage the use of public domain materials for these purposes and may be able to help.
+ *Maintain attribution* The Google "watermark" you see on each file is essential for informing people about this project and helping them find additional materials through Google Book Search. Please do not remove it.
+ *Keep it legal* Whatever your use, remember that you are responsible for ensuring that what you are doing is legal. Do not assume that just because we believe a book is in the public domain for users in the United States, that the work is also in the public domain for users in other countries. Whether a book is still in copyright varies from country to country, and we can't offer guidance on whether any specific use of any specific book is allowed. Please do not assume that a book's appearance in Google Book Search means it can be used in any manner anywhere in the world. Copyright infringement liability can be quite severe.

About Google Book Search

Google's mission is to organize the world's information and to make it universally accessible and useful. Google Book Search helps readers discover the world's books while helping authors and publishers reach new audiences. You can search through the full text of this book on the web at `http://books.google.com/`

PROPERTY OF THE Shelf No.
Public Library of the City of Boston
BOSTONIA
CONDITA A.D.
1630.
From the Bates Fund.

THE FRANCIS A. COUNTWAY
LIBRARY OF MEDICINE
BOSTON, MA

SEP 08 2003

PROPERTY OF THE Shelf No.
Public Library of the City of Boston
BOSTONIA
CONDITA A.D.
1630.
From the Bates Fund.

THE FRANCIS A. COUNTWAY
LIBRARY OF MEDICINE
BOSTON, MA

SEP 08 2003

TRANSACTIONS

OF THE

PATHOLOGICAL SOCIETY OF LONDON.

VOLUME THE FIFTY-EIGHTH.

COMPRISING THE REPORT OF THE PROCEEDINGS FOR THE SESSION 1906-1907.

THE FRANCIS A. COUNTWAY
LIBRARY OF MEDICINE
BOSTON, MA

SEP 03 2003

Edited by Samuel G. Shattock.

LONDON:
SMITH, ELDER & CO., 15 WATERLOO PLACE.
1907.

Bts.
*7786,3 Mar. 22. 1909
7,58 E
Cont.

THE Council think it right to state that the authors of the several communications herein published are alone responsible for the statements made or the views put forward by them.

PUBLIC LIBRARY
OF THE
CITY OF BOSTON

TABLE OF CONTENTS

OF VOLUME LVIII.

	PAGE
List of Presidents of the Society	iv
List of Officers and Members	v
Report by the Secretary	xxix
List of Communications made during the Session 1906–1907	xxxi
List of Plates	xxxii
List of Figures in the Text	xxxiii
President's Address	xxxv
Communications	1
Index	371

Presidents of the Society.

ELECTED

1846 CHARLES J. B. WILLIAMS, M.D., F.R.S.
1848 CHARLES ASTON KEY.
1850 PETER MERE LATHAM, M.D.
1852 CÆSAR H. HAWKINS, F.R.S.
1853 BENJAMIN GUY BABINGTON, M.D., F.R.S.
1855 JAMES MONCRIEFF ARNOTT, F.R.S.
1857 SIR THOMAS WATSON, BART., M.D., F.R.S.
1859 SIR WILLIAM FERGUSSON, BART., F.R.S.
1861 JAMES COPLAND, M.D., F.R.S.
1863 SIR PRESCOTT G. HEWETT, BART., F.R.S.
1865 THOMAS BEVILL PEACOCK, M.D.
1867 SIR JOHN SIMON, K.C.B., D.C.L., F.R.S.
1869 SIR RICHARD QUAIN, BART., M.D., LL.D., F.R.S.
1871 JOHN HILTON, F.R.S.
1873 SIR WILLIAM JENNER, BART., M.D., G.C.B., D.C.L., F.R.S.
1875 GEORGE D. POLLOCK.
1877 CHARLES MURCHISON, M.D., LL.D., F.R.S.
1879 JONATHAN HUTCHINSON, F.R.S.
1881 SIR SAMUEL WILKS, BART., M.D., F.R.S.
1883 JOHN WHITAKER HULKE, F.R.S.
1885 JOHN SYER BRISTOWE, M.D., F.R.S.
1887 SIR JAMES PAGET, BART., D.C.L., LL.D., F.R.S.
1889 WILLIAM HOWSHIP DICKINSON, M.D.
1891 SIR GEORGE MURRAY HUMPHRY, M.D., LL.D., F.R.S.
1893 FREDERICK WILLIAM PAVY, M.D., LL.D., F.R.S.
1895 HENRY TRENTHAM BUTLIN, D.C.L.
1897 JOSEPH FRANK PAYNE, M.D.
1899 WILLIAM WATSON CHEYNE, C.B., F.R.S.
1902 SIR JOHN BURDON SANDERSON, BART., M.D., D.C.L., F.I.S.
1906 PHILIP HENRY PYE-SMITH, M.D., F.R.S.

OFFICERS AND COUNCIL

OF THE

Pathological Society of London,

ELECTED AT

THE GENERAL MEETING, JUNE 4TH, 1907,

FOR THE SESSION 1906–1907 AS A PROVISIONAL COMMITTEE PENDING THE INCORPORATION OF THE SOCIETY INTO THE ROYAL SOCIETY OF MEDICINE.

President.

P. H. PYE-SMITH, M.D., F.R.S.

Vice-Presidents.

W. P. HERRINGHAM, M.D. (1)
SIR ALMROTH WRIGHT, M.D., F.R.S. (2)
F. W. PAVY, M.D., F.R.S. (3)
F. G. HOPKINS, F.R.S. (4)

Treasurer.

H. H. CLUTTON.

Council.

Members of Committee of Section A.

E. F. BUZZARD, M.D.
J. H. DRYSDALE, M.D.
W. S. LAZARUS-BARLOW, M.D.
F. J. POYNTON, M.D.
C. G. SELIGMANN, M.D.
H. THURSFIELD, M.D.
F. PARKES WEBER, M.D.
A. WHITFIELD, M.D.

Members of Committee of Section B.

G. DEAN, M.D.
W. D'ESTE EMERY, M.D.
K. W. GOADBY.
R. T. HEWLETT, M.D.
T. J. HORDER, M.D.
D. NABARRO, M.D.

Members of Committee of Section C.

C. J. MARTIN, M.D., F.R.S.
M. S. PEMBREY, M.D.
J. LORRAIN SMITH, M.D.
E. H. STARLING, M.D., F.R.S.

Members of Committee of Section D.

O. GRÜNBAUM, M.D.
R. HUTCHISON, M.D.
J. B. LEATHES, M.B.

Sectional Secretaries.

Section A.
G. F. STILL, M.D.

Section B.
W. BULLOCH, M.D.

Section C.
T. G. BRODIE, M.D., F.R.S.

Section D.
A. E. GARROD, M.D.

General Secretary and Editor of the 'Transactions.'

S. G. SHATTOCK.

Trustees.

T. BRYANT, M.Ch.
J. F. PAYNE, M.D.
H. MORRIS, M.B.

NOTE.—Section A: Pathological Anatomy and Histology. Section B: Bacteriology. Section C: Experimental Pathology. Section D: Chemical Pathology.
(1) Chairman of Section A. (2) Chairman of Section B.
(3) Chairman of Section C. (4) Chairman of Section D.

Committees.

The members of Council forming each Section (A, Pathological Anatomy and Histology; B, Bacteriology; C, Experimental Pathology; D, Chemical Pathology) constitute committees of reference in the subjects enumerated, with power to add to their numbers in particular cases.

*** *Members are requested to inform the General Secretary of any change of address, etc., which may be necessary.*

LIST OF MEMBERS OF THE SOCIETY.

Honorary Members.

BOUCHARD, C., M.D., Professor of General Pathology, Paris.
CHAUVEAU, A., M.D., Professor of Physiology at the Medical School of Lyons.
KOCH, R., M.D., Director of the Institute for Infective Diseases, Berlin.
The Right Honourable Lord LISTER, F.R.S., F.R.C.S., 12, Park crescent, Portland place, W.
METCHNIKOFF, E., M.D., Chef de Service à l'Institut Pasteur, Paris.
ORTH, J., M.D., Professor of Pathological Anatomy in the University of Berlin.
VON RECKLINGHAUSEN, F. D., Director of the Pathological Institute, Strassburg.
RINDFLEISCH, E., M.D., Professor of Pathological Anatomy in the University of Bonn.
ROUX, P. P. E., M.D., Sous-directeur de l'Institut Pasteur, Paris.
SALOMONSEN, C. J., Professor of General Pathology and Bacteriology in the University of Copenhagen.
WELCH, W. H., M.D., Professor of Pathology, Johns Hopkins University, Baltimore.
WILKS, SIR SAMUEL, Bart., M.D., LL.D., F.R.S., F.R.C.P., 8, Prince Arthur Road, Hampstead, N.W.
ZIEGLER, E., M.D. Professor of Pathological Anatomy, Freiburg.

EXPLANATION OF ABBREVIATIONS.

P.—President.
T.—Treasurer.
V.-P.—Vice-President.
S.—Secretary.
C.—Member of Council.
E.—Editor of the 'Transactions.'

The surnames of Members who have compounded for their subscriptions are printed in this type (TYPE). The surnames of Members who have paid the Composition Fee for the 'Transactions are printed in this type (**Type**).

GENERAL LIST OF MEMBERS.

Elected

1879 **ABERCROMBIE**, John, M.D., Augill Brough, Westmorland. (C. 1897-1900.)

1896 Abrahams, Bertram Louis, B.Sc., M.B., 14, Welbeck street, W.

1883 Acland, Theodore Dyke, M.D., 19, Bryanston square, W. (C. 1892-4.)

1891 Adami, J. George, M.A., M.D., Montreal, Canada.

1890 Adams, James, M.D., 4, Chiswick place, Eastbourne.

1848 **AIKIN**, Charles A., 12, Ladbroke terrace, W. (C. 1864-6.)

1872 Aikin, Charles Edmund, Llandrillo, Corwen, North Wales.

1897 Alcock, Samuel K., M.D., Portland House, Burslem.

1882 **ALLCHIN**, William Henry, M.D., 5, Chandos street, W.

1884 Anderson, Alexander Richard, 5, East Circus street, Nottingham.

1897 Andrewes, Frederick W., M.D., 31, Hampstead lane, Highgate, N. (C. 1900—6. Com. Sect. B, 1901—6.)

1902 Armour, Donald, M.B., 89, Harley street, W.

1883 Ashby, Henry, M.D., 13, St. John street, Manchester.

1863 Bagshawe, Frederick, M.A., M.D., 35, Warrior square, St. Leonard's-on-Sea.

1904 Bailey, William Henry, M.D., Featherstone Hall, Southall, Middlesex.

1902 Bainbridge, F. A., M.B., 1, Vernon Chambers, Southampton row, W.C.

1856 **Balding**, Daniel Barley, Royston, Herts.

1881 Ballance, Charles A., M.S., 106, Harley street, W. (C. 1890-2. C. Com. Sect. C, 1901—4. S. 1899—1901.)

1875 Barker, Arthur E. J., 87, Harley street, W. (C. 1884-6. V.P. 1896-7.)

1899 Barker, A. J. G., Kuching, Sarawak, Borneo.

1885 Barling, Gilbert, M.B., 87, Cornwall street, Newhall street, Birmingham. (C. 1894-7.)

1901 Barnard, Harold L., M.S., 21, Wimpole street, W.

1874 **BARLOW**, Sir Thomas, Bart., K.C.V.O., M.D., B.S., 10, Wimpole street, W. (C. 1879-81. V.-P. 1894-6.)

1899 Barratt, John Ogilthorpe Wakelin, M.D., Thompson-Yates Laboratory, University College, Liverpool.

1877 Barrow, A. Boyce, 8, Upper Wimpole street, W.

1881 Barrs, Alfred George, M.D., 22, Park place, Leeds.

1853 **BARWELL**, Richard, 55, Wimpole street, W. (C. 1862-4. V.-P. 1889-90.)

Elected

1861 **BASTIAN**, H. CHARLTON, M.A., M.D., F.R.S., Chesham Bois, Bucks. (C. 1869-71. V.-P. 1885-7.)

1877 BATEMAN, ARTHUR W., B.A., Tenterfield, New South Wales.

1895 BATTEN, FREDERICK E., M.D., 33, Harley street, W. (C. Com. Sect. A, 1903-5.)

1876 **BATTESON**, JOHN, 188, Goldhawk road, Shepherd's Bush.

1882 BATTLE, WILLIAM HENRY, 49, Harley street, W. (C. 1898—1901.)

1870 BÄUMLER, CHRISTIAN G. H., M.D., The University, Freiburg, in Baden Baden, Germany.

1892 BEADLES, CECIL F., The Clergy House, Englefield Green, Surrey. (C. 1898—1901.)

1879 BEALE, EDWIN CLIFFORD, M.B., 23, Upper Berkeley street, W.

1856 BEALEY, ADAM, M.D., M.A., Felsham Lodge, Hollington park, St. Leonard's-on-Sea.

1904 BEATTIE, JAMES M., M.D., Pathological Department, University of Sheffield.

1897 BEDDARD, ARTHUR P., M.D., 44, Seymour street, W.

1865 BEEBY, WALTER, M.D., Rapollo, Liguria, Italy (Nov.—May), and Varallo, Valsesia (May, June, Sept., Oct.).

1880 **BEEVOR**, CHARLES EDWARD, M.D., 135, Harley street, W. (C. 1888-90.)

1886 BENNETT, FREDERICK JOSEPH, 17, George street, Hanover square, W.

1877 BENNETT, Sir WILLIAM HENRY, K.C.V.O., 1, Chesterfield street, W. (C. 1891-3.)

1889 BENTLEY, ARTHUR, J. M., M.D., Mena House, Pyramids, Cairo, Egypt.

1878 BERNARD, FRANCIS R., M.D., Prawls, Stone, near Tenterden, Kent.

1904 BERNSTEIN, JULIUS M., M.B., Erskine Chambers, 36, Lincoln's Inn Fields, W.C.

1882 BERRIDGE, WILLIAM ALFRED, Redhill, Surrey.

1886 BERRY, JAMES, B.S., 21, Wimpole street, W. (C. 1895-7.)

1903 BEVERIDGE, WILFRID WILLIAM OGILVIE, M.B., R.A.M.C., D.S.O., Royal Army Clothing Department, Grosvenor Road, S.W.

1856 **Bickersteth**, EDWARD R., 2, Rodney street, Liverpool.

1882 BINDLEY, PHILIP HENRY, M.B. Address uncommunicated.

1906 BIRT, CECIL, Queen Alexandra Hospital, Millbank, S.W.

1865 BISSHOPP, JAMES, Mount Pleasant, Tunbridge Wells.

1889 BLACK, ROBERT, M.D., 14, Pavilion Parade, Brighton.

1863 BLANCHET, JEAN B., M.D., M.S., Montreal, Quebec, Canada.

1879 BOILEAU, J. P. H., M.D., Brigade-Surgeon, Army.

1900 BOKENHAM, THOMAS JESSOPP, 10, Devonshire street, Portland place, W.

1904 BOLTON, CHARLES, M.D., 16, Devonshire street, Portland place, W.

1900 BOLTON, JOSEPH SHAW, M.D., B.S., B.Sc., East Sussex County Asylum, Hellingly S.O., Sussex.

1902 BONNEY, W. F. VICTOR, M.D., M.S., 30, The Manor House, Marylebone road, W.

1869 BOURNE, WALTER, M.D. (Travelling).

1861 BOWER, RICHARD NORRIS (Travelling).

Elected

1881 Bowlby, Anthony A., C.M.G., 24, Manchester square, W. (M.G.C. 1884—1900. C. 1886-8, 1895-7. S. 1893-5. V.-P. 1898—1900.)

1895 Box, Charles R., M.D., 2, Devonshire place, Portland Place, W.

1892 Boyce, Rubert William, M.S., F.R.S., Thompson Yates Laboratories, Liverpool University, Liverpool.

1904 Boycott, Arthur Pagin, B.Sc., M.B., B.Ch., Guy's Hospital, S.E.

1882 Boyd, Stanley, B.S., 134, Harley street, W. (C. 1893-6. V.-P. 1897-9.)

1889 Bradford, John Rose, M.D., F.R.S. 8, Manchester square, W. (C. 1897—1900. C. Com. Sect. C, 1902-5. S. 1900-2.)

1880 Bramwell, Byrom, M.D., 23, Drumsheugh Gardens West, Edinburgh.

1904 Branson, William P. S., M.B., 59, Gordon square, W.C.

1889 Bredin, J. Noble, The Vines, Sutton Valence, Maidstone.

1902 Brewerton, Elmore W., 84, Wimpole street, W.

1877 Bridges, Robert, M.B., M.A., Manor House, Yattendon, Berks.

1867 **Bridgewater,** Thomas, LL.D. Glas., M.B. Lond., Harrow-on-the-Hill, Middlesex.

1873 Briggs, Jacob Myers, M.D., Coeymans, New York, U.S.A.

1868 Bright, George Charles, M.D., Cannes, Alpes Maritimes, France.

1902 Brincker, John Augustus Herman, M.B., B.C., 57, Great Ormond street, W.C.

1857 Briscoe, John, 5, Broad street, Oxford.

1904 Briscoe, John Charlton, M.B., 110, Harley street, W.

1885 Briscoe, John F., Westbrooke House, Alton, Hants.

1903 Broadbent, Sir J. F. H., Bart., M.D., 35, Seymour street, W.

1886 Brockatt, Andrew Alexander, M.D., Hazeldean, Malvern.

1884 Brodie, Charles Gordon, Fernhill, Wootton Bridge, Isle of Wight.

1899 Brodie, Thomas Grigor, M.D., F.R.S. (Hon. Secretary, Section C.), 4, Lancaster terrace, Regent's Park, N.W. (C. 1900—1901. S. Com. Sect. C, 1901-7.)

1871 Brown, Frederick Gordon, 17, Finsbury circus, E.C.

1903 Browne, H. S. D., 78, High street, Winchester.

1877 Bruce, J. Mitchell, M.D., 23, Harley street, W.

1902 Bruce, Samuel Noble, 15, Queensborough terrace, W.

1890 Brunton, Sir T. Lauder, M.D., D.Sc., LL.D., F.R.S., 10, Stratford place, W.

1855 **BRYANT,** Thomas, M.Ch. (Trustee), 42, Norfolk square, W. (C. 1863-6. V.-P. 1877-9.)

1890 Buckland, Francis O., M.A., M.B., C.M., Brockenhurst, Hants.

1899 Bulloch, William, M.D., M.B., C.M. (Hon. Secretary, Sect. B), 66, Holland road, Kensington, W. (C. Com. Sect. B, 1901-3. S. Com. Sect. B, 1903-7.)

1891 Burghard, Frédéric François, M.D., M.S., 86, Harley street, W.

1880 Burton, Samuel Herbert, M.B., 50, St. Giles' street, Norwich.

1900 Busch, Joseph Paul-Zum, M.D., Chiswell House, 133, Finsbury Pavement, E.C.

1903 Bushnell, Frank George, M.D., 11, New Parade, Worthing.

1872 **BUTLIN,** Henry Trentham, D.C.L., 82, Harley street, W. (M.G.C. 1875-86. C. 1876-8, 1887-9. S. 1884-6. V.-P. 1891-2. P. 1895-7.)

Elected

1883 **BUXTON**, Dudley W., M.D., 82, Mortimer street, W.

1903 Buzzard, Edward Farquhar, M.D., 33, Harley street, W. (C. Com. Sect. A, 1906-7.)

1856 **BUZZARD**, Thomas, M.D., 74, Grosvenor street, W. (C. 1869-70. V.-P. 1881-3.)

1901 Caddy, Adrian, M.B., 2/2, Harington street, Calcutta.

1899 Caddy, Arnold, 2/2, Harington street, Calcutta.

1893 Caley, Henry Albert, M.D., 24, Upper Berkeley street, W.

1897 Calvert, James, M.D., 113, Harley street, W.

1905 Cammidge, Percy John, M.B., 2, Beaumont street, Portland place, W.

1892 Campbell, Henry Johnstone, M.D., 36, Manningham lane, Bradford.

1905 Candler, John Pycock, M.D., B.C., Pathological Laboratory, Claybury Asylum, Woodford Bridge, Essex.

1897 **Carwardine**, Thomas, M.S., 16, Victoria square, Clifton, Bristol.

1877 Casson, John Hornsby, H.B.M. Legation, Teheran, Persia.

1864 Cay, Charles Vidler, Deputy Surgeon General. Address uncommunicated.

1869 Chaffers, Edward, Abbotsrood, Milnthorpe road, Eastbourne.

1884 Chavasse, Sir Thomas Frederick, M.D., C.M., 22, Temple row, Birmingham.

1901 Cheatle, G. Lenthal, 117, Harley Street, W.

1879 Cheyne, William Watson, C.B., M.B., C.M., F.R.S., 75, Harley street, W. (C. 1885-7. M.G.C. 1890-6. V.-P. 1892-3. P. 1899—1902.)

1873 Chisholm, Edwin, M.D., 44, Rosslyn gardens, Darlinghurst, near Sydney, New South Wales [care of Messrs. Dawson, 121, Cannon street, E.C.].

1865 **CHURCH**, Sir William Selby, Bart., K.C.B., 130, Harley street, W. (M.G.C. 1869-74. C. 1871-3. V.-P. 1894-6.)

1868 **CHURCHILL**, Frederick, M.D., 4, Cranley gardens, Queen's gate, S.W.

1898 Churton, Thomas, M.D., 35, Park square, Leeds.

1861 **CLAPTON**, Edward, M.D., Towercroft, 41, Eltham road, Lee, S.E.

1872 Clark, Andrew, 71, Harley street, W.

1886 Clark, Francis William, M.B., Victoria, Hong Kong.

1885 Clarke, John Michell, M.D., 28, Pembroke road, Clifton, Bristol.

1881 Clarke, W. Bruce, M.B., 51, Harley street, W. (C. 1892-4.)

1904 Cleland, John Burton, M.D., Central Board of Health, Perth, W. Australia.

1899 Cleveland, Arthur John, M.D., 45, Shooter's Hill road, Blackheath Park, S.E.

1875 **CLUTTON**, Henry Hugh, M.A. (Treasurer), 2, Portland place, W. (C. 1884-6. M.G.C. 1889-94. V.-P. 1892-3. T. 1906-7.)

1865 **Coates**, Charles, M.D., 10, Circus, Bath.

1892 Cole, Robert Henry, M.D., Moorcroft, Hillingdon, Uxbridge.

1886 Collier, William, M.D., High street, Oxford.

1888 Collins, Sir William Job, M.P., M.D., M.S., 1, Albert terrace, Regent's park, N.W.

Elected

1888 COLMAN, WALTER STACY, M.D., 9, Wimpole street, W.

1882 COLQUHOUN, DANIEL, M.D., Dunedin, New Zealand.

1905 COLWELL, HECTOR ALFRED, M.B., 55, Bridge road, Hornsey, N.

1896 CONNELL, W. T., M.D., Kingston, Canada.

1891 COOK, HERBERT G. GRAHAM, M.D., 22, Newport road, Cardiff.

1858 COOKE, R. T. E. BARRINGTON, 15, St. Nicholas cliff, Scarborough, Yorkshire.

1866 COOMBS, ROWLAND HILL, M.D., Mill street, Bedford.

1892 COOPER, C. DUDLEY [address uncommunicated].

1903 COOPER, PERCY ROBERT, M.D., B.Sc., Glenthorne, The Downs, Bowdon, Cheshire.

1900 CORNER, EDRED MOSS, M.B., 37, Harley street, W.

1899 CORNER, HARRY, M.D., Brook House, Southgate, N.

1861 **COUPER**, JOHN, 80, Grosvenor street, W. (C. 1870-2.)

1873 **COUPLAND**, SIDNEY, M.D., 16, Queen Anne street, W. (M.G.C. 1882-6. C. 1878-81, 1889-91. S. 1886-8. V.-P. 1892-3. T. 1894—1903.)

1904 COVENTON, CHARLES ARTHUR, 111, Woodstock road, Oxford.

1884 CRICHTON, GEORGE, M.D., 114, Lexham gardens, Kensington, W.

1873 CRIPPS, WILLIAM HARRISON, 2, Stratford place, W. (C. 1883-5. V.-P., 1893-4.)

1877 **CROCKER**, HENRY RADCLIFFE, M.D., 121, Harley street, W. (C. 1887-9, V.-P. 1897-9.)

1886 CROOKSHANK, EDGAR, M.B., Saint Hill, East Grinstead, Sussex. (C. 1890-3. V.-P., 1900-2.)

1875 CROSS, FRANCIS RICHARDSON, 5, The Mall, Clifton, Bristol.

1889 CUFF, ROBERT, M.B., 40, Filey road, Scarborough.

1871 CUMBERBATCH, A. ELKIN, 11, Park crescent, Portland place, W.

1893 CURTIS, HENRY JONES, M.D., 58, Harley Street, W.

1884 DAKIN, W. RADFORD, M.D., B.S., 8A, Grosvenor street, Grosvenor square, W.

1883 DALTON, NORMAN, M.D., 4, Mansfield street, W. (C. Com. Sect. A, 1901-3.)

1883 DAVIS, EDWIN HARRY, West Hartlepool.

1859 **Davis**, FRANCIS WILLIAM, R.N.

1879 DAVY, HENRY, M.D., 29, Southernhay, Exeter.

1894 DAWSON, BERTRAND, M.D., 32, Wimpole street, W.

1899 DEAN, GEORGE, M.D., The Lister Institute of Preventive Medicine, Queensberry Lodge, Elstree, Herts. (C. Com. Sect. B, 1905-7.)

1889 DEAN, HENRY PERCY, M.B., M.S., 69, Harley street, W. (C. 1900—1901.)

1905 DEAN, HENRY RAY, M.B., B.Ch., 53, Elm Park gardens, S.W.

1899 DE CHAZAL, EDMOND LUCIEN, M.D., Port Louis, Mauritius.

1887 DELÉPINE, SHERIDAN, M.B., C.M., The Owens College, Manchester. (C. 1899—1901.)

1880 DENT, CLINTON T., 61, Brook street, W.

Elected

1871 DICKINSON, EDWARD HARRIMAN, M.A., M.D. Address uncommunicated.

1858 **DICKINSON**, WILLIAM HOWSHIP, M.D., 10, Stanhope place, Marble arch, W. (C. 1866-8. S. 1869-71. V.-P. 1872-4. P. 1889-90.)

1900 DIXON, W. E., M.D., Hazelwood, Netherby road, Honor Oak, S.E., and Pathological Laboratory, Cambridge.

1872 DIVER, EBENEZER, M.D., 95, London road, Portsmouth.

1872 DORAN, ALBAN HENRY GRIFFITHS, 9, Granville place, W. (C. 1882-4. V.-P. 1894-6.)

1877 DRAKE-BROCKMAN, EDWARD F., 14, Welbeck street, W.

1893 DRYSDALE, JOHN HANNAH, M.D., 11, Devonshire place, W. (C. Com. Sect. A, 1904-7.)

1865 **DUCKWORTH**, Sir DYCE, M.D., LL.D., 28, Grosvenor place, S.W. (C. 1877.)

1902 DUDGEON, L. S., 6, Powis gardens, Bayswater, W.

1871 DUKES, CLEMENT, M.D., B.S., Sunnyside, Rugby.

1877 DUNBAR, J. J. MACWHIRTER, M.D., Hedingham House, Clapham common, S.W.

1889 DUNCAN, JOHN, M.D., St. Petersburg.

1884 DUNN, LOUIS ALBERT, M.B., M.S., 51, Devonshire street, Portland place, W.

1879 DURHAM, FREDERIC, M.B., 52, Brook street, W.

1899 EASTES, GEORGE LESLIE, M.B., B.Sc., 35, Gloucester terrace, W.

1901 EASTWOOD, A., M.D., Tuberculosis Commission, Stansted, Essex.

1893 ECCLES, WILLIAM MCADAM, M.S., 124, Harley street, W.

1892 EDDOWES, ALFRED, M.D., 28, Wimpole street, W.

1904 EDMUNDS, ARTHUR, M.S., 30, Welbeck street, W.

1880 **EDMUNDS**, WALTER, M.C., 2, Devonshire place, Portland place, W. (C. 1892-4. C. Com. Sect. C, 1901-2.)

1889 ELAM, WILLIAM HENRY, New Barnet, Herts.

1883 ELDER, GEORGE, M.D., 17, Regent street, Nottingham.

1867 ELLIS, JAMES, M.D., Coburg street, Fratton, Portsmouth, and California.

1902 EMANUEL, JOSEPH GEORGE, M.B., B.S., B.Sc., 47, Newhall street, Birmingham.

1902 EMERY, WALTER D'ESTE, M.D., 35, Clifton hill, N.W. (C. Com. Sect. B. 1906-7.)

1863 ENGELMANN, GEORGE JULIUS, M.D., A.M., 336, Beacon street, Boston, Mass., U.S.A.

1879 EVE, FREDERIC S., 125, Harley street, W. (M.G.C. 1884-94. C. 1885-7. V.-P. 1895-7.)

1876 EWART, JAMES COSSAR, M.B., C.M., F.R.S., School of Medicine, Edinburgh.

1877 **EWART**, WILLIAM, M.D., 33, Curzon street, W. (C. 1889-91.)

1859 **Ewens**, JOHN, 17, Redland Grove, Bristol.

1887 EYLES, CHARLES HENRY, Gold Coast Colony.

Elected

1897 EYRE, JOHN W. H., M.D., The Bacteriological Laboratory, Guy's Hospital, S.E. (C. Com. Sect. B, 1904—6.)

1889 FAIRBANK, FREDERICK ROYSTON, M.D., Hillside, Westcott, Dorking.

1894 FAWCETT, JOHN, M.D., 66, Wimpole street, W. (C. Com. Sect. A, 1902-5.)

1902 FENNELL, CHARLES HENRY, M.A., M.B., County Asylum, Hellingly, Sussex.

1872 FENWICK, JOHN C. J., M.D., Long Framlington, Morpeth.

1892 FENWICK, W. SOLTAU, M.D., 29, Harley street, W.

1885 FÉRÉ, CHARLES, M.D., Médecin de Bicêtre; 22, Avenue Bugeaud, Paris.

1906 FIELD, FRANCIS EDWIN, M.B., Ch.B., Leavesden Asylum, King's Langley, Herts.

1904 FIELDING-OULD, ROBERT, M.D., B.Ch., 94, Mount street, Berkeley square, W.

1897 FISHER, THEODORE, M.D., 25, Pembroke road, Clifton, Bristol.

1893 FLETCHER, H. MORLEY, M.A., M.D., B.C., 98, Harley street, W. (C. Com. Sect. A, 1903—6. S. Sect. A, 1901-3.)

1904 FORBES, JAMES GRAHAM, M.D., 1, Duke street, Manchester square, W.

1866 **Foster**, Sir BALTHAZAR WALTER, M.D., M.P., 30, Grosvenor road, Westminster.

1891 FOULERTON, ALEXANDER GRANT RUSSELL, Rhynie, Hayward's Heath, Sussex. (C. 1900—1901. C. Com. Sect. B, 1903—6. S. Sect. B, 1901-3.)

1880 FOWLER, JAMES KINGSTON, M.A., M.D., 35, Clarges street, W. (C. 1887-8.)

1878 FOX, THOMAS COLCOTT, B.A., M.B., 14, Harley street, W. (C. 1892-4.)

1902 FREMLIN, H. STUART, Government Lymph Laboratory, Chelsea Bridge, S.W.

1896 FREYBERGER, LUDWIG, M.D., 41, Regent's park road, N.W. (C. Com. Sect. A, 1902-3.)

1891 FRIPP, Sir ALFRED DOWNING, C.B., M.V.O., M.S., 19, Portland place, W.

1864 FRODSHAM, JOHN MILL, M.D., Streatham, S.W.

1899 FÜRTH, KARL, M.D., 39, Harley street, W.

1894 FURNIVALL, PERCY, 28, Weymouth street, Portland place, W.

1893 FYFFE, WILLIAM KINGTON, M.B., 1, Boullcott street, Wellington, New Zealand.

1880 GABBETT, HENRY SINGER, M.D., 8, Chiswick place, Eastbourne.

1858 **Gairdner**, Sir WILLIAM TENNANT, K.C.B., M.D., LL.D.Edin., F.R.S., 32, George square, Edinburgh. (V.-P. 1891-2.)

1890 GALLOWAY, JAMES, M.A., M.D., 54, Harley street, W. (C. 1899-1902. Com. Sect. A, 1901-2.)

1870 GALTON, JOHN H., M.D., Sylvan road, Upper Norwood, S.E.

Elected

1892 GARROD, ARCHIBALD EDWARD, M.D. (HON. SECRETARY, SECT. D), 9, Chandos street, Cavendish square, W. (C. 1898—1901. S. Sect. D, 1901-7.)

1879 GARSTANG, THOMAS WALTER HARROPP, Englefield, Delamer road, Bowdon, Cheshire.

1872 GARTON, WILLIAM, M.D., Inglewood, Aughton, near Ormskirk, Lancashire.

1902 GASK, G. E., M.B., The Warden's House, St. Bartholomew's Hospital, E.C.

1880 GIBBES, HENEAGE, M.B., University of Michigan, Ann Arbor, Michigan, U.S.A.

1853 GIBBON, SEPTIMUS, M.D., 39, Oxford terrace, Hyde park, W.

1878 GIBBONS, ROBERT A., M.D., 29, Cadogan place, S.W.

1906 GIBSON, A. G., M.B., Pathological Department, University Museum, Oxford.

1876 GILL, JOHN, M.D., 30, West mall, Clifton, Bristol.

1881 GLYNN, THOMAS ROBINSON, M.D., 62, Rodney street, Liverpool.

1898 GOADBY, KENNETH WELDON, 21, New Cavendish street, Portland place, W. (C. Com. Sect. B, 1905-7.)

1873 GODLEE, RICKMAN JOHN, M.B., M.S., 19, Wimpole street, W. (M.G.C. 1875-84. C. 1877-80, 1891-2. S. 1887-9. V.-P. 1893-4, 1902-5. Chairman, Sect. A.)

1878 GOLDING-BIRD, CUTHBERT H., M.B., B.S., 12, Queen Anne street, W. (C. 1885-7. V.-P. 1894-6.)

1907 GOMPERTZ, R., Public Dispensary, Drury lane, W.C.

1902 GOODBODY, FRANCIS WOODCOCK, M.D., 6, Chandos street, W.

1871 GOODHART, JAMES FREDERIC, M.D., 25, Portland place, W. (M.G.C. 1874-86. C. 1876-8, 1886-8. S. 1883-5. V.-P. 1892-3.)

1894 GOSSAGE, ALFRED MILNE, M.B., B.Ch., 54, Upper Berkeley street, W.

1875 GOULD, ALFRED PEARCE, M.S., 10, Queen Anne street, W. (C. 1883-5. V.-P. 1898-1900.)

1870 GOWERS, Sir WILLIAM, M.D., F.R.S., 50, Queen Anne street, W. (C. 1878-9. V.P. 1896-7.)

1888 GRANT, J. DUNDAS, M.A., M.D., C.M., 18, Cavendish square, W.

1905 GRAY, HARRY TYRRELL, 48, Pembroke square, W.

1900 GREEN, ALAN B., M.A., M.D., B.C., Lister Institute of Preventive Medicine, Queensberry Lodge, Elstree, Herts.

1895 GREEN, CHARLES DAVID, M.D., The Ferns, South street, Romford. (C. 1900-2. C. Com. Sect. A, 1901-2.)

1873 GREENFIELD, WILLIAM SMITH, M.D., B.S., 7, Heriot row, Edinburgh. (M.G.C. 1874-81. C. 1877-80. V.-P. 1893-4.)

1886 GREVES, EDWIN HYLA, M.D., Rodney House, Suffolk road, Bournemouth.

1887 GRIFFITHS, JOSEPH, M.D., C.M., 63, Trumpington street, Cambridge.

1876 GRIFFITHS, THOMAS D., M.D., Hearne Lodge, Swansea.

1900 GRUBE, KARL, M.D., Neuenahr, Germany.

1899 GRUBER, R., M.D., 67, Wimpole street, W.

1905 GRÜNBAUM, ALBERT SIDNEY FRANKAU, M.D., 38, Clarendon road, Leeds.

Elected

1902 GRÜNBAUM, O. F. F., M.D., D.Sc., 34, Wimpole street, W. (C. Com. Sect. D. 1906-7.)

1887 HABERSHON, SAMUEL HERBERT, M.D., 88, Harley street, W. (C. Com. Sect. A, 1902-4.)

1851 HACON, E. DENNIS, 269, Mare street, Hackney, N.E. (C. 1872.)

1892 HADLEY, WILFRED JAMES, M.D., 33, Queen Anne street, W.

1882 HAIG, ALEXANDER, M.D., 7, Brook street, W.

1899 HALL, ARTHUR J., M.B., 342, Glossop road, Sheffield.

1905 HALL, JOHN BASIL, M.B., B.C., 116, Manningham lane, Bradford.

1904 HALL, ISAAC WALKER, 9, Royal park, Clifton, Bristol.

1901 HALLIBURTON, WILLIAM DOBINSON, M.D., F.R.S., Church Cottage, 17, Marylebone road, W. (V.-P., Chairman Sect. D., 1901-5.)

1894 HALLIDIE, ANDREW HALLIDIE SMITH, M.B., 50, Noord street, Johannesburg.

1886 HAMILTON, DAVID JAMES, M.B., 41, Queen's road, Aberdeen.

1890 HANDFIELD-JONES, MONTAGU, M.D., 35, Cavendish square, W.

1886 HANDFORD, HENRY, M.D., Elmfield, Southwell.

1902 HANDLEY, WILLIAM SAMPSON, M.S., M.D., 77, Wimpole street, W.

1891 HANKIN, E. H., Agra, India.

1882 HARBINSON, ALEXANDER, M.D., County Lunatic Asylum, Lancaster.

1893 HARLEY, VAUGHAN, M.D., 25, Harley street, W. (C. Com. Sect. D, 1901—6.)

1901 HARMER, W. D., 45, Weymouth street, W.

1896 HARTLEY, PERCIVAL HORTON-SMITH, M.V.O., M.D., B.C., 19, Devonshire street, W.

1905 HARNETT, WALTER SIDWELL, M.B., B.C., St. Thomas's Hospital, S.E.

1891 HASLAM, WILLIAM F., 8, Vicarage road, Edgbaston, Birmingham.

1904 HAWES, COLIN SADLER, Albany General Hospital, Grahamstown, South Africa.

1899 HAWKES, CLAUDE SOMERVILLE, Glencairn, Wickham terrace, Brisbane, Queensland, Australia.

1886 HAWKINS, FRANCIS HENRY, M.D., 73, London street, Reading.

1890 HAWKINS, HERBERT PENNELL, M.D., 56, Portland place, W. (C. 1898—1901.)

1900 HEATON, CHARLES, Westgate-on-Sea, Thanet, Kent.

1892 HEATON, GEORGE, M.B., B.Ch., 47, Newhall street, Birmingham.

1881 HEBB, RICHARD G., M.A., M.D., 50, Ridgmount gardens, Gower street, W.C. (M.G.C. 1891—1900. C. 1891-3. 1898—1901. S. 1896-7.)

1884 HEBBERT, CHARLES ALFRED, care of C. Baylor, 7, Water street, Boston, U.S.A.

1879 HENDERSON, GEORGE COURTENAY, M.D., Kingston, Jamaica, West Indies.

1869 HENSLEY, PHILIP J., M.D., Snaith Cottage, Surbiton Hill, Surrey.

1884 HERRINGHAM, WILMOT PARKER, M.D., 40, Wimpole street, W. (C. 1894-7. V.-P., Chairman, Sect. A, 1906-7.)

1892 HEWLETT, RICHARD TANNER, M.D., Bacteriological Laboratory, King's College, Strand, W.C. (C. Com. Sect. B, 1902-7.)

1897 HICHENS, PEVERELL S., M.B., B.Ch., 45, Sheep street, Northampton.

Elected

1900 HILLIER, WILLIAM THOMAS, Rougemont, Beaconsfield road, St. Albans.

1903 HOBDAY, F., F.R.C.V.S., 10, Silver street, Kensington, W.

1880 HOBSON, JOHN MORRISON, M.D., Glendalough, Morland road, Croydon.

1878 HOOD, DONALD WILLIAM CHARLES, C.V.O., M.D., 43, Green street, Park lane, W.

1864 HOOD, WHARTON P., M.D., 11, Seymour street, W.

1903 HOPEWELL-SMITH, ARTHUR, 37, Park street, Grosvenor square, W.

1895 HOPKINS, FREDERICK GOWLAND, M.B., F.R.S., New Museums, Cambridge, (C. 1899—1905. Com. Sect. D, 1901-5. V.P., Chairman Sect. D. 1905-7.)

1900 HORDER, THOMAS J., M.D., B.Sc., 141, Harley street, W. (C. Com. Sect. B, 1906-7.)

1897 HORNE, W. JOBSON, M.D., 23, Weymouth street, W.

1883 HORSLEY, Sir VICTOR, M.B., B.S., F.R.S., 25, Cavendish square, W. (C. 1888-9. V.-P. 1900-1902.)

1880 **HOVELL**, T. MARK, 105, Harley street, W.

1893 HOWARD, ROBERT JARED BLISS, M.D., 31, Queen Anne street, W.

1856 **HUDSON**, JOHN, M.D., 11, Cork street, W.

1874 HUMPHREYS, HENRY, M.D., St. Mary Church road, Torquay.

1897 HUNT, E. L., c/o King, King, and Co., Bombay.

1897 HUNT, GEORGE B., M.D., 47, Albemarle crescent, Scarborough.

1888 HUNTER, WILLIAM, M.D., 103, Harley street, W. (C. 1897-1900.)

1852 **HUTCHINSON**, JONATHAN, F.R.S., 15, Cavendish square, W. (C. 1856-9, V.-P. 1872-3, 1881-3. P. 1879-80.)

1901 HUTCHISON, ROBERT, M.D., 22, Queen Anne street, W. (C. Com. Sect. D, 1905—.)

1884 HUTTON, HENRY RICHMOND, M.B., 8A, St. John street, Manchester.

1880 INGRAM, ERNEST FORTESCUE, Newcastle, Natal, S. Africa.

1905 INMAN, ARTHUR CONYERS, M.B., B.C., St. Thomas's Hospital, S.E.

1886 JACKSON, ARTHUR MOLYNEUX, M.D., Kent County Asylum, Barming Heath, Maidstone.

1865 JACKSON, J. HUGHLINGS, M.D., F.R.S., 3, Manchester square, W. (C. 1872-3. V.-P. 1888-9.)

1875 JALLAND, WILLIAM HAMERTON, St. Leonard's House, Museum street, York.

1897 JAMES, GEORGE T. B., Carlisle mansions, Victoria street, S.W.

1888 JAMES, JAMES THOMAS, M.D., 108, Harley street, W.

1853 **Jardine**, JOHN LEE, Grandon Lodge, Holmwood, Surrey.

1904 JENNINGS, JOHN FREDERICK, M.B., B.S., St. Bartholomew's Hospital, E.C.

1881 JENNINGS, WILLIAM OSCAR, M.D., 74, Avenue Marceau, Paris.

1878 JOHNSON, ARTHUR JUKES, Yorkville, Ontario, Canada.

1876 JOHNSON, CHARLES HENRY, Winton House, Basingstoke, Hants.

1901 JOHNSON, EDWARD ANGAS, M.B., B.S., 50, Franklin street, Adelaide South Australia.

Elected

1888 JOHNSON, RAYMOND, M.B., B.S., 11, Wimpole street, Cavendish square, W. (C. 1896-9.)

1899 JONAS, HERBERT C., M.D., Bear street, Barnstaple.

1853 **JONES**, SYDNEY, M.B., 8A, New Cavendish street, W. (C. 1864-6. V.-P. 1886-7.)

1888 JONES, TALFOURD, M.B., St. Davids, Pembury, Tunbridge Wells.

1862 **JONES**, THOMAS RIDGE, M.D., 4, Chesham place, S.W. (C. 1882-4.

1898 KEEP, ARTHUR CORRIE, M.D., M.C., 14, Gloucester place, W.

1897 KELLY, CHARLES E. M., M.D., Witney, Oxon.

1859 KIALLMARK, HENRY WALTER, 5, Pembridge gardens, W. (C. 1875-6.)

1882 KIDD, PERCY, M.D., 60, Brook street, W. (C. 1889-91.)

1903 LAKIN, CHARLES ERNEST, M.D., Middlesex Hospital, W.

1878 LANCEREAUX, ETIENNE, M.D., 44, Rue de la Bienfaisance, Paris.

1882 LANE, WILLIAM ARBUTHNOT, M.B., M.S., 21, Cavendish square, W. (C. 1891-3.)

1904 LANGMEAD, FREDERICK, M.D., 74, Oxford terrace, Hyde park, W.

1869 LARCHER, O., M.D.Par., 97, Rue de Passy, Paris. [M. Kliensieck, Libraire, Rue de Lille 11, Paris, per Messrs. Longmans.]

1884 LARDER, HERBERT, Whitechapel Infirmary, Vallance road, N.E.

1897 LATHAM, ARTHUR C., M.D., 38, Portland place, W.

1873 LATHAM, PETER WALLWORK, M.D., 17, Trumpington street, Cambridge.

1853 LAWRENCE, HENRY JOHN HUGHES, Picton House, Llandowror, St. Clears. (C. 1873-5.)

1892 LAWRENCE, THOMAS WILLIAM PELHAM, M.B., 12, North hill, Highgate, N. (C. Com. Sect. A, 1901-3.)

1893 LAWSON, ARNOLD, M.D., 12, Harley street, W.

1879 LAYCOCK, GEORGE LOCKWOOD, M.B., Melbourne, Victoria, Australia.

1891 LAZARUS-BARLOW, WALTER SYDNEY, M.D., Fernholme, Woodside Park, N. Finchley, N. (C. Com. Sect. C, 1901-4.)

1904 LEATHEM, ALFRED NEWMAN, Gwydor Cottage, Elmer's end, Beckenham.

1901 LEATHES, JOHN BERESFORD, M.B., 89, Albert Bridge road, Battersea park, S.W. (C. Com. Sect. D, 1904-7.)

1875 LEDIARD, HENRY AMBROSE, M.D., 35, Lowther street, Carlisle. (C. 1897-1900.)

1906 LEDINGHAM, J. C. G., London Hospital Medical College, London Hospital, E.

1877 **LEES**, DAVID B., M.D., 22, Weymouth street, W. (C. 1890-2.)

1867 LEES, JOSEPH, M.D., 21, Brixton road, S.W.

1877 LEESON, JOHN RUDD, M.D., C.M., 6, Clifden road, Twickenham.

1868 LEGG, JOHN WICKHAM, M.D. (Travelling.) (C. 1874-5.)

1902 LEGG, THOMAS PERCY, M.B., 141, Harley street, W.

1892 LEITH, ROBERT FRASER CALDIE, M.B., C.M., B.Sc.

1892 **Leudet**, ROBERT, 72, Rue de Bellechasse, Paris, France.

1897 LISTER, THOMAS DAVID, M.D., 50, Brook street, W.

1895 LITTLE, ERNEST GRAHAM GORDON, M.D., 61, Wimpole street, W.

1889 LITTLE, JOHN FLETCHER, M.B., 125, Harley street, W.

Elected

1862 **LITTLE**, LOUIS S., 31, Grosvenor street, W.
1896 LITTLEWOOD, HARRY, 25, Park square, Leeds.
1863 **LIVEING**, ROBERT, M.D., 11, Manchester square, W. (C. 1876.)
1881 LUBBOCK, MONTAGU, M.D., 19, Grosvenor street, W.
1897 LUCAS, ALBERT, 9, Easy row, Birmingham.
1873 LUCAS, R. CLEMENT, M.B., B.S., 50, Wimpole street, W. (C. 1883-5.)
1887 LYON, THOMAS GLOVER, M.D., 1, Victoria square, S.W.

1907 MACCORMAC, H., 13, Malone avenue, Belfast.
1904 MCDONALD, STUART, 39, Thirlestane road, Edinburgh.
1893 MCFADYEAN, Sir JOHN, M.B., Royal Veterinary College, Great College street, N.W. (C. 1899-1901. Com. Sect. B, 1901-4.)
1899 MCGAVIN, LAWRIE H., 6, Mansfield street, Cavendish square, W.
1885 MACKENZIE, HECTOR WILLIAM GAVIN, M.A., M.D., 34, Upper Brook street, Grosvenor square, W. (C. 1895-7.)
1870 MACKENZIE, JOHN T., Bombay, India.
1878 MACKENZIE, SIR STEPHEN, M.D., Merrycourt, Great Bookham, Leatherhead, Surrey. (C. 1888-90.)
1902 MACKIE, FREDERIC PERCIVAL, Agents, *c/o* Grindlay, Groom and Co. Bombay.
1865 MACLAURIN, HENRY NORMAND, M.D., 187, Macquarie street, Sydney, New South Wales.
1896 MCWEENEY, EDMOND JOSEPH, M.D., M.Ch., 84, St. Stephen's green, Dublin.
1885 MAGUIRE, ROBERT, M.D., 4, Seymour street, W.
1877 **MAKINS**, GEORGE HENRY, C.B., 47, Charles street, Berkeley square, W. (C. 1889-91. V.-P. 1899-1901.)
1887 MALCOLM, JOHN DAVID, M.B., C.M., 13, Portman street, W.
1892 MANN, HAROLD EDWARD, Alderney.
1890 MANSON, Sir PATRICK, K.C.M.G., M.D., C.M., F.R.S., 21, Queen Anne street, W. (C. 1900-1.)
1876 MAPLES, REGINALD, Kingsclere, near Newbury.
1904 MARRIAGE, HERBERT JAMES, M.B., B.S., 109, Harley street, W.
1868 MARSH, F. HOWARD, M.C., 14, Hertford street, Mayfair, W. (C. 1876-7.) (V.-P 1889-90.)
1904 MARTIN, CHARLES J., M.B., D.Sc., F.R.S., Lister Institute of Preventive Medicine, Chelsea gardens, S.W. (C. Com. Sect. C, 1904-7.)
1887 MARTIN, SIDNEY, M.D., B.S., F.R.S., 10, Mansfield street, W. (C. 1893-6. V.-P. 1900-1902.)
1889 MASON, DAVID JAMES, M.D., Rosemont, Maidenhead.
1898 MASTERMAN, ERNEST WILLIAM GURNEY, Surgeon, English Mission Hospital, Jerusalem, Syria.
1892 MASTERS, JOHN ALFRED, M.D., 94, Knightsbridge, S.W.
1884 MAUDSLEY, HENRY CARR, M.D., 11, Spring street, Melbourne, Victoria.
1902 MAVROGORDATO, ANTHONY, 8, Ladbroke gardens, W.
1897 MAXWELL, J. P., c/o E.P. Mission, Eng Chhun, Amoy, China.
1900 MAXWELL, JAMES LAIDLAW, M.D., E.P. Mission, Yai-nan-fu, Formosa, *viâ* Hong Kong.

Elected

1852 **MAY**, George, M.B., Reading.

1838 **May**, William Page, M.D., B.Sc., 9, Manchester square, W., and Heloman, near Cairo, Egypt (November to April).

1881 **Maylard**, Alfred Ernest, M.B., 12, Blythswood square, Glasgow.

1874 **Meredith**, William Appleton, C.M., 21, Manchester square, W.

1894 **Michels**, Ernest, M.D., 48, Finsbury square, E.C.

1900 **Milburn**, Leslie, Kenley, Beverley gardens, Cullercoats, Northumberland.

1901 **Moore**, Alfred, Reculver Villa, Cheam road, Sutton, Surrey.

1899 **Moore**, Frederick Craven, M.D., The Priory, Ardwick Green, Manchester.

1879 **Moore**, Norman, M.D., 94, Gloucester place, Portman square, W. (C. 1885-7. M.G.C. 1889-1900. V.-P. 1895-7.)

1874 **Morison**, Alexander, M.D., C.M., 14, Upper Berkeley street, W.

1869 **MORRIS**, Henry, M.A., M.B. (Trustee), 8, Cavendish square, W. (C. 1877-9, 1884-6. S. 1881-3. V.-P. 1888-9.)

1879 **Morris**, Malcolm Alexander, 8, Harley street, W.

1894 **Morrice**, George Gavin, M.D., Holy Trinity Vicarage, Weymouth.

1891 **Morton**, Charles A., 14, Vyvyan terrace, Clifton, Bristol.

1884 **Mott**, Frederick Walker, M.D., F.R.S., 25, Nottingham place, W. (C. 1891-3. V.-P. 1899-1901.)

1900 **Muir**, Robert, M.D., 4, Alfred terrace, Glasgow.

1893 **Mummery**, John Howard, 10, Cavendish place, W.

1899 **Murray**, George R., M.D., 11, Ellison place, Newcastle-on-Tyne.

1894 **Murray**, John, M.B., B.Ch., 110, Harley street, W.

1901 **Nabarro**, David, M.D., B.Sc., D.P.H., 4, Albemarle mansions, Heath Drive, N.W. (C. Com. Sect. B, 1906-7.)

1887 **Nason**, Edward Noel, M.D., 80, Abbey street, Nuneaton.

1904 **Neave**, Sheffield, Mill Green park, Ingatestone, Essex.

1875 **Newby**, Charles Henry, St. Mary's, Broad Park avenue, Ilfracombe.

1902 **Newland**, Henry Simpson, M.B., Ch.B., North terrace, Adelaide, S. Australia.

1865 **Newman**, William, M.D., Stamford, Lincolnshire.

1895 **Nias**, J. Baldwin, M.D., 5, Rosary gardens, S. Kensington, S.W.

1868 **Nicholls**, James, M.D., Trekenning House, St. Columb, Cornwall.

1876 **Nicholson**, Frank, M.D., 29, Albion street, Hull.

1864 **NORTON**, Arthur T., C.B., Leyfields Wood, Ashampstead, Berks. (C. 1877-9.)

1883 **Norvill**, Frederic Harvey, M.B., Dibrooghur, India.

1880 **O'Connor**, Bernard, M.D., 32, Old Buildings, Lincoln's Inn, W.C.

1873 **O'Farrell**, Sir George Plunkett, M.D., 19, Fitzwilliam square, Dublin.

1894 **Ogle**, Cyril, M.D., 96, Gloucester place, W. (C. 1899-1901.)

1888 **Openshaw**, Thomas Horrocks, C.M.G., M.S., 16, Wimpole street W.

1892 **Ord**, William Wallis, M.D., The Hall, Salisbury.

Elected

1879 ORMEROD, JOSEPH A., M.D., 25, Upper Wimpole street, W. (C. 1887-9.)

1875 OSBORN, SAMUEL, Maisonnette, Datchet, Bucks.

1865 OWLES, JAMES ALLDEN, M.D., Hill View, Woking, Surrey.

1884 PAGET, STEPHEN, 70, Harley street, W. (C. 1894-7.)

1895 PAKES, WALTER CHARLES, Government Laboratory, Pretoria, South Africa. (C. Com. Sect. B, 1901-2.)

1897 PARFITT, CHARLES D., M.D., London, Canada.

1898 PARKER, ARTHUR PERCY, M.B., B.Ch., 2, Holywell, Oxford.

1874 PARKER, RUSHTON, M.B., B.S., 59, Rodney street, Liverpool.

1853 PARKINSON, GEORGE, Orchard Dene, Henley-on-Thames.

1901 PARSONS, JOHN HERBERT, M.B., B.S., B.Sc., 27, Wimpole street, W.

1882 PASTEUR, WILLIAM, M.D., 4, Chandos street, W. (C. 1893-6.)

1885 PAUL, FRANK THOMAS, 38, Rodney street, Liverpool.

1865 PAVY, FREDERICK WILLIAM, M.D., LL.D., F.R.S., 35, Grosvenor street, W. (C. 1872-4. V.-P. 1891-2. V.-P., Chairman Sect. C, 1901-7. P. 1893-4.)

1868 PAYNE, JOSEPH FRANK, M.D. (TRUSTEE), Lyonsdown House, New Barnet, Herts. (M.G.C. 1872-85. C. 1873-5, 1883-5. S. 1880-2. V.-P. 1888-9. V.-P., Chairman Sect. A, 1901-2. P. 1897-8.)

1872 PEARCE, JOSEPH CHANING, M.D., C.M., Montague House, St. Lawrence-on-Sea, Kent.

1879 PEEL, ROBERT, 130, Collins street East, Melbourne, Victoria.

1899 PEMBREY, MARCUS SEYMOUR, M.D., B.Ch., Guy's Hospital, S.E. (C. Com. Sect. C, 1904-7.)

1889 PENBERTHY, JOHN, Royal Veterinary College, Camden Town, N.W.

1884 PEPPER, AUGUSTUS JOSEPH, M.B., C.M., 13, Wimpole street, W.

1900 PERKINS, JOSEPH JOHN, M.B., 8, Mansfield street, Cavendish square, W.

1888 PERRY, Sir EDWIN COOPER, M.D., Superintendent's House, Guy's Hospital, S.E.

1904 PETRIE, GEORGE FORD, M.D., *c/o* King, King, & Co., Bombay.

1902 PHEAR, ARTHUR G., M.D., 47, Weymouth street, W.

1878 PHILIPPS, SUTHERLAND REES, M.D., 4, The Beacon, Exmouth.

1878 PHILLIPS, JOHN WALTER, 30, Stanley street West, Melbourne, Victoria.

1893 PINKERTON, ROBERT A., M.A., M.D., 15, South Norwood hill, S.E.

1884 PITT, GEORGE NEWTON, M.D., 15, Portland place, W. (M.G.C. 1889-97. C. 1890-2, 1896-9. S. 1894-6. V.-P. 1899-1901.)

1876 PITTS, BERNARD, M.A., M.C., 109, Harley street, W. (C. 1888-90.)

1899 PLIMMER, HENRY GEORGE, 3, Hall road, N.W. (C. Com. Sect. B. 1901-3.)

1883 POLAND, JOHN, 2, Mansfield street, Cavendish square, W.

1882 POLLARD, BILTON, M.B., B.S., 24, Harley street, W. (C. 1895-7.)

1850 POLLOCK, JAMES EDWARD, M.D., 37, Collingham place, W. (C. 1862-4. V.-P. 1879-81.)

1879 POTTER, HENRY PERCY, M.D., St. Mary Abbotts Infirmary, Marloes road Kensington, W.

1866 POWELL, Sir RICHARD DOUGLAS, Bart., K.C.V.O., M.D., P.R.C.P., 62, Wimpole street, W. (C. 1873-5, 1881-3. S. 1877-9. V.-P. 1887-8.)

Elected

1884 **POWER**, D'ARCY, M.A., M.B., 10A, Chandos street, W. (C. 1891-3. 1899-1902. Com. Sect. A, 1901-2. M.G.C. 1897-1900. S. 1897-9.)

1865 POWER, HENRY, Bagdale Hall, Whitby. (C. 1876-7.)

1900 POYNTON, FREDERICK JOHN, M.D., 1, Harley place, Harley street, W. (C. Com. Sect. A, 1905-7.)

1887 PRATT, WILLIAM SUTTON, M.D., Penrhos House, Rugby.

1902 PRICE, F. W., M.B., 133, Harley street, W.

1884 PRICE, JOHN A. P., M.D., 124, Castle street, Reading.

1900 PRICE-JONES, CECIL, M.B., Beachcote, The Bungalow, Walmer Beach.

1888 PRIMROSE, ALEXANDER, M.B., C.M., 100, College street, Toronto, Canada.

1895 PURVIS, WILLIAM PRIOR, M.D., 2, Avenue place, Southampton.

1865 PYE-SMITH, PHILIP HENRY, M.D., F.R.S. (PRESIDENT), 48, Brook street, W. (C. 1874-7. V.-P. 1890-1. Chairman Sect. A, 1905—6. T. 1903—6.)

1897 RANKIN, GUTHRIE, M.D., 4, Chesham street, S.W.

1890 **Ransom**, WILLIAM BRAMWELL, M.D., The Pavement, Nottingham.

1891 RATCLIFFE, JOSEPH RILEY, M.B., C.M., Wake green, Moseley.

1887 RAVEN, THOMAS FRANCIS, Broadstairs, Kent.

1870 RAY, EDWARD REYNOLDS, 15A, Upper Brook street, W.

1875 REID, ROBERT WILLIAM, M.D., C.M., 8, Queen's gardens, Aberdeen,

1901 REID, ST. GEORGE CAULFIELD, Brigstock House, Thornton Heath, Surrey.

1906 REID, SIDNEY THOMAS, R.N., Royal Naval Hospital, Chatham.

1901 REISSMANN, CHARLES, M.B., 8, North terrace, Adelaide, S. Australia.

1881 RENNER, WILLIAM, Wilberforce street, Free Town, Sierra Leone.

1893 RENNIE, GEORGE EDWARD, M.D., College street, Hyde park, Sydney, N.S.W.

1895 RITCHIE, JAMES, M.D., 28, Beaumont street, Oxford. (C. Com. Sect. B, 1903-5.)

1901 RIVIERE, CLIVE, M.D., 19, Devonshire street, W.

1865 **Roberts**, DAVID LLOYD, M.D., 11, St. John's street, Manchester.

1871 ROBERTS, FREDERICK THOMAS, M.D., 102, Harley street, W. (C. 1883-5.)

1878 ROBERTS, WILLIAM HOWLAND, M.D., Surgeon, Madras Army.

1888 ROBERTSON, ROBERT, M.D., The Bungalow, Ventnor, Isle of Wight.

1885 ROBINSON, ARTHUR HENRY, M.D., St. Mary's Infirmary, Highgate hill, N.

1882 ROBINSON, TOM, M.D., 9, Princes street, Cavendish square, W.

1904 ROBSON, A. W. MAYO, 8, Park crescent, Portland place, W.

1888 ROLLESTON, HUMPHRY DAVY, M.A., M.D. 55, Upper Brook street, Grosvenor square, W. (C. 1894-7. 1900-1902. Com. Sect. A, 1901-2. M.G.C. 1895-1900. S. 1898-1900.)

1904 ROSE, FRANK ATCHERLEY, M.B., 3, Upper Wimpole street, W.

1858 **ROSE**, HENRY COOPER, M.D., 16, Warwick road, Maida hill, N.W. (C. 1873-4.)

1906 ROSS, ERNEST ATHOLE, M.B., B.C., The Grove Lodge, Sawbridgeworth, Herts.

1875 ROSSITER, GEORGE FREDERICK, M.B., Cairo Lodge, Weston-super-Mare.

Elected

1877 **ROTH**, BERNARD, 38, Harley street, W., and Kingswood, Enfield.

1891 ROUILLARD, LAURENT ANTOINE JOHN, M.B., Durban, Natal.

1901 ROWLAND, SYDNEY, M.A., Lister Institute of Preventive Medicine, S.W.

1899 ROWLANDS, ROBERT P., 6, St. Thomas's street, London Bridge, S.E.

1891 RÜFFER, MARC ARMAND, M.D., The Quarantine Board, Alexandria.

1897 RUNDLE, HENRY, 13, Clarance parade, Southsea.

1900 RUSSELL, A. E., M.D., 9, Wimpole street, Cavendish square, W.

1895 RUSSELL, JAMES SAMUEL RISIEN, M.D., 44, Wimpole street, Cavendish square, W.

1891 RUSSELL, WILLIAM, M.D., 3, Walker street, Edinburgh.

1903 SALAMAN, REDCLIFFE N., M.B., Homestall, Barley, Royston, Herts.

1902 SARGENT, PERCY WILLIAM GEORGE, M.B., B.C., 67A, Harley street, W.

1886 SAUNDBY, ROBERT, M.D., 140B, Great Charles street, Birmingham.

1871 SAUNDERS, CHARLES EDWARD, M.D., Sussex County Lunatic Asylum, Hayward's Heath.

1901 SAUNDERS, E. Arthur, M.B., 49, Harley street, W.

1890 SAUNDERS, FREDERICK WILLIAM, M.B., B.C., Chieveley House, Newbury.

1873 SAVAGE, GEORGE HENRY, M.D., 26, Devonshire place, W. (C. 1881-3.)

1882 SAVILL, THOMAS DIXON, M.D., 60, Upper Berkeley street, W.

1902 SCHÖLBERG, H. A., M.B., University College of South Wales and Monmouthshire, Cardiff.

1901 SCOTT, Hon. G. H., M.D., B.C., Trinity College, Cambridge.

1902 SCOTT, S. G., M.A., M.B., Yorkshire College, Department of Medicine, Thoresby place, Leeds.

1899 SELIGMANN, CHARLES G., M.D., 15, York terrace, Regent's Park, N.W. (C. Com. Sect. A, 1905-7.)

1903 SELOUS, C. F., M.B., St. Thomas's Hospital, Albert Embankment, S.E.

1877 SEMON, Sir FELIX, C.V.O., M.D., 39, Wimpole street, W. (C. 1885-7.)

1894 SEQUEIRA, JAMES HARRY, M.D., 63, Harley street, Cavendish square, W.

1872 SERGEANT, EDWARD, D.P.H., Lancashire County Council, Public Health Department, County Offices, Preston.

1876 SHARKEY, SEYMOUR J., M.D., 22, Harley street, W. (M.G.C. 1884-1895. C. 1884-6. V.-P. 1895-7.)

1880 SHATTOCK, SAMUEL G. (HON. GENERAL SECRETARY), 4, Crescent road, The Downs, Wimbledon, S.W. (M.G.C. 1884-1900. C. 1885-7. 1893-6. S. 1890-2, 1902-7. V.-P. 1896-8. E. 1900-7.)

1898 SHAW, HAROLD BATTY, M.D., 7, Devonshire street, W. (C. Com. Sect. A, 1903—6.)

1885 SHAW, LAURISTON ELGIE, M.D., 64, Harley street. W.

1886 **SHERRINGTON**, CHARLES SCOTT, M.D., F.R.S., University College, Liverpool. (C. 1894-7.)

1856 **SHILLITOE**, BUXTON, 2, Frederick's place, E.C.

1875 SIDDALL, JOSEPH BOWER, M.D., C.M., Conybeare, Northam, Bideford.

1901 SINGER, HAROLD DOUGLAS, M.D., McCagne Buildings, Omaha, Neb., U.S.A.

1892 SLATER, CHARLES, M.B., St. George's Hospital, S.W.

Elected

1887 SMALLPEICE, WILLIAM DONALD, 10, Chester square, S.W.

1887 **SMITH**, FREDERICK JOHN, M.D., 138, Harley street, W.

1894 SMITH, GUY BELLINGHAM, M.B., B.S., 24, St. Thomas's street, S.E.

1906 SMITH, J. HENDERSON, M.B., B.Ch., 225, Woodstock road, Oxford.

1900 SMITH, J. LORRAIN, M.D., The Victoria University of Manchester. (C. Com. Sect. C, 1905—.)

1873 SMITH, RICHARD T., M.D., 117, Haverstock hill, N.W.

1883 SMITH, ROBERT PERCY, M.D., 36, Queen Anne street, W.

1869 SMITH, ROBERT SHINGLETON, M.D., Deepholm, Clifton Park, Bristol.

1866 SMITH, WILLIAM, Melbourne, Australia.

1870 SNOW, WILLIAM VICARY, M.D., Richmond Gardens, Bournemouth.

1888 SOLLY, ERNEST, M.B., Strathlea, Harrogate, Yorks.

1887 SPENCER, WALTER GEORGE, M.S., 35, Brook street, W. (M.G.C. 1894-1900. C. 1896-9.)

1906 SPILSBURY, BERNARD H., M.B., B.Ch., 25, Cambridge Terrace, Hyde Park, W.

1899 SPRIGGS, EDMUND IVEN, M.D., 48, Bryanston Street, W.

1861 SQUIRE, ALEXANDER BALMANNO, M.B., 24, Weymouth street, W.

1901 STAINER, E., M.B., 60, Wimpole street, W.

1895 STARLING, ERNEST HENRY, M.D., F.R.S., 40, West end lane, N.W. (C. Com. Sect. C, 1901-7.)

1896 STEPHENS, J. W. W., M.D., The Johnston Laboratory, The University, Liverpool.

1899 STEWARD, FRANCIS J., M.S., 125, Harley street, W.

1891 STILES, HAROLD JALLAND, M.B., C.M., 5, Castle terrace, Edinburgh.

1897 STILL, GEORGE F., M.D. (HON. SECRETARY, SECT. A), 114, Harley street, W. (C. Com. Sect. A, 1901-3. Sec. Sect. A, 1903-7.)

1879 STIRLING, EDWARD CHARLES, C.M.G., M.D., F.R.S., Adelaide, South Australia [care of Messrs. Elder & Co., 7, St. Helen's place, E.C.].

1884 STONHAM, CHARLES, C.M.G., 4, Harley street, W. (C. 1893-6.)

1896 STRANGEWAYS, T. P., St. John's College, Cambridge.

1902 STRICKLAND-GOODALL, J., M.D., 30, Vanbrugh hill, Blackheath, S.E.

1903 STRONG, WALTER M., "Helstonleigh," Champion park, Denmark hill, S.E.

1875 STURGE, W. A., M.D., 29, Boulevard Dubouchage, Nice.

1867 SWAIN, WILLIAM PAUL, 17, The Crescent, Plymouth.

1881 SYMONDS, CHARTERS JAMES, M.S., 58, Portland place, W. (M.G.C. 1884-91. C. 1886-8. V.-P. 1899-1901.)

1886 TARGETT, JAMES HENRY, M.B., M.S., 19, Upper Wimpole street, W. (M.G.C. 1894-1900. C. 1894-5, 1897-1900. V.-P. 1900-1902. S. 1895-7.)

1870 TAY, WARREN, 4, Finsbury square, E.C. (C. 1881-2.)

1871 **TAYLOR**, FREDERICK, M.D., 20, Wimpole street, W. (M.G.C. 1879-89. C. 1879-81. V.-P. 1897-9.)

1885 TAYLOR, HENRY H., 36, Brunswick square, Hove, Sussex.

1892 TAYLOR, JAMES, M.D. 49, Welbeck street, W.

1902 THIELE, FRANCIS HUGO, M.D., 19, Hampstead lane, Highgate, N.

1891 THOMSON, HENRY ALEXIS, M.D., 39, Drumsheugh gardens, Edinburgh

Elected

1884 THOMSON, JOHN, M.D., C.M., 14, Coates crescent, Edinburgh.
1901 THOMSON-WALKER, J. W., M.B., 30, Queen Anne street, W.
1892 **Thorburn**, WILLIAM, B.S., 2, St. Peter's square, and Rusholme Lodge, Rusholme, Manchester.
1872 THORNTON, WILLIAM PUGIN, 35, St. George's place, Canterbury.
1900 THURSFIELD, HUGH, M.D., 84, Wimpole street, W. (C. Com. Sect. A, 1905-7.)
1880 TIRARD, NESTOR ISIDORE, M.D., 74, Harley street, W.
1884 TIVY, WILLIAM JAMES, 8, Lansdowne place, Clifton, Bristol.
1882 TOOTH, HOWARD HENRY, C.M.G., M.D., 34, Harley street, W. (C, 1892-4. M.G.C. 1895-1900.)
1886 TOTSUKA, KANKAI, Tokio, Japan.
1872 **TOWNSEND**, THOMAS SUTTON, 68, Queen's gate, S.W.
1899 TREDGOLD, ALFRED F., London County Asylum, Woodford Bridge, Essex.
1888 TREVELYAN, EDMOND F., M.D., 40, Park square, Leeds.
1902 TREVOR, ROBERT SALUSBURY, M.B., 21, Fitzgeorge avenue, West Kensington, W.
1904 TROTTER, WILFRED BATTEN LEWIS, M.S., 13, Harley street, W.
1895 TROUTBECK, HENRY, M.B., B.C., 151, Ashley gardens, S.W.
1859 **TRUMAN**, EDWIN THOMAS, 23, Old Burlington street, W.
1888 TUBBY, ALFRED HERBERT, M.S., 68, Harley street, W.
1858 TUDOR, JOHN, Dorchester, Dorset.
1893 TURNEY, HORACE GEORGE, M.D., M.Ch., 68, Portland place, W.
1858 **TURTLE**, FREDERICK, M.D., Kirkmead, Woodford, Essex.
1880 TYSON, WILLIAM JOSEPH, M.D., 10, Langhorne gardens, Folkestone.

1867 VENNING, Sir EDGCOMBE, 30, Cadogan place, S.W.
1889 VOELCKER, ARTHUR FRANCIS, M.D., B.S., 101, Harley street, W. (C. 1895-7.)

1867 **WAGSTAFFE**, WILLIAM WARWICK, B.A., Purleigh, St. John's hill, Sevenoaks. (C. 1874, 1878-80. M.G.C. 1874-82. S. 1875-7.)
1885 WAKLEY, THOMAS, jun., 16, Hyde park gate, S.W.
1902 WALKER, E. W. AINLEY, M.D., University College, Oxford.
1893 WALKER, NORMAN PURVIS, M.D., 7, Manor place, Edinburgh.
1901 WALLACE, CUTHBERT SIDNEY, 26, Upper Wimpole street, W.
1881 WALLER, BRYAN CHARLES, M.D., Masongill House, Cowan bridge, Kirkby-Lonsdale.
1890 WALLIS, FREDERICK CHARLES, M.B., B.C., 107, Harley street, W. (C. 1898-1901.)
1859 WALTERS, JOHN, M.B., Reigate, Surrey.
1892 WARD, ALLAN OGIER, M.D.Edin., 73, Cheapside, E.C.
1903 WARD, EDWARD, M.B., B.C., 30, Park square, Leeds.
1892 WARING, HOLBURT JACOB, M.B., M.S., 37, Wimpole street, W.
1891 WATERHOUSE, HERBERT FURNIVALL, M.D., C.M., 81, Wimpole street, W.
1903 WATERS, W. A. P., M.D., 99, Holywell, Oxford.
1890 WEBB, CHARLES FRERE, M.D., New street House, Basingstoke.

Elected

1894 **WEBER**, Frederick Parkes, M.D., 19, Harley street, W. (C. Com. Sect. A, 1906-7.)

1858 **WEBER**, Sir Hermann, M.D., 10, Grosvenor street, W. (C. 1867-70. V.-P. 1878-80.)

1864 Welch, Thomas Davies, M.D. (Travelling).

1894 Wells, Sydney Russell, M.D., 16, Lower Seymour street, Portman square, W.

1892 Wesbrook, Frank F., M.D., The University of Minnesota, Minneapolis, U.S.A.

1877 West, Samuel, M.D., 15, Wimpole street, W. (C.1884-6, 1891-3. S, 1889-90. V.-P. 1896-7.)

1891 Wheaton, Samuel Walton, M.D., 10, Restall avenue, Streatham hill, S.W.

1869 Whipple, John H. C., M.D., Royal Army Medical Corps.

1877 White, Charles Haydon, 4, East Circus street, Park row, Nottingham.

1894 **WHITE**, Charles Powell, M.B., Pathological Laboratory, Victoria University, Manchester. (C. Com. Sect. A, 1903-5.)

1891 White, Gilbert B. Mower, M.B., B.S., 112, Harley street, W.

1881 White, William Hale, M.D., 65, Harley street, W. (C. 1888-90.)

1886 White, William Henry, M.D., 43, Weymouth street, W.

1868 **Whitehead**, Walter, Birchfield, 235, Wilmslow road, Manchester.

1897 Whitfield, Arthur, M.D., 21, Bentinck street, Manchester square, W. (C. Com. Sect. A, 1905-7.)

1869 Wilkin, John F., M.D., M.C., Rose Ash Court, N. Devon.

1871 Wilkinson, J. Sebastian. Address uncommunicated.

1869 Williams, Albert, M.D. (Travelling).

1858 **Williams**, Charles, 48, Prince of Wales road, Norwich.

1866 Williams, Charles Theodore, M.V.O., M.D., 2, Upper Brook street, W. (C. 1875-8.)

1881 Williams, Dawson, M.D., B.S., 2, Agar street, Strand, W.C. (C. 1893-6.)

1881 Williams, W. Roger, Beaufort House, Clifton Down, Clifton.

1900 Williamson, Oliver K., M.B., B.C., 55, Upper Berkeley street, W.

1863 Willis, Francis, M.D., Asheville, N. Carolina, U.S.A.

1889 Wilson, Albert, M.D., 1, Belsize park, N.W.

1888 Wilson, Claude, M.D., C.M., Church road, Tunbridge Wells.

1859 Wilson, Edward Thomas, M.B., Montpelier terrace, Cheltenham.

1891 Wilson, Theodore Stacey, M.D., C.M., 27, Wheeley's road, Edgbaston, Birmingham.

1861 **Windsor**, Thomas, Brownlow, Great Budworth, Northwich.

1874 Wiseman, John Greaves, Straurner, St. Peter's Road, St. Margaret's-on-Thames.

1883 Woodcock, John Rostron, Darlington Court, North road, Bath.

1883 Woodhead, German Sims, M.D., 6, Scrope terrace, Cambridge. (C. 1891-3. V.-P. 1898—1900. M.G.C. 1899—1900.)

1879 Woodward, G. P. M., M.D., Deputy Surgeon General; Sydney, New South Wales.

Elected

1884 WORTS, EDWIN, 6, Trinity street, Colchester.

1903 WRIGHT, Sir ALMROTH EDWARD, M.D., F.R.S., 7, Lower Seymour street, Portman square, W. (C. Com. Sect. B, 1903-5. V.-P., Chairman Sect. B, 1905-7.)

1890 WYNNE, EDWARD T., M.B., Gladstone, Queensland.

1884 WYNTER, WALTER ESSEX, M.D., 27, Wimpole street, W.

1872 YOUNG, HENRY, M.B., Monte Video, South America.

1901 YOUNG, HENRY WILLIAM PENNEFATHER, "Dursley," Norbury, S.W

NOTICE.

At a General Meeting held on June 4th, 1907, the Pathological Society of London was dissolved, in order to constitute henceforth the Pathological Section of the Royal Society of Medicine.

The publications of the Pathological Section will appear as part of the more extensive publication of the Royal Society of Medicine, which will comprise the work of thirteen sections (previously independent societies), viz. :

(1) Clinical.
(2) Dermatological.
(3) Electro-therapeutical.
(4) Epidemiological.
(5) Laryngological.
(6) Medical.
(7) Neurological.
(8) Obstetrical and Gynæcological.
(9) Odontological.
(10) Otological.
(11) Pathological.
(12) Surgical.
(13) Therapeutical and Pharmacological.

The property of the Pathological Society has been handed over in its entirety to the Royal Society of Medicine.

Notandum.

Dissoluta est jam de die quarto Junii, 1907, Societas Pathologica Londinensis, Facultas ut fieret Pathologica Societatis regiæ Medicinæ, in Londino nuper constitutæ.

Quæcunque ad hanc Facultatem pertinent litteræ, conjunctim cum illis Societatis regiæ Medicinæ abhinc in lucem edentur.

S. G. Shattock.

LIST OF COMMUNICATIONS

MADE TO THE SOCIETY DURING THE SESSION 1906-7.

			PAGE
1.	Chorion-epithelioma of testis	T. W. P. Lawrence	1
2.	Chorion-epithelioma of testis	J. M. Bernstein	4
3.	Chorion-epithelioma of congenital origin	V. Bonney	9
4.	Jensen's mouse tumour	W. R. Williams	38
5.	Pathology of the sphincters	E. M. Corner	42
6.	Fœtal bone disease	F. S. Dawe	59
7.	Round-celled sarcoma of stomach	N. Dalton	61
8.	The poison of the weever fish	H. M. Evans	63
9.	Lateral fractures of the axis	E. M. Corner	78
10.	Origin of the red blood-corpuscles in mammals	C. E. Walker	99
11.	Centrosomes and other structures in the red blood-corpuscles of vertebrates	R. Ross, F.R.S., J. E. S. Moore, and C. E. Walker	107
12.	Eosinophilic pleurisy	J. J. Perkins and L. S. Dudgeon	119
13.	A histological study of the human parathyroid glands	W. L. Harnett	128
14.	The parathyroid glands in man	D. Forsyth	154
15.	A case of sulph-hæmoglobinæmia	A. E. Russell	177
16.	Calcareous change in the myocardium	W. O. Meek	183
17.	The activity of the adrenals in relation to blood-pressure	P. R. Parkinson	187
18.	Primary carcinoma of the male urethra	S. G. Shattock	199
19.	Osteo-lipoma of the brain	F. P. Weber and P. Daser	219
20.	Fatty degeneration of the blood	S. G. Shattock and L. S. Dudgeon	227
21.	Cystinuria with diamenes	F. H. Thiele	255
22.	A case of typhoid fever diagnosed in the absence of agglutination	T. J. Horder	263
23.	Influenzal endocarditis	T. J. Horder	265
24.	Ovarian embryoma, with remarks on the pathogenesis of the so-called dermoid cyst of the ovary	S. G. Shattock	267
25.	Hæmogregarines of snakes	L. W. Sambon and C. G. Seligmann	310

LIST OF PLATES.

		TO FACE PAGE
I II.	The origin of red blood-corpuscles. (C. E. Walker)	104
III.	Centrosomes and other structures in red blood-corpuscles. (R. Ross, F.R.S., J. E. S. Moore, and C. E. Walker) . . .	112
IV, V.	Human parathyroid glands. (W. L. Harnett) .	146
VI, VII.	Human parathyroid glands. (D. Forsyth) .	162
VIII.	Fatty degeneration of the blood. (S. G. Shattock and L. S. Dudgeon) . . .	254
IX—XI.	Ovarian embryomata. (S. G. Shattock)	272, 292, 292
XII—XV.	Hæmogregarines of snakes (L. W. Sambon and C. G. Seligmann) . . .	370

LIST OF FIGURES IN THE TEXT.

		PAGE
1—3. Chorion-epithelioma of testicle	(J. M. Bernstein)	5—8
4—17. Chorion-epithelioma of congenital origin	(V. Bonney)	11—29
18. Poison of the weever fish	(H. M. Evans)	65
19—25. Fractures of the axis	(E. M. Corner)	80—87
26. Human parathyroids	(W. L. Harnett)	136
27. Calcareous change in myocardium	(W. O. Meek)	185
28—31. Primary carcinoma of male urethra	(S. G. Shattock)	201—217
32, 33. Osteo-lipoma of brain	(F. P. Weber and P. Daser)	220, 221
34. Fatty degeneration of the blood	(S. G. Shattock and L. S. Dudgeon)	231
35. Teratomatous cyst of testicle	(S. G. Shattock)	308
36—73. Hæmogregarines of snakes	(L. W. Sambon and C. G. Seligmann)	318—368

ADDRESS BY THE PRESIDENT,

Delivered at the last Meeting of the Society held on June 4th, 1907, at which date the Society was dissolved in order that it might be incorporated with the Royal Society of Medicine.

OUR Society, which enters on a new career to-day, was founded in 1846.

The first President was Dr. C. J. B. WILLIAMS, a pupil of Laennec, an accomplished pathologist and experimenter in more than one direction, a man of high character, to whom I, as a young physician, was more than once indebted. He was followed, after two years, by a surgeon, and this alternate choice between the two branches of the profession has been preserved until very recently.

In 1848 Mr. ASTON KEY succeeded the Presidency ; a brilliant surgeon, who was prematurely cut off by the epidemic cholera of 1850. His successor, Dr. PETER MERE LATHAM, was best known by his admirable lectures on medicine, almost equal in style to those of Paget, delivered at the same celebrated medical school.

The second surgical President, Mr. CÆSAR HAWKINS, of St. George's Hospital, died before he had completed his term (1853), and was followed by Dr. GUY BABINGTON. This son of the eminent physician and mineralogist, whose statue stands in St. Paul's Cathedral, was also a remarkably accomplished man. He was sent to sea as a midshipman, and was present at the battle of Copenhagen. He was afterwards Professor of Tamil, in India, and graduated from Pembroke College ; a learned physician, and

the physiologist who first defined the blood, not as consisting of serum and clot, but as of corpuscles and liquor sanguinis, or plasma (as we now call it). He also invented a "glottiscope" in 1829 to enable the vocal cords to be seen, an earlier though less perfect instrument than those of Garcia (1855), and Türck (1857), and Czermak and Türck (1858). The name "speculum laryngis," or laryngoscope, was given by his colleague, Dr. Hodgkin.

Babington was succeeded in 1855 by Moncrieff Arnot, a Scottish surgeon of wide scientific knowledge, which he used with liberality and ingenuity in practical hygiene.

In 1857 Sir Thomas Watson became President; a man beloved and honoured like Babington, and master of a style as classical and more easy than that of Latham.

Sir William Fergusson, the eminent Scottish surgeon, of King's College, became President in 1859, and was succeeded by Dr. Copland, the author of a once popular cyclopædia of medicine.

The next President was Sir Prescott Hewett, an accomplished surgeon and a most skilful operator.

His successor in 1865, Dr. Peacock, was one of the best Presidents we have ever had; a master of pathological anatomy, as well as of medicine, liberal and honourable, and not without a touch of humour on occasions. Like Fothergill, he was a member of the Society of Friends.

He was followed by Sir John Simon (1867), senior surgeon, as Dr. Peacock was senior physician, of St. Thomas's Hospital. He was an able surgeon and a distinguished pathologist, but his general work was advising the Local Government Board on questions of public health, and his reports were remarkable for their scientific and practical value, as well as for their precise and elaborate style, which sometimes reached eloquence.

Sir Richard Quain was the next President; an Irishman, with the full share of his countryman's ready wit and strenuous energy. His researches on fatty degeneration of the heart were of original value. He was the chief motive power in making the useful and necessary change from our original house in Berners Street to the present spacious rooms, and he would have been delighted to see the union of societies which is now an accomplished fact. As President of the General Medical Council

he gave a noble example of devotion to duty when knowing that he was the subject of incurable disease.

The next surgical president was JOHN HILTON (1871), an accomplished anatomist, an admirable teacher, and an original observer. His lectures on Rest and Pain were justly called by Giraldés "ce grand ouvrage de Mons. Hilton."

A man no less eminent, upright and plain-spoken was Sir WILLIAM JENNER, for many years the Capo di Scuola at University College. He was a true pathologist, and, as the acknowledged head of the profession, set a bright example of great talents used for the benefit of the public and the profession. Those of us who saw him introducing a deputation to the Home Secretary, Sir Richard Cross, will never forget his eloquent defence of scientific investigation.

The following President was Mr. GEORGE POLLOCK, of St. George's Hospital, member of a family renowned in Law and in Arms, as well as in medicine, and himself a judicious and successful surgeon.

Mr. POLLOCK was followed by Dr. MURCHISON (1877), a pupil of Hughes Bennett at Edinburgh, and long a remarkable bedside teacher at St. Thomas's Hospital, who, like Peacock, was removed by sudden death when visiting a patient. He was an eminent pathologist and an excellent geologist as well as a clinical teacher.

The next President was Mr. HULKE, a sound surgeon, an accurate pathologist, and sharing with the elder Babington and Murchison the honour of eminence in geology, for Mr. Hulke was president of the Geological Society and of the College of Surgeons, as well as of our Society.

Dr. BRISTOWE, of St. Thomas's Hospital, was a friend and colleague of Wilks, whom he rivalled in the number and value of his contributions to this Society. He was an admirable teacher and a cultivated and liberal man.

The majority has long received the next President on our list, Sir JAMES PAGET (1887), one of the most eminent pathologists this Society can boast. All his observations were accurate, and his exposition clear and concise. His insight was remarkable and wide. In purity of style and in oratory he outstripped all his fellows. His son's biography is a remarkable success in a difficult task.

Sir George Humphry, of Cambridge, was an admirable lecturer, a keen observer, and a philosophical anatomist. The services he rendered to the Medical School at Cambridge deserve to be held in everlasting remembrance.

Much more recently this Society has been deprived by death of Sir John Burdon Sanderson, who became President in 1902. An eminent and accomplished pathologist, who touched every allied subject and who adorned all that he touched. His work in University College, and at Oxford, has been well described by his successor, Professor Gotch. His lofty stature, his fine features, his dignity and urbanity, combined to form a figure of singular interest.

As a teacher and a writer he was no less admirable. His best original work lay in that fruitful field which lies on the confines of geology and botany.

Such is the list of our past Presidents who have joined the majority. But we thankfully and proudly point to no less distinguished men who are still with us. I could not do justice to their merits, and must content myself with barely reciting the names of our surviving presidents: Sir Samuel Wilks, Mr. Hutchinson, Dr. Dickinson, Dr. Pavy, Mr. Butlin. Dr. Payne, and Mr. Watson Cheyne.

May they long enjoy their well-earned reputation, and rest assured that we regard them with pride and gratitude, with admiration and affection.

When our Society was founded, pathology was still the handmaid of medicine and surgery, as is shown by the names I have cited. The science has now a far more independent position, and is the foundation or *institute* on which all scientific prevention and treatment of diseases must rest. The study of morbid anatomy was the beginning of rational pathology. Then followed experiments on living animals, like those of Harvey himself, of Mayow, of Stephen Hales, of Hunter, and of Sir Charles Bell. Since 1846 we have seen the rise and vast progress of bacteriology as the third and most important chapter in the causation of disease.

The fourth division of pathology is chemical, at present in its infancy, but probably destined to open many fresh paths to investigation. Especially fruitful will probably be the borderland between animal and vegetable pathology.

The recent investigations by Professors Halliburton and Mott into degeneration of nerve-fibres deal with the conditions, not only histological, but also chemical. Moreover, by an unexpected series of observations it appears to be demonstrated that a parallel series of changes—after Wallerian degeneration of nerve-fibres, but in the reverse order—may lead to a restoration of the axis cylinder and ultimately of the whole injured nerve-fibre.

At present the future of experimental pathology lies on the knees of the Royal Commission on Vivisection. Let us hope that the result will be to give greater freedom for experimental methods.

The minute anatomy of disease is not yet complete.

The chemical aspect of pathology is not more than begun, and our contributions in this department are comparatively few, though in value they have been great.

Nowhere is the ground more promising than on the confines of physics and physiology, between botany and zoology, between chemistry and physics.

The investigations embodied in Professor Farmer's admirable lecture before the Royal Society show how complicated may be the structure of a single cell. But complicated or simple, it still baffles all attempts to explain its functions and their mechanism.

To apply the words of an anonymous poet of the seventeenth century: In the ovum or the germ-cell

> "The thread of life untwisted is
> Into its first consistencies;
> Infant nature cradled here
> In its principles appear."

And, so untwisted, its principles are as great a puzzle as ever.

REPORT.

SESSION 1906—1907.

---

1. *Chorion-epithelioma of testis.*

By T. W. P. Lawrence.

The tumour is ovoidal in shape, and measures 11 cm. in length and 6 cm. in breadth. The two layers of the tunica vaginalis are adherent over its lower part, but free superiorly, and in the latter situation the surface of the growth forms rounded lobulated projections into the cavity of the tunica vaginalis. The compressed body of the testicle is situated on the surface of the growth at its upper and anterior part.

On section the tumour is found to be divided into lobules by septa of fibrous tissue passing inwards from the periphery. In many places the septa are stained of an orange colour. The tumour-substance shows no definite structure to the naked eye; it is of a pale-brown colour, with scattered spots of dark-brown pigment in places. The section gives the impression of being extensively hæmorrhagic in almost every part, its comparatively pale colour being due, apparently, to long immersion in spirit. In several places small cysts are visible, which have smooth inner surfaces, and are free from intra-cystic growths.

The specimen, which is without a history, has been for many years in the Museum of University College, London (No. 2164), as an example of mixed sarcoma and carcinoma. The true nature of the growth was first recognised by Mr. Raymond Johnson.

Microscopic structure.—In all parts of the growth necrotic tissue, fibrinous coagulum, and blood largely predominate. Enclosed within the necrotic tissue islands occur in which

the vitality of the cell-elements is retained. These non-necrotic areas consist of tracts of fibrous tissue containing large blood-spaces in such abundance as to give the growth the appearance of a cavernous angioma. In one or two places the blood-spaces have, in addition to an endothelial lining, an outer coat composed of fibrous tissue and smooth muscle-fibres. In other parts they are devoid of a muscular or fibrous coat, and present merely an endothelial layer resting directly on the somewhat loose and cellular connective tissue which separates one blood-space from another and constitutes the central tissue of the fibrous tracts. In most situations that part of the loose connective tissue which is immediately adjacent to the endothelium is replaced by a well-defined stratum of cells, which form the most characteristic feature of the growth. The cell-strata are of two kinds: In one the cells are large, tolerably uniform in size, mostly polygonal in shape, with very definite contours and an abundant protoplasm which stains deeply, and with a single, deeply staining nucleus (large mononuclear cells). Scattered among these cells, which are placed in close contact, are others of larger size, more rounded form, and having, in some instances, two or three nuclei. Cell-strata of this kind appear as long, continuous bands or ribbons bounding the endothelial spaces in the whole or in part of their circumference. The endothelium is in many places intact and unaltered; in some it is absent, and in these situations the exposed surface of the cell-stratum may be coated towards the lumen of the blood-space by multinucleated giant-cells or by a narrower syncytial layer. The second form of cell-stratum is less continuous and less ribbon-like than the former; the cell-masses are broken up into clumps of rounded or irregular form, but in all cases some part of their circumference is in close relation with the blood-spaces. They are composed of detached or anastomosing nucleated plasmodial masses, amidst which are irregular areas of small rounded cells with pale and scanty protoplasm (Langhans' cells). The plasmodial masses are in places vacuolated, in one or two places to such an extent as to form a wide-meshed reticulum. The endothelium adjacent to the plasmodia may be present and unaltered, but in many parts it is absent.

The mode in which the cellular tissue bounding the blood-spaces becomes replaced by the cell-masses can be studied in

several parts where the process is but slightly advanced. The tissue becomes infiltrated with the large mononuclear cells, the process commencing in that part of the tissue which is immediately adjacent to the endothelium; no prelimary destruction of tissue occurs, nor is there any leucocytic infiltration or new formation of stroma, no alveolar spaces are produced, and the cells do not form into masses which shrink away from the surrounding tissue in the manner commonly seen in carcinomata.

In one or two places, where the cell-strata have become intravascular by the destruction of the endothelium, the cells are found to have closed up over the orifices of small tributary vessels, and to have grown into these tributaries in the form of slender, ramifying, solid columns of cells, detached on all sides from the channels in which they lie, and presenting an appearance very similar to that of a scirrhous carcinoma.

The extensive blood-extravasation which is present in all parts of the growth appears to arise through actual breach in the continuity of the vascular walls; the endothelium becomes destroyed, as above mentioned, the corresponding segment of the subjacent cell-stratum becomes necrotic, and the blood thus gains access to the surrounding tissues.

In several parts of the growth, and occupying considerable areas, small tubular spaces are found, which are lined by a single layer of small cubical epithelium with clear protoplasm. In parts the lumina of these tubules open out into larger spaces and clefts of elongated and irregular form, and here the epithelium becomes modified. In these parts the cells may become disposed in two or three layers, and their protoplasm, instead of being clear, is opaque, stains readily, and is more abundant; the definite outline of individual cells is less distinct, and the protoplasm of adjacent cells in some instances apparently becomes confluent. The form of the cells also changes; some cells become columnar, others polyhedral, and in one spot a transition to a form very similar to that of the large mononuclear cells can be traced, but no direct continuity with cell-strata of the latter kind of cell occurred in the sections examined. The lumina of the tubules are either empty or contain coagulated material and blood-corpuscles.

Small areas of myxomatous tissue and cartilage are scattered sparsely through parts of the growth. Where the tumour is in contact with the testicle the fibrous stroma of the growth is

directly continuous with the connective tissue of the gland, and no definite capsule is present. There is an extensive leucocytic infiltration in many parts of the tumour.

The growth appears to be of the nature of a chorion-epithelioma occurring in a teratoma of the testis. (*May 15th*, 1906.)

---

2. *Two cases of tumours resembling chorion-epithelioma occurring primarily in the testicle.*

By J. M. Bernstein.

The specimens from the first case I wish to bring before you this evening are the left testicle and one lung removed *post mortem* from a man, aged 34 years, who died in the Westminster Hospital in October, 1898, after a history of enlargement of the testicle for four months and abdominal pain for six months.

The *post-mortem* notes, by Dr. Hebb, are as follows: Body emaciated; chest large; left testicle much enlarged, spheroidal, weight 18 oz. On incision testicle found to be supplanted by a soft spongy neoplasm, highly vascular, and centrally much degenerated. The growth spreads along the cord into the abdomen, where it communicates with a mass the size of a fœtal head at term, of soft, yellowish-white, malignant deposit in the abdominal prevertebral glands. In this mass is involved the left ureter. Left kidney in a condition of simple hydronephrosis. Liver 112 oz., measuring 14 × 9 × 4½ in., and bestudded all over, but chiefly in its central moiety, by soft, spongy, hæmorrhagic new growth. In the gastric and intestinal mucosa are several firm polypoid deposits of blackish hue. In both pleural sacs one to two pints of sanious fluid. Both lungs bestudded with spheroidal masses varying in size from a pea to a hen's egg, of soft consistence, spongy appearance on section, most dark-purple from hæmorrhage, but a few whitish. Remaining viscera normal.

In the 'Westminster Hospital Reports,' vol. xi, pp. 322, 323, Dr. Hebb reported on this case as follows: "The microscopical appearances are those of sarcoma. . . . The growth bears certain (*i.e.* definite) resemblances to deciduoma malignum, there

being present plasmodial cells, ordinary giant cells, cells of every kind and shape, and large thin-walled blood-vessels." Thus succinctly yet practically summing up all the salient features of the case, Dr. Hebb, as early as 1898, recorded one of the few cases of this uncommon disease.

The left testicle, with the spermatic cord thickened by infiltrating growth, and part of one lung, with the original colours

FIG. 1.

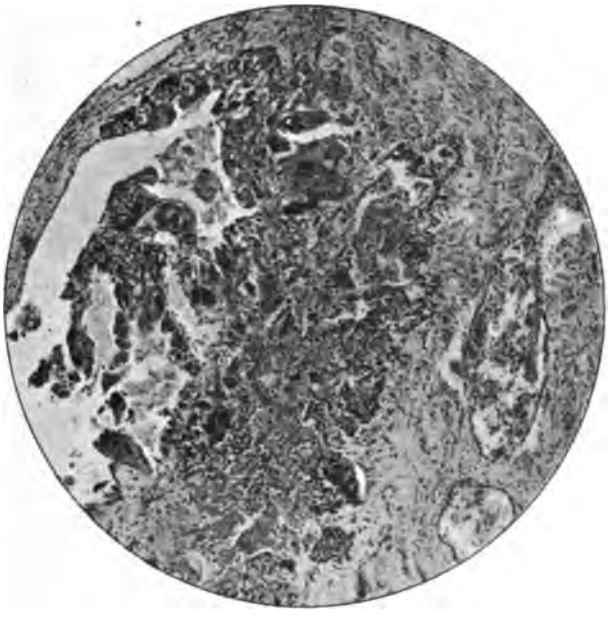

A transverse section of the growth in the testicle ($\frac{2}{3}$ objective). The detail is better discerned with the aid of a hand lens. On the left is a space containing some blood *débris*, and lined with darkly staining syncytial cells (many of which have fallen out of the section) and surrounded with Langhans' cells. In the upper part of the field to the right of the space is shown a large mass of multinucleated syncytium. Centrally the two types of cells are intermingled. On the right side is shown degenerated tissue and some blood-spaces.

well preserved, are placed on the table and correspond with the above descriptions. The largest growth in the lung is 3 in. in diameter. Several are whitish in colour, but most hæmorrhagic, with whitish areas. The intervening lung-tissue is normal. A slice of the liver is also preserved, and shows one large hæmorrhagic growth 3 in. in diameter, and numerous smaller nodules in the midst of normal hepatic tissue. The microscopical

appearances are for the most part degenerated tissue, and the structure can only be defined at the edge of the growths. In the testicle two types of cells are distinguishable: (1) accumulations of round to oval cells of rather large size, with large nuclei, staining irregularly, and showing an intra-nuclear network, and recalling strongly the cell of epiblastic origin. These cells are often polyhedral from mutual pressure, but have no intervening

FIG. 2.

A transverse section of one of the metastatic growths in the lung ($\frac{2}{3}$ objective). The detail is better discerned with the aid of a hand lens. An irregular blood-space lined by fibrin and surrounded by columns of polyhedral cells simulating a hæmangeio-endothelioma. In the lower right quadrant and in the upper part of the figure are several masses of darker-stained syncytium.

connective tissue. Sometimes karyokinetic figures are seen. (2) Areas of deeper staining protoplasm of varying size forming fusiform, roundish, or large irregular masses containing one or more, and frequently an enormous number, of small, oval, nuclei, staining very deeply. The protoplasm is sometimes vacuolated, and has no definite cell outline, and resembles the syncytial cells of chorion-epithelioma. These plasmodia are sometimes found in the midst of a mass of round cells, sometimes bounding spaces

containing blood and *debris*. Many of these spaces are accidental, but others are evidently true blood-channels bounded by syncytial-like cells, more or less flattened, and surrounded by the round to oval cells (Fig. 1). These types of cell correspond in structure to the syncytium and cells of Langhans of the chorionic growths respectively.

In the secondary growths in the lung also there is very little not degenerated. The prevailing type of cell is the polyhedral (Langhans'), arranged generally in columns, surrounding spaces containing blood and resembling the so-called hæmangeio-endothelioma, though the spaces are somewhat irregular and at times have a bordering layer of fibrin (Fig. 2). In places in the midst of these perivascular columns of cells a larger multinucleated mass of plasmodia appears, but this type is not prominent, and where present is generally mixed with recent blood, and at times appears to be elongating and uniting to form new blood-vessels.

In the hepatic growths the structure is well seen, and resembles the primary tumour, specially prominent being the elongating and branching multinucleated masses of protoplasm. The tendency to hæmorrhages is as well marked here as elsewhere.

The second case is that of a man aged 29 years, who died shortly after admission to the Westminster Hospital. The *post-mortem* notes are as follows: Right testicle converted into a red globular mass the size of a cricket-ball; left testicle normal; a few enlarged right iliac glands, lumbar glands normal. Both pleural sacs contain blood-stained fluid and both lungs are infiltrated with nodules of new growth. All the growths are extremely hæmorrhagic.

Half the testicle and portions of the lungs are here shown. The spermatic cord is unaffected. The growths resemble the previous case, but with some variations in detail. The greater portions are degenerated. In the testicle the two types of cell already described occur, viz. the epiblastic type (Langhans' cells), arranged along what seems to be the wall of a large blood-space with several multinucleated plasmodia intermixed. These "syncytial" cells, of all sizes and shapes, in places seem to be rapidly proliferating and forming narrow channels containing blood. But in the central parts of the growth these are seen

more or less completely degenerated. In the lung sections the rapidly proliferating plasmodia are very well marked, forming peculiar irregular-shaped masses, with oval nuclei, amongst blood and polyhedral cells, and around these growing into the surrounding tissue until lost in the degenerated areas. In other parts most conspicuous is the presence, amongst much blood and *debris*, of narrow anastomosing columns of polyhedral cells

FIG. 3.

A transverse section of a hæmorrhagic portion of one of the metastases in the lung ($\frac{2}{3}$ objective). Passing transversely amidst a mass of darkly staining blood and *débris* there is a group of more lightly stained, new-formed branching, vascular channels; on the right side these form a larger blood-space, as described in the text. The network of spaces are artificial fissures in the blood-clot.

bounded by elongated and fusiform plasmodial cells, which in places spread out into multinucleated masses. These columns are sometimes solid, sometimes the cells form a reticulum, in the meshes of which blood is found, and sometimes they form vascular tubes, all of which are found in various stages of degeneration (Fig. 2).

Summary.—These two cases are examples of primary tumours of the testicle of great malignancy, with dissemination by the

blood-stream. Though showing many variations in minute structure, they consist essentially of cells resembling Langhans' cells and the syncytial cells of the chorion. These arrange themselves in masses, surround blood-spaces (either by growing along the walls of pre-existing channels or by forming new ones), or form new capillaries which apparently rupture and cause destruction of the new-formed tissue by pressure of the extravasated blood.

The similarity between these growths and true chorion-epithelioma is so great that I have thought it advisable to add them to the number of such already recorded.

In neither case is there any evidence of teratomatous structure or chorionic villi such as described in some of the previous cases.

All the specimens here described are preserved in their original colours in the museum at the Westminster Hospital.

May 15*th*, 1906.

3. *On chorion-epitheliomata of congenital origin.*

By Victor Bonney.

On the Occurrence of Chorion-epitheliomatous Growths apart from Pregnancy.

Since the publication of Teacher's monograph on chorion-epithelioma (1) it is generally accepted here, as on the Continent, that these neoplasms when associated with pregnancy arise from the non-fœtal portion of the embryonic ectoderm or "trophoblast" (Hubrecht).

Within the last few years, however, tumours simulating chorion-epithelioma have been described, not only in women in the absence of pregnancy, but also in men. By far the greater number of these have arisen in pre-existing teratomata. The credit of the suggestion that these tumours are really chorion-epitheliomata arising from chorionic elements present in the teratoma is due to Schlagenhaufer (4). Subsequently Pick (5–9), working, not only independently, but on material derived from quite different sources, confirmed his views.

The acceptance of this view must be based on the proof of two propositions:

(1) That the histological features of the group of tumours under consideration are identical with those of chorion-epithelioma.

(2) That they arise from cells ontogenetically identical with those of the trophic ectoderm of the embryo.

The Histology of Chorion-epithelioma.

A short recapitulation of the histology of chorion-epithelioma is necessary in order that the class of tumours with which this paper is concerned may be compared with them.

Macroscopically chorion-epitheliomata present a dark red colour and the larger masses have frequently a lobulated outline. On section their appearance is quite characteristic, the peripheral parts of the tumour presenting a number of dark red hæmorrhagic areas interspersed with smaller cream-coloured patches. Centrally the tumour usually consists of necrotic cell elements, decolorised blood-clot, and fibrin.

Microscopically they contain three types of cells, without intercellular stroma, but lying in irregular masses in or between areas of fibrin and blood-clot. These types are as follows:

(1) *Hyaline cells.*—Small, closely packed, polyhedral cells with a singularly transparent cytoplasm and a rounded nucleus which exhibits a loose chromatic network. These cells are usually arranged in masses, having a somewhat festooned outline, and are not found isolated amongst the fibrin elements or invading singly the pre-existing tissues.

(2) *Syncytial masses.*—Large syncytial masses containing many nuclei, some of which are small and stain deeply; others are much larger, lobulated or reniform in outline, show a distinct chromatic network, and are usually vacuolated. Syncytial masses vary enormously in size. Some are very large, with irregularly pointed processes, whilst others are thin and elongated and the nuclei contained within them compressed and flat. The latter form is most commonly observed, bounding the festooned masses of hyaline cells already described. Syncytia are usually found on the surface of a blood-containing space.

(3) *Large mononuclear cells.*—Large, irregular, mononucleated

cells of varying character, which appear to originate both from the hyaline polyhedral cells and the syncytial masses. In the

FIG. 4.

A portion of the wall of an early tubal gestation-sac showing syncytia bounding the intervillous blood-space, large mononuclear cells invading the tubal muscle, which has undergone fibrinoid degeneration, and a group of young hyaline Langhans' cells. (Obj. 1 inch. Ocular No. 8 Zeiss. Camera lucida.)

FIG. 5.

Another portion of the wall of an early tubal gestation-sac showing a mass of cells indistinguishable from chorion-epithelioma. (Obj. 1 inch. Ocular No. 8 Zeiss. Camera lucida.)

first case the cytoplasm of the small hyaline cell appears to increase in size owing to the deposit in it of granules of glycogen, whilst the nucleus becomes larger, ovate, and increasingly

chromatic. The tessellated appearance of the cell mass remains, however, and indicates its origin. When originating from syncytia the cells can be distinguished from the preceding group by their isolation, by their very large, irregular, vacuolated nuclei, and by their homogeneous, non-granular cytoplasm. They are found imbedded in masses of fibrin or blood-clot.

The author, in conjunction with Comyns Berkeley (3), published the results of an investigation into the histology of early tubal gestation, and we have no hesitation in saying that all the cell forms just described can be seen in the wall of an early extra-uterine gestation-sac. The small hyaline cells are identical with the Langhans' cells of the chorionic villus, the syncytial masses are identical both in position and character with those bounding the periphery of the intervillous blood-spaces, whilst the mononuclear cells are identical with the large cells invading

FIG. 6.

A chorionic villus from an early vesicular mole showing proliferation of young Langhans' cells. (From a slide of Dr. John Teacher's. Obj. 1 inch. Ocular No. 8 Zeiss. Camera lucida.)

the tubal muscle or imbedded in the fibrin masses (Figs. 4 and 5). But whilst the general cell features described are common to all these tumours, there exist between individual specimens great differences as to the proportions in which these varying cell types are found. These various forms have been especially studied by Marchand (2), who divides the chorion-epitheliomata into typical and atypical varieties. Thus tumours have been described consisting almost entirely of the young hyaline Langhans' cell ("Langhanseoma"); others, again, are almost entirely made up of syncytium ("syncytioma malignum"). The *young* hyaline Langhans' cell (*vide* Figs. 4, 6, and 7) is, perhaps, the rarest cell type in these growths. More commonly the predominant form is the large mononuclear cell already as described as originating from the Langhans' cell by hypertrophy and accumulation of glycogen and chromatin. In some

tumours, or in certain parts of the same tumour, the second type of large mononuclear cell—namely that derived from the breaking up of the syncytial mass—is most noticeable. On

FIG. 7.

Section of a chorion-epithelioma of the uterus associated with pregnancy. The growth is made up entirely of young hyaline Langhans' cells interspersed with syncytia. (Drawn from a slide of Dr. John Teacher's with his kind permission. Obj. 1 inch. Ocular No. 8 Zeiss. Camera lucida.)

Figs. 7 and 8 the histological characters distinguishing two different types of uterine chorion-epithelioma are shown.

Besides the pure chorion-epitheliomata, tumours are known which bridge the gap between them and the vesicular moles. Such tumours possess, not only elements derived from the trophic

ectoderm, but also the whole structure of villi in a state of vesicular degeneration, and, consequently, they may be rightly termed "choriomata." At the other end of the series are the

FIG. 8.

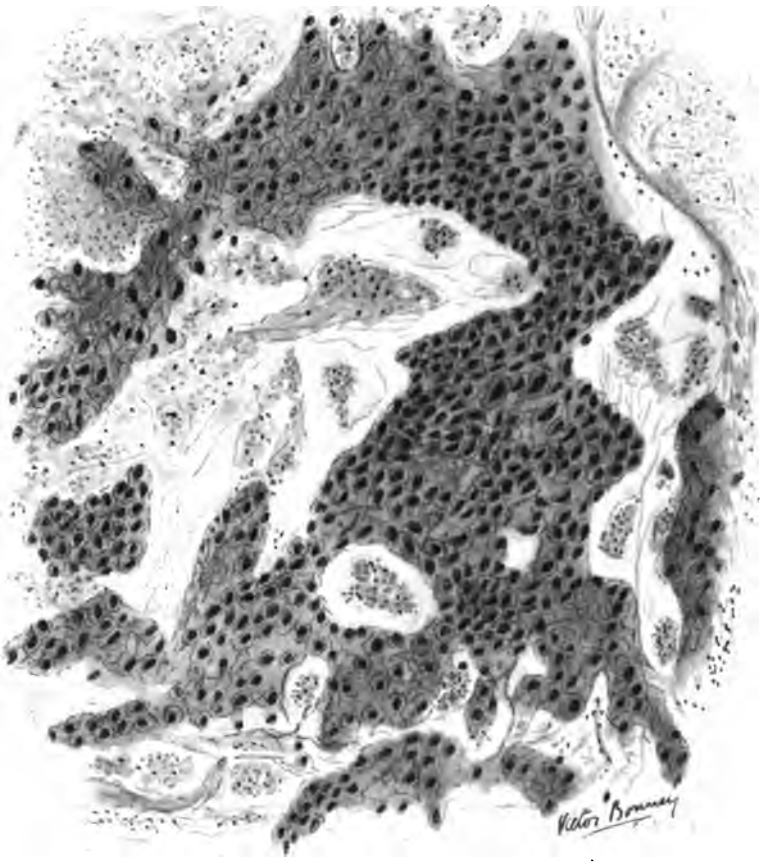

Section of chorion-epithelioma of the uterus associated with pregnancy. The growth is made up entirely of large mononuclear cells loaded with granules of glycogen and presenting a deeply chromatic nucleus. The cells are lying in masses amongst areas of blood-clot and fibrin. (Drawn from a slide of Dr. John Teacher's with his kind permission. Obj. 1 inch. Ocular No. 8 Zeiss. Camera lucida.)

vesicular moles proper, which exhibit various degrees of invasional activity ranging between malignancy and innocency.

On the Histological Identity of certain Tumours originating apart from Pregnancy with recognised Chorion-epithelioma.

(A) *The Author's Cases.*

Case. 1.—By the kindness of Dr. Karl Fürth I have been permitted to publish the following case:

F. R—, aged 69 years, a bootmaker, was admitted into the German Hospital, Dalston, on September 12th, 1905. He had been quite well until eight weeks previously, when he noticed slight swelling of his ankles. This extended upwards to his legs; later the abdomen became enlarged. He lost appetite and flesh, but had been at work until his entrance into the hospital.

On admission he was thin and cachectic in appearance, and had marked œdema of both legs. The heart and lungs were normal. There was considerable ascites and marked distension of the superficial abdominal veins.

In the middle line, between the pubes and umbilicus, was situated a hard mass, somewhat ill-defined on account of the ascites. It was not painful, but the patient complained of a distressing sensation of fulness and distension. The urine and stools were normal.

On September 14th the stomach-tube was passed and the contents of that viscus examined. No free hydrochloric acid was present, but there was an absence of lactic acid and bacteria.

On September 21st the abdomen was tapped and 4000 c.c. of sero-sanguinolent fluid was withdrawn; the patient, in spite of this temporary relief, subsequently died.

At the autopsy the following condition was found:

The abdomen was full of sanguinolent fluid. Immediately underneath the anterior abdominal wall and apparently situated in the great omentum was a tumour the size of a man's head, of lobulated shape, of a deep red colour, and of soft consistency. On section it was solid throughout, and presented a number of hæmorrhagic areas interspersed amongst others of a pale pink or buff colour. Above it was adherent to the greater curvature of the stomach, and elsewhere it was surrounded by many adhesions.

The liver was considerably enlarged, nodulated, and contained a number of metastases, which varied in size from a pea to an orange. These growths externally were of a deep red colour. Their appearance on section (Fig. 9) resembled in a striking manner the naked-eye appearance of a chorion-epithelioma. No other secondary growths were found. The other organs of the body were normal. Both testes were incised, but no pathological appearances were present.

FIG. 9.

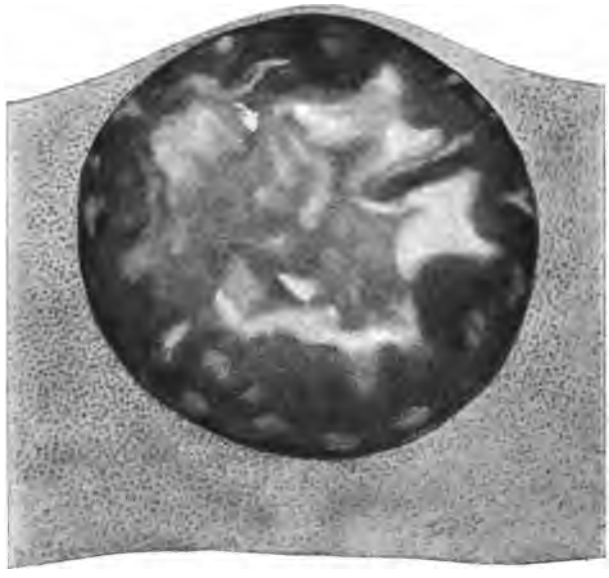

Hepatic metastasis from the author's first case. The nodule is markedly circumscribed. Its periphery is made up of extensive blood-extravasations intermixed with tumour cells. The centre is necrotic.

Portions of the primary tumour were removed for microscopical investigation and a piece of the liver was preserved in Kaiserling's solution. Unfortunately, the bulk of the primary tumour was not kept. The tissues reserved for microscopical examination were fixed in formalin, imbedded in paraffin, and the preparations were stained by hæmatoxylin and eosin; these preparations were investigated by me at the Cancer Research Laboratories of the Middlesex Hospital, when it was recognised that the tumour bore a striking resemblance, not only macroscopically but microscopically, to chorion-epithelioma.

The primary tumour presents a well-marked capsule of fibro-cellular tissue, infiltrated in many parts with blood, and covered on its external surface by a layer of endothelium. Immediately against the capsule are masses of cells which present a sharply defined growing edge. These masses are arranged in an irregular manner, being partially separated from one another by aggregations of blood or strands of fibrin, containing leucocytes, which often penetrate between the individual cells.

In a few places prolongations inwards of the capsule are visible, but except for these no intercellular stroma is present.

As the central portions of the tumour are approached the aggregations of blood and fibrin become larger, and the groups of

FIG. 10.

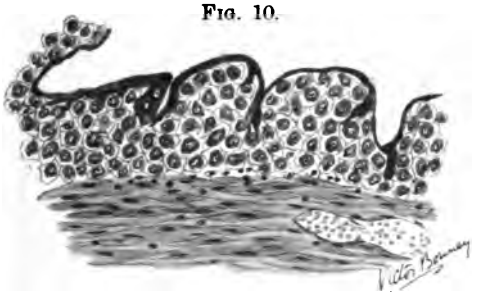

The author's first case. A portion of the primary tumour. Immediately under the capsule are seen festooned masses of small cells, with hyaline cytoplasm and round vesicular nuclei. They are bounded on their further surface by delicate syncytial strands simulating an endothelium. (Obj. 1 inch. Ocular No. 8 Zeiss. Camera lucida.)

cells more scattered. Deeper still, marked evidence of necrosis is seen, the areas of the blood-clot becoming decolorised and structureless, fibrin masses predominant, and the tumour-cells pale and indistinct.

The cell elements of the growth are of three distinct types:

(*a*) Immediately under the capsule is a track of small hyaline cells, massed together in a "tessellated" manner, and exhibiting a vesicular-looking nucleus with a distinct chromatic network. These cells are thrown into festoon-like masses.

(*b*) Large irregular syncytia of very variable shape. They are seen bounding the festooned masses of hyaline cells and dipping down between them as thin processes. Here they are very narrow, and resemble an endothelium (Fig. 10). In other parts they run in towards the capsule in a series of elongated flame-like strands. Elsewhere they present irregular shapes

with fine pointed processes extending out amongst the other cell elements. Their nuclei vary greatly, being elongated, flattened, and deeply chromatic in the narrow strands, but lobulate, pale, and vacuolated in the larger masses.

(*c*) Irregular cells exhibiting all gradations in size and shape between the hyaline cells and the syncytia. In some parts they obviously originate by syncytial disintegration, but in others exhibit continuity with the small hyaline cells. In general their shape is irregular but their cytoplasm chromatic and their nuclei large and variable in appearance. Thus these may be vesicular, deeply chromatic, or vacuolated, and in shape round, oval, or lobulate. Not infrequently giant nuclei are observable, whilst in some cells the nucleus is divided into two halves by a thin transparent line. In the central portions of the tumour these cells become more isolated amongst the masses of fibrin.

Leucocytes are sparsely seen at the growing edge, but are present in great quantity in the central parts of the tumour amongst the masses of fibrin and blood-clot. In the necrotic areas they appear to have remained intact longer than the other elements, their nuclei standing out amidst the general pallor.

The metastases in the liver present the same general appearance (Fig. 11). The growing edge is well defined, the liver-cells in this situation are compressed, and there is a complete absence of any reaction to the tumour-cells, which resemble those of the primary growth, except that the small hyaline cell is nowhere observable. Especially noticeable are certain large spaces, whose walls are bounded either by syncytia or by very large mononuclear cells with giant nuclei. These spaces contain unaltered blood.

The peripheral parts of the metastases exhibit large intercellular extravasations of blood, but centrally they are necrotic like the primary tumour.

No elements suggesting a teratomatous origin were present in any of the preparations made from the primary tumour, but it must be borne in mind that only a very small portion of it was available for investigation.

Case 2.—This case, the microscopical preparation of which I owe to the kindness of Dr. Stevens, is a testicular tumour removed for suspected malignancy.

The clinical history is, unfortunately, wanting.

Microscopically, the growth consists of two parts: (*a*) typical chorion-epitheliomatous tissue imbedded in masses of blood and

FIG. 11.

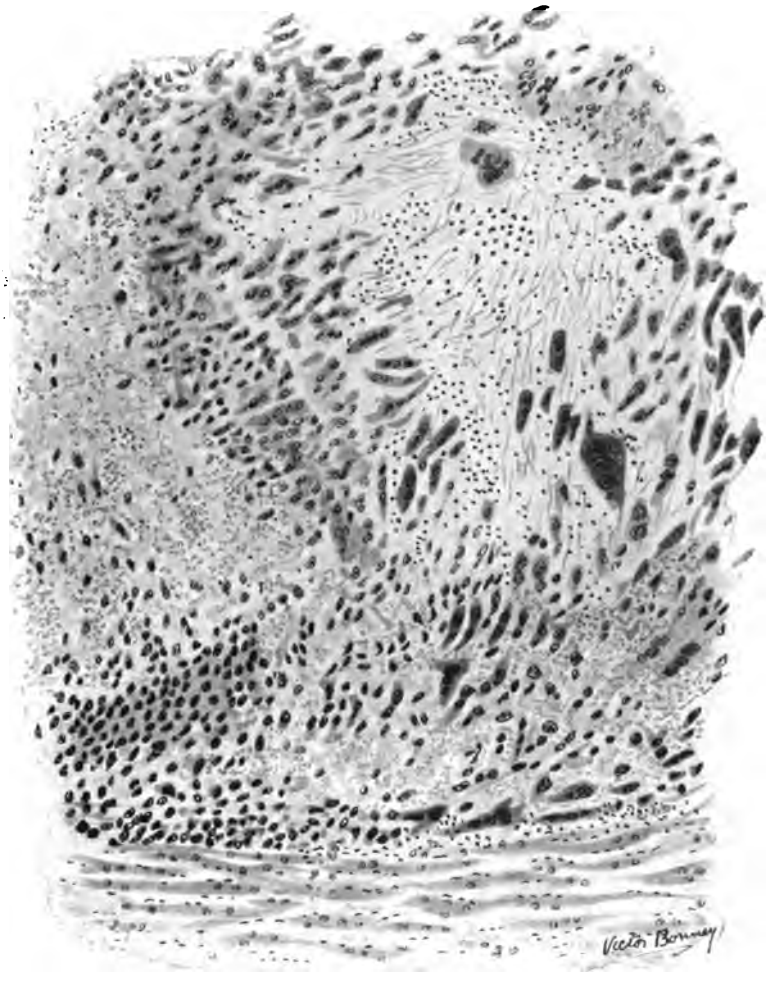

The author's first case. A portion of a metastasis in the liver. The tumour here consists of large syncytial masses and mononuclear cells of varying character. In the centre of the field is a pale area of laminated fibrin containing leucocytes. Elsewhere masses of blood are seen in which cell elements of the tumour are lying. The liver-cells seen below are compressed and flattened. (Obj. 1 inch. Ocular No 8. Zeiss. Camera lucida.)

fibrin, and (*b*) hyaline cells arranged in ill-formed tubules which in many parts have proliferated so that all trace of tubular

structure is lost. The arrangement of these cell-masses cannot be termed "alveolar." They lie in an irregular manner, being separated from one another by strands of fibrin, which in many parts interpenetrate between the individual cells. These cells resemble the hyaline cells of the typically chorion-epitheliomatous portion, but direct conversion into them is not apparent in the slide I possess.

CASE 3.—This case I also owe to Dr. Stevens. It is a testicular tumour presenting a typical teratomatous structure. Within a fibrous matrix are found a great variety of epithelial types.

FIG. 12.

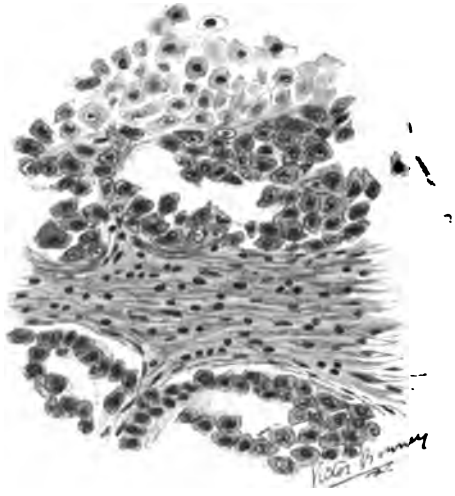

The author's third case. A field showing large polyhedro-columnar cells in irregular alveolar arrangement. In the upper part of the field these cells have degenerated. (Obj. 1 inch. Ocular No. 8 Zeiss. Camera lucida.)

Thus spaces are found lined with squamous, cubical, or well-marked columnar epithelium. In many places spaces are found lined partly with cubical or columnar cells and partly by stratified squamous epithelium. These types merge one into another. Especially to be noted, however, are certain large polyhedral cells having a somewhat granular cytoplasm and a vesicular nucleus. They are arranged in masses as a rule, but in certain parts assume a rudely columnar appearance on the wall of an alveolar space (Fig. 12). In several fields these cells may be seen undergoing a conversion into a typical chorion-epitheliomatous tissue. Wherever this change is going on large blood-

extravasations occur (Fig. 13). I have with great interest compared these slides with others lent me by Messrs. Spilsbury and

FIG. 13.

The author's third case. Another field from the same slide showing conversion of the large polyhedro-columnar cells into chorion-epitheliomatous tissue. (Obj. 1 inch. Ocular No. 8 Zeiss. Camera lucida.)

Hicks. Spilsbury's case (42) was a typical teratoma of the testis. In it, besides many epithelial types, are found these same

FIG. 14.

Dr. Spilsbury's case of testicular teratoma. A group of polyhedro-columnar cells in alveolar arrangement identical with those seen in the author's third case. With acknowledgments to Dr. Spilsbury. (Obj. 1 inch. Ocular No. 8 Zeiss. Camera lucida.)

large polyhedral cells which I have already noted. Here, also, the same tendency to occasional "tubular" arrangement is

noticeable. Direct conversion into a chorion-epitheliomatous tissue is absent, though a few isolated syncytial masses are present (Fig. 14).

In Hicks' specimen (43), which is a typical testicular teratoma, there is an isolated area containing a pure chorion-epitheliomatous tissue which can be seen to be proliferating from these same large polyhedro-columnar cells. Dr. L. Pick has kindly sent me a slide from a case of his own showing these cells in marked adeno-carcinomatous arrangement. One portion of the slide shows typical chorion-epitheliomatous tissue.

These large polyhedro-columnar cells are certainly not Langhans' cells, though one sees all stages in their conversion into Langhans' cells. I think with Risel that we see in these cases the differentiation of primitive teratomal ectoderm in alveolar or tubular arrangement into chorio-epithelial tissue.

(B) *The previously recorded cases.*

These may be grouped under three heads according as the primary growth was in (I) the testicle, (II) the ovary, or (III) other situations.

(I) *Cases primary in the testicle.*

In the following group of cases structures closely resembling the vesicular mole were found in connection with a testicular tumour.

(1) Waldeyer (10), under the name of "Myxoma intravasculare," described a tumour of the testicle containing cystic spaces with islands of myxomatous tissue and cartilage from which outgrowths invaded the spermatic veins. These outgrowths were "only comparable with the villi of a vesicular mole."

(2) Kanthack and Pigg (11) described an almost similar case with metastases in the prevertebral glands, liver, inferior vena cava, and right auricle. From the tricuspid valve projected a branched mass resembling externally, as in Waldeyer's case, a vesicular mole.

(3) Macallum (12) described and illustrated a remarkable case in which the testicular tumour is described as myxomatous, hæmorrhagic, and partly necrotic. The inferior vena cava, right auricle, pulmonary vessels, jugular and subclavian veins, and some of the cerebral sinuses were filled with a growth macroscopically and microscopically "resembling nothing so much as a hydatidiform mole."

(4) Silberstein (13) recorded an almost similar case. The primary tumour was complex and suggested a teratoma. The pulmonary metastases from the description may be chorion-epithelioma, whilst in the right auricle was a hydatidiform mass.

(5) In 1902 Schlagenhaufer first stated that the occurrence of chorion-epitheliomatous and vesicular mole-like structures in the absence of pregnancy was to be explained by attributing their origin to elements of the trophic ectoderm of the chorion occurring in teratomata. He published two cases in support of his contention.

The first was a specimen originally described by Breus. The primary tumour in the testicle was an undoubted teratoma containing entire villi in a state of vesicular degeneration. In the lungs were secondary growths identical with chorion-epithelioma and embolic areas containing villus-like plugs. In the left auricle was a mass exactly resembling a vesicular mole.

The second case was somewhat different, the metastases in the lungs presenting a chorion-epitheliomatous structure only. The primary tumour in the testicle was a teratoma containing elements derived from all the three layers of a trilaminar blastocyst (Fig. 15.)

(6) Steinhaus (14) has recorded a case identical with Schlagenhaufer's second case.

(7) In 1896 Kanthack and Eden (15) showed a specimen identical in structure with "deciduoma malignum," but derived from the testicle.

(8) Wlassau (16) investigated the "sarcome angioplastique" of certain French authors (17, 18, 19.) He pointed out that all the described cases had originated in the testicle and added four cases of his own. He noted the resemblances to chorion-epithelioma, but considered that the malignant cells originated from the imperfectly differentiated epithelium of the embryonic gland-tubes. The stromal portions of the testicular growth, however, he recognised as arising from an embryonic inclusion.

(9) Steinert (20) investigated a rapidly growing tumour of the testicle (Schmorl's case). Secondary growths were present in the retro-peritoneal lymph-glands and formed a mass the size of a head. Smaller metastases were present in the liver. The primary tumour was a typical teratoma, representatives of all the three primitive layers being present. *In one small part of*

the mass was found an area of typical chorion-epitheliomatous structure. The metastases in the retro-peritoneal tissue were also teratomatous. In addition, certain large spaces lined by a cylindrical epithelium were present which showed marked proliferation of a carcinomatous type. In other parts typical Langhans' cells and broken-up syncytia were found.

FIG. 15.

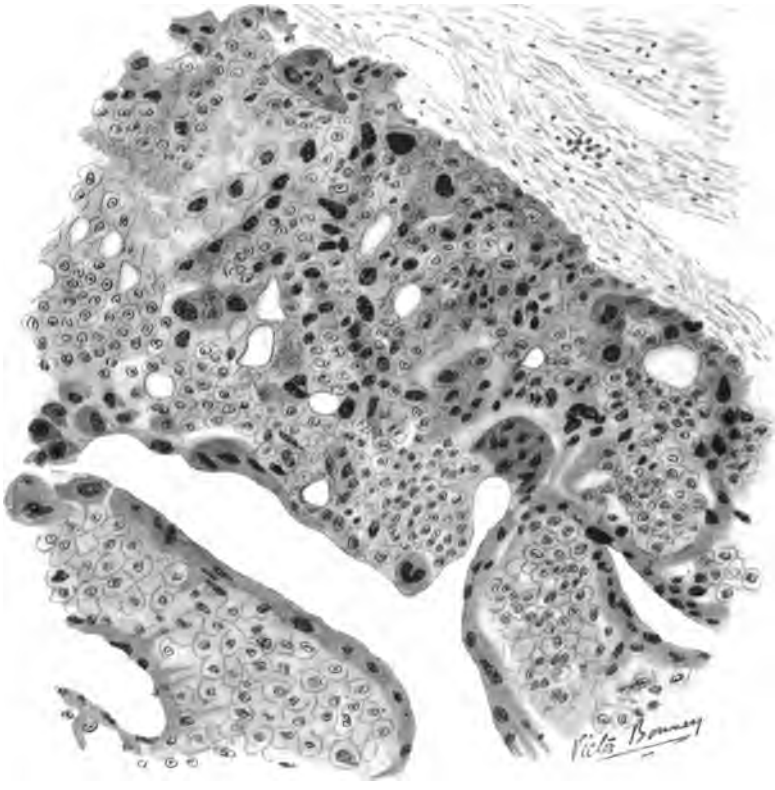

Schlagenhaufer's second case. A portion of the testicular growth, showing large Langhans' cells, syncytial masses, and large mononuclear cells. Drawn from a slide with the kind permission of Professor Schlagenhaufer. (Obj. 1 inch. Ocular No. 8 Zeiss. Camera lucida.)

In the liver the growth consisted of syncytial masses and of the large irregular cells derived from syncytial disintegration.

(10) Emanuel's case (21) is of the same character as that of Steinert. The tumour situated in the testicle caused death in three months with metastases in the right lung, liver, retro-

peritoneal glands, and pancreas, which macroscopically resembled chorion-epithelioma. The retroperitoneal mass was of great size. Microscopically, *both in the primary and secondary tumours* he found a tissue consisting in parts of tubular spaces lined by epithelial cells resembling carcinoma and in parts of typical chorion-epithelioma, whilst besides these were found simple cysts lined by a cylindrical epithelium. He considered the case to be

FIG. 16.

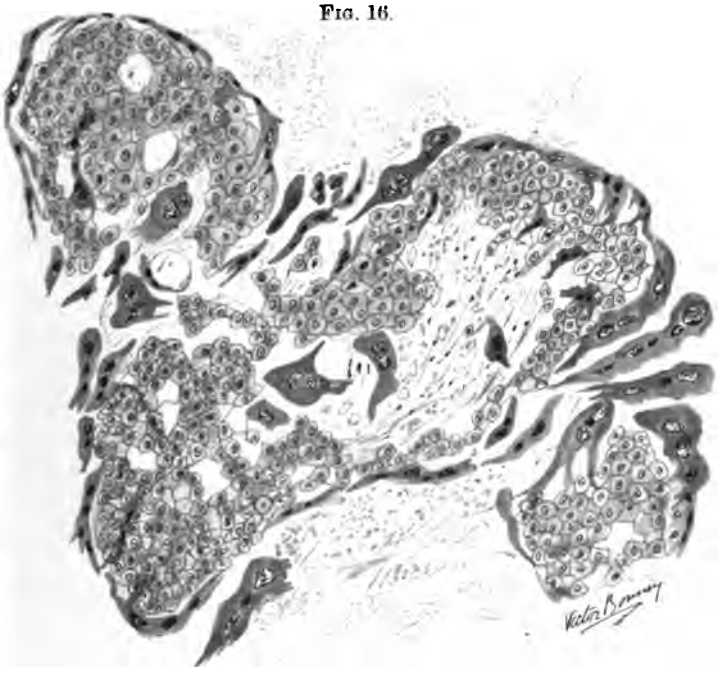

v. Hansemann's case. A portion of the testicular tumour, showing Langhans' cells, syncytia, and blood-extravasations in typical arrangement. With acknowledgments to Professor v. Hansemann. (Obj. 1 inch. Ocular No. 8 Zeiss. Camera lucida.)

one of simultaneous carcinomatous and chorion-epitheliomatous degeneration of a teratoma, and believed both types of growth to have been derived from embryonic ectoderm.

(11) v. Hansemann (22) has reported a somewhat similar case. The testicular growth and the metastases in the liver, spleen, and the bulk of the retro-peritoneal glands showed a chorion-epitheliomatous structure only. In some of the lower glandular metastases, however, spaces lined by cubical or cylindrical epithelium were found. The tumour was held to be of

teratomatous origin on account of the cystic spaces found in the metastases (Fig. 16).

(12) Dillmann (23) has published a case of particular interest. The patient died of a very large retro-peritoneal tumour of a bluish-red colour with other smaller masses in the lung. All these growths showed a typical chorion-epitheliomatous structure. The left testicle was normal in size. Near the hilus was a whitish mass the size of a cherry composed of connective tissues containing cystic spaces, the epithelium of which appeared to be proliferating to form masses of Langhans' cells, having a carcinomatous arrangement.

(13) Risel (24) has investigated two specimens. In the first the primary tumour presented, not only chorion-epitheliomatous tissue, *but also appearances suggestive of a proliferation of neuro-epithelial structures.* He regarded the specimen as arising from embryonic ectoderm.

In his second case the testicle had been previously removed and was not available for examination. *Post mortem* the metastasis in the retro-peritoneal tissue, inferior vena cava, fourth lumbar vertebra, lungs, and liver exhibited a typical chorion-epitheliomatous structure. In addition portions of the retro-peritoneal mass showed duct-like spaces, lined by small cubical cells which Risel suggested were derived from the epithelium of the seminiferous tubules or from epithelial tissues present in the primary tumour.

Askanazy (25) has interpreted cases such as Risel records in another manner. He has himself investigated a primary chorion-epitheliomatous tumour of the testicle and asserts that the Langhans' cells or their prototypes in the teratoma may at times assume an atypical arrangement of a tubular or alveolar character.

(15) Scott and Longcope (26) have described a specimen in an undescended testicle; it contained no teratomatous tissue, but only cells of the Langhans type. The metastases were typical.

(16) Frank (27) has described two specimens. In the first the general arrangement was alveolar with papillary projections resembling villi; no teratomatous structures were present. The second case was held to be a teratoma containing chorion-epitheliomatous tissue. The subsequent history of these two cases, both of which were operated on, is unknown.

(II) *Cases primary in the ovary.*

In this group are considered seven cases reported by L. Pick and three cases reported by Michel, by Schmaus, and by Kleinhaus.

(1) Pick's cases (5–9). The earliest published case was that of a woman from whom the right adnexa were removed for tubal gestation. The ovary contained a "dermoid" cyst with hair, teeth and bone (teratoma), but towards the uterine pole was another smaller cyst, containing clear fluid in which was found a mass resembling both macroscopically and microscopically a vesicular mole. Although the possibility that this represented a metastasis from the tubal gestation could not be excluded, Pick considered that the balance of probability favoured the view that it was a primary development from an ovarian teratoma.

His second case was that of a girl aged 9 years. Microscopically the growth contained teratomatous structures from which were proliferating a typical chorion-epitheliomatous growth, together with tissue of a neuro-epithelial character. He subsequently investigated five similar cases.

(2) Michel's case (28) was an undoubted virgin aged 16 years. A dark red tumour was removed from the left ovary, together with a pedunculated metastasis from the back of the left broad ligament. The patient died later, with a large recurrence in the lower abdomen and numerous smaller masses in the kidneys and liver. These presented to the naked eye the appearances of a chorion-epithelioma. Microscopically in the paler parts of the large mass were groups of hyaline polyhedral cells surrounded by a spindle-celled stroma. In the hæmorrhagic areas large syncytia were seen together with many large mononuclear cells. The general arrangement of the hyaline cell masses was carcinomatous, but they showed the festoon-like appearance of the Langhans' cell masses in chorion-epithelioma. The growths in the liver and kidneys presented only the syncytia and the large mononuclear cells.

Michel regarded the case as one of carcinoma of the ovary of a chorion-epitheliomatous type, but Pick subsequently criticised this conclusion and declared the case a chorion-epithelioma arising in a teratoma ('Cent. für Gyn.,' 1905, Nos. 18–26).

(3) Schmaus (29) has reported a case which he describes as an

adenocarcinoma of the ovary with chorion-epitheliomatous metastases in the peritoneum. A perusal of the description leaves one unconvinced as to the exact character of the secondary growths. Pick, however, believes this case also to be a chorion-epithelioma.

(4) Kleinhans's case (30) was that of a woman who was operated on for supposed tubal pregnancy. The tube was normal, but there was a hæmorrhagic tumour of the left ovary, which was chorion-epitheliomatous in structure.

The patient subsequently died and *post mortem* were found chorion-epitheliomatous metastases in the lungs and vagina. Kleinhans, who published the case at a period antecedent to Schlagenhaufer's paper, considered that the growth arose from an ovarian gestation. The case must be considered doubtful.

(III) *Tumours primary in situations other than the testicle and ovary.*

(1) Bock's case (31) was that of a girl aged 12 years, almost certainly a virgin, who at her fourth monthly period passed *per vaginam* a typical vesicular mole.

(2) In Lubarsch's case (32) a large uterine tumour of typical chorion-epitheliomatous appearance and structure was removed from the uterus of a virgin aged 12 years.

(3) Boström's case (33). In this case a small intra-cranial tumour having a typical chorion-epitheliomatous structure was removed from a man aged 30 years. The patient died shortly afterwards and a large retro-peritoneal tumour was found, with smaller growths in the lungs, liver, and kidneys, all of which, both to the naked eye and under the microscope, were identical with a chorion-epithelioma. The testes were normal.

(4) Djewitzki (34) has recorded the case of a virgin, aged 75 years, in whom was found a chorion-epitheliomatous growth of the posterior surface of the bladder, with secondary growths in the lungs, bronchial glands, spleen, and sigmoid flexure. No teratomatous structures were found.

(5) Ritchie (35) reported the case of a man in whom a large tumour occupying the anterior mediastinum was found, which consisted of (*a*) an area presenting the typical structure of a teratoma containing skin, sebaceous material, hair, etc., and (*b*) a solid portion macroscopically and microscopically identical with

a chorion-epithelioma. In the lungs were many nodules typically chorion-epitheliomatous (Fig. 17).

(6) Frank (27) lately reported a case in which *post mortem*

FIG. 17.

Ritchie's case.—A portion of the tumour, showing large Langhans' cells and syncytia invading the substance of the teratoma; above is seen a space lined by stratified epithelium. Masses of blood are scattered through the field. Drawn from a slide with the kind permission of Dr. Ritchie. (Obj. 1 inch. Ocular No. 8 Zeiss. Camera lucida.)

a mediastinal tumour was found in a young man, together with metastases in the lungs and liver, all presenting a typical chorion-

epitheliomatous appearance and structure. No evidence of a teratoma was found, but the case, unfortunately, could not be thoroughly investigated.

(7) Marx (36) has reported a tumour of the liver which microscopically resembled a chorion-epithelioma.

A study of the foregoing cases, therefore, reveals a remarkable histological identity between the class of tumours under discussion and the chorion-epitheliomata, vesicular moles, and mixed tumours (choriomata) occurring in connection with pregnancy. We see also in these tumours the same tendency to depart from the typical cell characteristics which we have already remarked in the chorion-epitheliomata. In short, the typical and atypical forms of chorion-epithelioma described by Marchand are reproduced in these cases.

The chorion-epitheliomatous nature of these tumours of the testes, ovary, and certain other situations is, however, not accepted by all observers. The views of Wlassau, of Michel, and of Schmaus have already been indicated when describing their cases. Foulerton (37) believes that appearances such as those described by Schlagenhaufer may be present in what he regards as undoubted columnar-cell carcinoma of the testes. Finally Sternberg (38) has combated Schlagenhaufer's views, and whilst considering a case of his own as a perithelioma, holds that many tumours, both carcinomatous and sarcomatous, may at times take on a syncytial form.*

On the Ontogenetic Identity of certain Tumours originating apart from Pregnancy and recognised Chorion-epitheliomata.

The absolute identity of the tumours under discussion with the chorion-epitheliomata, choriomata, and vesicular moles cannot be proved on their histological resemblance alone. Such evidence, however, is greatly strengthened if it can be shown that it is reasonable to suppose that they arise from cells ontogenetically identical with the elements of a trophoblast or chorion.

* Since the above was written Professor M. Askanazy, of Geneva, has very kindly sent me slides from a case of chorion-epithelioma primary in the pineal gland of a man. The microscopical appearances are typical. The literary bearing on this remarkable case is to be found in 'Verhandlungen der Deutschen Pathologischen Gesellschaft zu Stuttgart.'

There is no doubt that the majority of chorion-epitheliomatous tumours originating in the absence of pregnancy have arisen *in connection with teratomata.* It will be necessary, then, to discuss briefly the possible modes of origin of teratomata.

At the outset I would set aside those forms of growth which apparently originate from unequal dichotomy of the fœtal axis. They have no characteristics in common with the class of teratomata under discussion. The parasite is an absolute continuity with the autosite, and never develops after birth, in these respects presenting a complete contrast to the tumours under discussion, namely the endogenous teratomata, which are invariably encapsuled and develop at long periods after birth.

As regards the theoretical origin of these endogenous teratomata, I cannot accept the view that attributes them to the inclusion of one fertilised ovum within another; for I think that, having regard to the embryology of the early human ovum, the possibility of such an occurrence seems extremely problematical. From the same standpoint the inclusion of a fertilised polar body within the developing ovum is equally unlikely. Moreover, both these theories consort ill with the known fact that these endogenous teratomata almost invariably develop at periods long subsequent to birth, nor do they explain the marked preference shown by them for the genital glands.

The ingenious theory of "epigenesis" propounded by Mr. Shattock (40) is open to the former objection.

The so-called "cœlom parasite" has been attributed to the inclusion of one uniovular twin within its fellow. Apart from the embryological difficulties, this view appears to me to be negatived by the fact already referred to that these tumours usually develop rapidly in later life. The interesting experiments carried out by Nichols (41) on the rabbit may be here referred to. He implanted a very early fœtus about $\frac{1}{2}$ cm. long, with the yolk-sac adherent but without the placenta, into the subcutaneous tissue of the mother. As a result a tumour *immediately* formed, which at the end of ninety days was ten times the size of the implanted mass, and which presented the structure and arrangement of the more complicated forms of teratomata. Further, this theory negatives the presence in these tumours of chorio-epithelial tissue; but in the remarkable case of Maydl quoted by Teacher an abdominal teratoma in a male contained a mass presenting the

histological structure of placenta. (See also Zagari, 'Reforma Medica,' 1903, No. 19, quoted in Gould's 'Year-book of Surgery,' 1905, p. 116.)

Finally, the histology and behaviour of these mediastinal and retro-peritoneal tumours are identical with those endogenous teratomata occurring in situations where the theory of fœtal inclusion cannot be applied. I am therefore led to the belief that all endogenous teratomata are derived from cell-seclusions formed in embryonic life, and that they may originate in this way from two sources—

(A) That they arise from abnormal embryonic cell-seclusions formed at various periods during the development of the ovum.

(B) That they arise from the cells specialised in early embryonic life to form the germinal epithelium.

(A) *Origin from abnormal embryonic cell-seclusions.*

It is probable that certain teratomata arise from abnormal cell-seclusions formed during embryonic life. Such a seclusion may represent:

(1) An undifferentiated blastomere.

(2) An element of one of the layers of the blastocyst.

(3) An element of the specialised derivatives of one of the layers of the blastocyst.

(1) *Blastomeric seclusions.*—Owing to its wide potentialities, the undifferentiated blastomere or any cell equivalent to it may be regarded as capable of producing all varieties of tissue, including the trophic ectoderm. For even those teratomata composed of elements derived from only two or one layer of the differentiated blastocyst may be explained on the assumption that the sequestered blastomere or equivalent of a blastomere (*a*) does not necessarily produce all three layers when it eventually develops, or (*b*) that it may produce elements of one layer in such excess as to obscure the others.

As regards the first possibility (*a*), one must remember that the earliest differentiation of the blastomere is into ectoderm and entoderm, mesoderm making its appearance much later. It would not, then, be unlikely that under abnormal conditions of growth only the first two elements should be produced—that is, that the tumour should contain epithelial structures only.

As regards the last possibility (B) Pick (6) has pointed out that the ovarian tumours first described by him as struma ovarii could be proved by serial sections to be teratomata in which thyroid tissue had developed to such a degree as almost to conceal the other elements, and an interesting confirmation of this observation is to be found in the 'Transactions of the Obstetrical Society of London,' 1905, pp. 242 and 247, dealing with similar tumours studied by Herbert Williamson and Hamilton Bell.

(2) *Seclusions representing elements of one of the layers of the blastocyst.*—It is possible that certain teratomata originate from cell-seclusions representing elements of one of the layers of the bilaminar or trilaminar blastocyst. Thus an ectodermic seclusion developing at a later date might theoretically form trophoblast tissue, squamous and columnar epithelium, and nerve elements. The direct association of chorio-epithelial and neuro-epithelial tissue in a teratoma has been described by Pick and by Risel, whilst the continuity frequently observed between the former and various other types of epithelium has been already referred to.

(3) *Seclusions from specialised derivatives of the blastocyst.*—Seclusion may take place after the differentiation of the primitive layers into their permanent derivatives (*e. g.* facial dermoids), the tumours formed as a result of such seclusions presenting a simpler type than the foregoing. Since embryological continuity can be traced between the trophoblast of the chorion and the fœtal ectoderm the possibility of a direct seclusion of trophoblast cells in the body of the fœtus cannot be denied, though its probability is slight. Thus it is evident that a chorion-epithelioma may theoretically not only arise as part of a seclusional tumour, but might actually constitute the entire seclusional tumour itself.

(B) *Origin from the cells derived from the germinal epithelium.*

The theory of the origin of teratomata from embryonic cell-seclusions does not at first sight satisfactorily explain the marked preference shown by these tumours for the genital glands. A consideration, however, of the origin, development, and potentialities of the sexual cells leads one to believe that the

teratomata occurring in these organs are also to be regarded as of seclusional origin.

The germinal epithelium is descended from cells separated off as early as the morula stage of the segmentation of the ovum (Arthur Robinson); that is to say, the cells composing it are the direct descendants of the blastomeres of the morula, and have no connection with any of the layers of the blastocyst.

Having regard to the extraordinary variety of tumours which the ovarian parenchyma is capable of producing, and the presence in them of types of epithelium which have no ectodermic or entodermic prototype in the normal organ, and bearing in mind the remarkable power of mutability shown by the cells of the stratum granulosum and the evolution of the fœtus from the cytoplasm of the ovum there is the strongest reason to believe that in the female the cells of the germinal epithelium and their derivatives have maintained intact those primitive potentialities to which their unbroken descent from the blastomere would entitle them, and I would regard them, therefore, as *normal seclusions* of elements of the undifferentiated blastocyst.

In the testicle we again meet with a variety of tumours, many of which in their multiform character are only comparable to the ovarian growths. In this organ, however, their origin is more obscure because in addition to the cells of the spermatogenetic tubules which are derived from the germinal epithelium we have those lining the tubules of the vasa recta and rete testis, whose derivation is usually held to be from the nephridial tubes of the intermediate cell mass (Arthur Robinson). The relation borne by the testicular teratomata to the two types of cell is difficult to make out because when encapsuled the testicular substance proper and mediastinum testis are flattened out on the periphery of the tumour, whilst when non-encapsuled and malignant the relations of the parts are lost.

Further, the relation of the cells of the nephridial tubules to the ectoderm is not at present apparent in the higher mammals. It is possible that the cells of the intermediate cell-mass usually reckoned as mesodermic are really of a more primitive nature. At all events, we have the apparent anomaly of an epithelium originating in a tissue neither ectodermic nor entodermic. For this reason anomalous types of growth might well be expected from them.

Taking all these facts into consideration, I am of opinion that the parenchyma cells of the testis proper and possibly those of the mediastinum testis also should be considered as normal seclusions of elements of the undifferentiated blastocyst.

Thus I would regard the specialised sex cells, both male and female, as potential blastomeres and the ovary and testis as areas of normal embryonic cell seclusion.

This view explains the frequency with which teratomata affect the genital glands.

In the more complex forms of teratomata, which occur most commonly in the ovary and testis, a great variety of epithelial types are present. Some of these are histologically identical with those normally met with in other parts of the body, whilst others are quite anomalous. I believe, with certain continental observers, that we see in these tumours ectodermal and entodermal elements in course of differentiation. It is from the former, such as we see in Spilsbury's case, in my third case, and in the slides Dr. Pick has kindly sent me, that trophoblastic proliferations may take place, and I am of opinion that scattered areas of this tissue are really not uncommon in these tumours if sufficient search be made for them.

The proportion of the tumour which this variety of ectodermal proliferation may form will vary, for it seems evident that when a teratoma becomes malignant it may do so in virtue of any one or all of the elements which it contains. Thus in two cases lately published by Targett and Hicks (39) the multiform structures characterising the primary growths were faithfully reproduced in all the metastases, whilst in the case reported by Dr. Ritchie, which I have cited to-night, the trophic ectoderm which the tumour contained was alone responsible for its malignant nature.

The occurrence in such tumours of actual villi, hydatidiform or otherwise, whilst very unlikely, is certainly not impossible.

In conclusion, I believe that the teratomata may originate—(*a*) from the development of an abnormal embryonic seclusion, (*b*) from the abnormal development of a normal embryonic seclusion, namely the sex cell.[1]

[1] Professor Arthur Robinson has shown me slides of the rat's ovary exhibiting asexual division of the ovum in the follicle. He tells me it is not an uncommon occurrence in this animal.

In theory a teratoma derived from either of these sources may contain elements of a trophic ectoderm; and this, when conjoined with the remarkable evidence of histological identity between the cases I have cited and the recognised chorion-epitheliomata, constitutes the strongest reason for believing that these tumours are chorion-epitheliomata of congenital origin.

Note.—I have to express my thanks to Dr. Edward Schenk, who has most kindly investigated the literature for me, and I am also indebted to Professors Schlagenhaufer, Ritchie, v. Hansemann, Askanazy, and Arthur Robinson, and to Messrs. John Teacher, L. Pick, Risel, Hicks, Bernstein, Lawrence, Spilsbury, and Stevens for their kindness in replying to my communications and (in many cases) for sending me microscopical preparations. I have also to acknowledge much help and useful criticism from Dr. Lazarus Barlow.

References.

1. *J. Teacher.*—'Brit. Journ. of Obstet. and Gynæc.,' vol. iv, Nos. 1 and 2, 1903.
2. *Marchand.*—*Ibid.*, vol. iv, No. 1.
3. *Berkeley and Bonney.*—'Arch. Midd. Hosp.,' vol. iv, 1905.; 'Brit. Journ. of Obstet. and Gyn.,' February, 1905.
4. *Schlagenhaufer.*—"Über das Vorkommen chorionepitheliom und trauben molenartiger Wucherungen in Teratomen," 'Wien. klin. Woch.,' May, 1902, Nos. 22 and 23.
5. *Pick.*—"Das Epithelioma chorioectodermale," 'Berl. klin. Woch.,' 1904, Nos. 7 and 8.
6. *Pick.*—"Beiträg zur Lehre von den Geschwülsten," "Struma thyroidea ovarii teratomatosa," 'Berl. klin. Woch.,' 1902, Nos. 19 and 26; 'Bull. de la Soc. Belge de Gyn. et d'Obstet.,' 1899—1900, p. 113.
7. *Pick.*—"Zur Kenntnis der Teratome: Blasenmolenartige Wucherungen in einer 'Dermoidcyste' des Eierstocks," 'Berl. klin. Woch.,' 1902, No. 51.
8. *Pick.*—"Zur Lehre von Epithelioma chorioektodermale," 'Zentralbl. f. Gyn.,' 1905, No. 18, und "Noch einmal zur Entstehung des Chorioepithelioms und Epithelioma chorioektodermale aus kongenitaler Anlage," 'Zentralbl. f. Gyn.,' 1905, No. 26.
9. *Pick.*—*Loc. cit.*, und "Zur Histiogenese des Chorioepithelioms," 'Zentralbl. f. Gynäk.,' 1903, No. 37, p. 1110; "Zur Frage der Entstehung des Chorioepithelioms aus angeborener Anlage," 'Virch. Arch.,' 1905, vol. clxxx, p. 172.
10. *Waldeyer.* — "Myxoma intravasculare arborescens funiculi spermatici, zugleich ein Beitrag zur Kenntnis des Cylindroms," 'Virch. Arch.,' 1868, vol. xliv, p. 83.
11. *Kanthack and Pigg.*—"Carcinoma of the Testis, with Metastatic Deposits lying free in the Heart and in the Infer. Cava," 'Journ. of Pathol. and Bact.,' 1898, p. 98.

12. *MacCullum.*—" On the Intravascular Growth of Certain Endotheliomata," 'Rep. of the Johns Hopkins Hosp.,' vol. ix, p. 497.
13. *Silberstein.*—" Ein Fall von Metastasenbildung in einem Thrombus der Vena cava int. bei primarem Adeno-Carcinoma myxomatodes des Hoden," 'Virch. Arch.,' 1899, vol. clvii, p. 183.
14. *Steinhaus.*—" Über chorionepitheliomartige Wucherungen beim Manne," 'Wien. med. Woch.,' 1903, No. 17.
15. *Kanthack and Eden.*—' Committee of the Obstet. Soc. of Lond.,' 1896.
16. *Wlassau.*—" Über die Patho-und Histogenese der sogenannten 'Sarcome angio-plastique,'" 'Virch. Arch.,' vol. clxix, p. 220.
17. *Malassez et Monod.*—" Des Tumeurs à myeloplaxes," 'Arch. d. Physiol.,' 1878.
18. *Carnot et Marie.*—" Sarcome angioplastique,' 'Soc. Anat.,' 1898.
19. *Dopter.*—" Sarc. angioplastique," 'Arch. de Méd. Exper.,' 1900.
20. *Seinert.*—" Über die embryoiden Geschwülste der Keimdrüsen und über das Vorkommen chorionepitheliomartiger Bildungen in diesen Tumoren,' 'Virch. Arch.,' vol. clxxiv, p. 232.
21. *Emanuel.*—' Ges. f. Geburtsh. u. Gyn.,' Bd. ii, xii, 1903; Ref. 'Zentralbl. f. Gyn.,' 1904, No. 5, u. 'Über chorionepitheliomartige Wucherungen in Hodenteratomen,' 'Monatschr. f. Geburtsh. u. Gyn.,' Bd. xxi, H. 3–6.
22. *von Hansemann.*—' Ges. f. Geburtsh. u. Gyn.,' Bd. ii, xii, 1903; Ref. 'Ztrlbl. f. Gyn.,' 1904, No. 5, p. 144.
23. *Dillmann.*—" Über einen Fall von Chorionepitheliom beim Manne," 'Zeit. f. Krebsforschung,' vol. iii, H. 1.
24. *Risel.*—" Über das maligne Chorionepitheliom und die analogen Wucherungen in Hodenteratomen," 'Arb. aus d. Pathol. Instit.,' Leipzig, 1903, Heft 1.
25. *Askanazy.*—' Zur Kenntnis der chorionepitheliomatösen Wucherungen in den Teratomen der Keimdrüsen,' 1-D., Leipzig, 1904.
26. *Scott and Longcope.*—" The Report of a Case of Malignant Tumour of the Testicle, resembling Chorion-epithelioma, with Metastases," 'Bull. of the Ayer Clin. Lab., Pennsylv. Hosp.,' 1905, Jan., No. 2.
27. *Frank.*—" Chorionepitheliomatous Proliferations in Teratomata, especially in those of the Testicle, with Three New Cases," 'Journ. of Amer. Med. Assoc.,' 1906, Nos. 4 and 5.
28. *Michel.*—" Ein Karzinom des Eierstockes mit chorionepitheliomartigen. Bildungen," 'Zentralbl. f. Gyn.,' 1905, No. 14.
29. *Schmaus.*—" Über einen Ovarialtumour mit chorionepitheliomartigen Metastasen im Peritoneum," 'Hegar's Beitr.'
30. *Kleinhans.*—Ref. 'Zentralbl. f. Gyn.,' 1892, No. 42, p. 1148.
31. *Bock.*—" Môle hydatiforme chez une enfant de 12½ ans."
32. *Lubarsch.*—" Zur Metaplasie-Frage," 'Arb. ans der Patholog.-Anat. Abteil. d. Kgl. Hyg. Instit. zu Posen,' 1901, p. 230.
33. *Boströem.*—' Verhandl. d. Deutsch. Patholog. Gesellsch.,' 1902, vol. v, p. 212.
34. *Djewitski.*—" Über einen Fall von Chorionepithelioma der Harnblase," 'Virch. Arch.,' vol. clxxviii, p. 451.
35. *Ritchie.*—" A Case of Embryoma occurring in the Mediastinum," 'Journ. of Obstet. and Gyn. of Brit. Emp.,' 1903, vol. iv, No. 1.
36. *Marx.*—" Über einen eigenartigen primaren Tumor der Leber nebst Bemerkungen zur Chorionepitheliomfrage," 'Ziegl. Beitr.,' vol. xxxvi, 1904, p. 585.

37. *Foulerton, A. G. R.*—"Carcinoma of the Testicle," 'Lancet,' Dec. 23rd, 1905.
38. *Sternberg.*—"Ein peritheliales Sarkom (Hæmatangioendotheliom des Hodens mit 'Chorionepitheliomartigen Bildungen,'" 'Zeitschr. f. Heilkunde,' April, 1905, vol. xxvi, No. 4, p. 105.
39. *Targett and Hicks.*—"Two Cases of Malignant Embryoma of the Ovary," 'Trans. Obstet. Soc., Lond.,' 1905.
40. *Shattock.*—'Brit. Med. Journ.,' November, 1904.
41. *Nichols.*—'Caroline Brewer Croft Cancer Commission,' 3rd Report, 1905, p. 120.
42. *Spilsbury.*—'Path. Soc. Trans.,' London, 1906.
43. *Hicks.*—*Ibid.*

---

4. *The nature of Jensen's mouse tumour.*

By W. Roger Williams.

No doubt everyone here is well aware of the fact, that the mountain of imperial cancer research in labour has brought forth a mouse; and this mouse has a tumour, which is "Jensen's tumour," with regard to which I now propose to submit a few critical remarks.

At the outset it may be mentioned that it was Morau, in 1891, who first specially directed attention to this so-called cancer of white mice, and subjected the malady to experimental tests. Jensen did little more than repeat, extend, and popularise Morau's experiments, which in the intervening decennium had been forgotten; and those who have subsequently concerned themselves with this matter, have done nothing more than say ditto to Jensen, without otherwise adding to our knowledge of the malady.

In comparatively recent times, several experimenters allege that they have succeeded in transmitting "cancer" from mouse to mouse. What is the real nature of this so-called cancer?

The great mistake of those who have so prematurely identified "Jensen's tumour" with cancer is that, in making their diagnosis, they have placed far too much reliance on histological appearances—the fallaciousness of which has so often been demonstrated in recent times—and far too little on the *ensemble* of the indications available for diagnostic purposes.

It is not so long ago since experimental pathologists, relying solely on histological appearances, were misled into regarding coccidial disease of the rabbit's liver as the prototype of cancer; and it is not a little disconcerting to find them again lapsing into the same kind of error, so soon after the explosion of this coccidial fallacy.

The history of recent experimental cancer research teems with analogous instances, which compel in the impartial observer a certain scepticism as to the diagnostic capability of these pathologists.

To mention only a few instances, it will be within the recollection of almost every one here, that the contagious venereal malady of dogs has been described by various independent authors, who have submitted it to careful microscopical examination, as being epithelioma, carcinoma, sarcoma, lymphosarcoma, endothelioma, lymphoma, molluscoid, papilloma, and granuloma. The histological accounts of different authors as to the minute structure of "Jensen's tumour" teem with similar incongruities. In like manner Sanfelice, relying too exclusively on this kind of indication, recently claimed to have produced true epithelial cancer in various animals, by inoculating them with cultures of certain blastomyceles; while Plimmer, Gaylord, and quite a host of other experimenters, have made the same little jump at the same little nothing.

These gentlemen seem to forget that the preceding generation of pathologists clearly established the fact, that wherever epithelial cells, capable of proliferation, come into contact with proliferous granulation-tissue, they grow into and interpenetrate the latter, producing histological appearances which are *per se* often indistinguishable from cancer.

Waldeyer, from the histological standpoint, having proposed for cancer the very short-sighted definition of "atypical epithelial proliferation," was soon made conscious of the serious inadequacy of such a conception by the histological researches of Wyss, Friedländer, and Councilman, who showed that "atypical epithelial ingrowths" were common enough in many chronic hyperplastic processes affecting epithelial-covered surfaces. A good example of this is furnished by the so-called "erosions" of the portio vaginalis uteri, which commonly comprise epithelial structures exactly like cancer structures.

It was by following the before-mentioned line of fallacies that Weber, Smith and Washbourn, and others, formerly persuaded themselves and most pathologists, that the contagious venereal tumours of dogs were examples of inoculable cancer; and it may be within the recollection of some here, that specimens of this kind were actually exhibited to this Society, and generally accepted as examples of true cancer; indeed, it is only lately that this fallacy has been exploded.

Knowledge of the foregoing facts enables us to understand how *quasi*-malignant tumours, comprising proliferous epithelial elements, may be caused by various extrinsic agents—microbic, chemical, etc. Thus cases of "blastomycetic dermatitis" have been described, in which the gross and microscopical features of the lesions were very similar to those of cutaneous cancer (Gilchrist, Stokes, Owens, Hyde, etc.). In this category the "infective epithelioses" of Borrel may also be comprised; and here also, I have no doubt, "Jensen's tumour" will eventually find its acknowledged resting-place. There are good reasons for believing, that experimental cancer reseachers are still far from realising the true import of these significant revelations.

Such considerations alone should have sufficed to cause the investigation of a novel morbid condition like "Jensen's tumour" to be approached with the greatest caution: but the event has been far otherwise; for, the modern experimenter, being a law to himself, is only too often quite impervious to the plainest lessons of history—even to those that may be learned from his own speciality. This narrowness of outlook is the cause of the extraordinary concatenation of blunders, with which the history of the experimental study of cancer is cumbered; indeed, if we put aside the Munchausen creations, very little solid fact remains as the outcome of so much vapouring.

Now, what are the plain facts in respect to which "Jensen's tumour" differs *in toto* from cancer or any form of human malignant tumour? They are briefly these:

The disease is highly contagious; thus when infected animals are introduced into cages with healthy animals, the latter take the malady, as if by local contagion, and sometimes the proportion thus infected is so considerable as to constitute veritable epidemics (Klebs, Bosc, Loeb, Haaland, etc.). Nothing like this occurs with human cancer—at least, not outside the Munchausen

sphere; but, in the contagious venereal malady of dogs, analogous conditions are commonly met with. "Jensen's tumour" is readily transmissible by implantation to other mice, the proportion of successful experiments often being as high as 30 per cent. No such property is ever manifested by human cancer; but with the contagious venereal pseudoplasms of dogs similar conditions obtain.

A considerable proportion of white mice are immune to the contagion of this disease, whether in its spontaneous or experimentally-determined form; and sometimes whole families manifest this peculiarity. The same phenomena have often been noted in the contagious malady of dogs.

Moreover, "Jensen's tumour" fairly often undergoes spontaneous cure, and the cured animals are then immune to further contagion, and give only negative results when inoculated, as Gaylord has specially pointed out. With human malignant tumours, no such spontaneous curability has ever been scientifically demonstrated, but with the venereal pseudoplasms of dogs this phenomenon is of common occurrence.

"Jensen's tumour" is circumscribed and easily enucleable, the tissues of the host forming no part of it; moreover, the latter do not acquire cancerous properties, nor do they become interpenetrated by processes of the pseudoplasm; and, besides this, "Jensen's tumour" generally causes no cachexia.

Finally, according to Apolant and Ehrlich, "Jensen's tumour" in the course of experimental transmission often changes its anatomical type—from the epithelial to the sarcomatous, etc.; and Morau found, under similar circumstances, that its physiological type also changed, with corresponding alteration in its power of inoculability. In all of these vitally important respects, which, taken together, are crucial for diagnostic purposes, "Jensen's tumour"—whatever its real nature may turn out to be—is totally unlike any form of human cancer.

On the other hand, like the venereal malady of dogs, "Jensen's tumour" can usually only be successfully grafted into other animals of similar species.

Another feature in regard to which the two maladies present a certain resemblance is, that in both secondary disseminative lesions occasionally result, so that, in this respect, "Jensen's tumour" resembles certain artificially produced pseudoplasms—

such, for instance, as those Sanfelice and others caused by inoculating animals with pathogenic yeasts, etc.

Although in the foregoing remarks no reference has been made to the contagious pseudoplasm of rats, which is analogous to "Jensen's tumour" of mice, I may as well now state that the criticisms applied to one malady are equally valid for the other.

In conclusion, I have only to remark, that "Jensen's tumour" —regarded as cancer—is a mere bogey, the lineal descendant of such other bogeys as the contagious venereal tumour of dogs, coccidial disease of the rabbit's liver, etc., and I am inclined to believe, while the psychological prepossessions of experimental pathologists remain such as they now are, that—even when we have laid this Jensen bogey—some kindred phantom will soon arise to perpetuate this particular kind of prepossession. Recent experimental cancer research is a medley of "chaos, clouds, and tongues," in which there is neither light nor leading. Therefore, in dealing with matters of this sort, let us never forget Cousin's luminous dictum: "*La critique est la vie de la science.*"

November 6th, 1906.

5. *A contribution to the pathology of the sphincters in cranial and spinal injuries.*

By Edred M. Corner.

Any attempt to understand the manner in which the bladder and rectum perform their functions in certain injuries and diseases is a matter of very great difficulty. The various text-books upon medicine and surgery shed little or no light upon the subject, but rather add to the trouble, as conflicting statements are made, and terms with various meanings are used, without any explanation whatever being offered. With this confusion there was every incentive to undertake the work of striving to elucidate their mysteries. The observations were made, during my term of office as surgical registrar to St. Thomas' Hospital in 1900, on cases of concussion and compression of the brain, fractures of the skull, and injuries to the vertebral column.

After observing over one hundred examples clinically, the conclusion was reached that the frequency with which the sphincters were affected depended on the amount of violence which chanced to cause the injury. As figures indicating the frequency of such affections were mere matters of chance and, therefore, largely valueless, no further observations were included, there being sufficient evidence in hand to testify to the existence of the different pathological states which will be referred to. The figures themselves clearly show how the sphincters are affected by the variations in the amount of violence which caused the injuries; for instance, in concussion of the brain, affection of the spincters is infrequent; whilst in fractures of the skull, in which generally more violence is needful, they are more frequently affected.

The problem of the conditions of the sphincters is made worse by the confusion which exists as to the meaning of the word "incontinence." It is generally understood to mean the unconscious passage of excreta, no matter how, whether by a reflex act or otherwise. As the normal and conscious passage of excreta is a reflex act, sanctioned by the higher centres, it would seem better to restrict the name "incontinence" to the abnormal—*i. e.* to the passage of excreta other than by a reflex act, whether consciously or unconsciously; and in this definite and restricted sense the word "incontinence" is used throughout this paper. The words "micturition" and "defæcation" are used in the opposite sense, namely to denote reflex acts, whether conscious or unconscious. The various methods of voiding urine are, therefore, by conscious micturition, by unconscious micturition—*i. e.* by an unconscious reflex—and by incontinence. There are precisely similar varieties of defæcation.

In this paper the effects which various lesions have upon the excretion or secretion of urine have not been considered in detail; and the results, as well as those of obstruction, such as stricture of the urethra or carcinoma of the rectum, have been carefully excluded. Unlike the bladder, the rectum may contain both solid and liquid excreta; but, as the solid or semi-solid motions are the natural contents, they alone are considered. The results of the presence of irritating fluids in the rectum will be obvious.

This communication is divided into four sections. The first deals

with the bladder and rectum in the paralytic and non-paralytic states; the second, with the effects of concussion, compression, and other head injuries on them; the third, with their conditions in fractures of the spine and concussion of the spinal cord; the fourth, with results of lesions of various nerves.

The two fundamental conditions under which the bladder and rectum work are the paralytic and non-paralytic states. Each of these conditions will be fully considered before proceeding to the different diseases and injuries. Both of these organs, the bladder and the rectum, may be regarded physiologically as consisting of a body with detrusor muscles, and of a neck with a sphincter muscle.

(I) The Non-paralytic State.

The possibilities will be considered with regard to the bladder first.

The bladder.—(1) If the bladder should contain urine at the time of injury, an act of unconscious micturition may take place, the bladder expelling its contents.

(2) If for any reason such an act does not occur, the bladder will become full and even lose its power of contracting to cause the passage of urine, such a condition being termed *retention of urine.*

(3) If this retention of urine is unrelieved, either by the patient passing urine or by means of a catheter, the bladder will continue to be filled from the ureters, until the pressure within it is sufficient to overcome both the mechanical and muscular—*i.e.* the physical and physiological or the passive and active—resistances of the urethra, and the urine will overflow.

Of this overflow two varieties exist: (*a*) The bladder ordinarily undergoes rhythmic contractions, which only disappear with very great distension of the viscus. These contractions will cause the passage of a few drops of urine every few minutes and, I think, can be recognised clinically. The condition is best termed *active overflow.* (*b*) If the bladder becomes still further distended, these rhythmic contractions cease, the muscular wall becoming paralysed. Where the urethra is canalised the overflow will consist of drops of urine which are mechanically displaced from the bladder by the influx from the ureters, which

can be recognised clinically by the presence of a more or less continuous dribbling. This state may be called *passive overflow.* In recognising it clinically, great care must be taken to eliminate the action of the diaphragm, which makes the flow appear more intermittent than it really is. Neither condition of overflow should be seen clinically, as the retention of urine should have been relieved, when needful, by a catheter. If by any mischance the passage of the catheter is delayed, first active overflow and later passive overflow will be seen. Naturally, the latter phenomenon is of very rare occurrence. It is by no means an easy matter to distinguish between these two methods of overflow.

The rectum.—The rectum differs from the bladder in several important points, of which the following may be cited: its normally solid contents; its tolerance of those contents, sometimes very great; its evacuation once a day as compared with the bladder's four, five, or more times. Observations on the rectum are not so easily made, as a purgative is usually administered, which masks the true condition. The conditions are very similar to those of the bladder.

(1) There may be an act of defæcation, unconscious defæcation.

(2) If the above fails to occur, there will be retention of fæces, most probably followed by their drying and by constipation.

As the rectum and sigmoid are capable of very great distention and the contents are solid, no such condition as overflow is observed.

The "retentions," both of urine and fæces, noted in this non-paralytic state may be called active retentions, as they are caused by the active—*i. e.* the muscular or physiological—resistances of the unparalysed anus and urethra.

The Paralytic State.

In this condition a somewhat similar process can be traced.

The bladder.—When the bladder is paralysed, it might be expected that the urine would trickle from the ureters through the empty bladder and out of the urethra, the musculature of the bladder and urethra being paralysed. Sir William Gowers has given the name of "simple incontinence" to this condition.[1] Such a state is, however, more ideal than real. The urethra is

[1] 'Text-book of Diseases of the Nervous System.'

not an open pipe, but its walls are in apposition; therefore the urine has to collect within the paralysed bladder until the intra-vesical pressure is sufficient to overcome the passive, physical, or mechanical resistance of the urethra. The amount of the obstruction varies considerably in different patients and is least in the short urethræ of women, in whom the ideal simple incontinence of Sir William Gowers is most nearly approached. In a man, there is superimposed the resistance of a longer urethra and of the prostate. The presence of an obstruction, such as a stricture of the urethra, will greatly increase the passive resistance to be overcome.

At first a certain degree of retention will be present, to be followed by a purely passive paralytic overflow, which differs from the non-paralytic passive overflow, as in the latter both the active and passive resistance of the urethra have to be overcome, whilst in the former the passive alone has to be contended with. Consequently, in the paralytic state the distension of the bladder required to cause overflow is much less than it is in the non-paralytic.

As the mechanism which causes the normal rhythmic contractions of the bladder has been assumed by physiologists to be purely local, they may even be present in the paralytic state and help the organ to overcome the resistance of the urethra. Whether such a condition exists I do not know. But, eliminating the action of the diaphragm, theoretically there may be an active followed by a passive overflow in the paralytic as in the non-paralytic state. On the other hand, it seems very doubtful if a paralysed bladder can be distended sufficiently to abolish its own contractions.

The rectum.—The rectum itself is not paralysed, as peristalsis is handed on from segment to segment of the bowel either by continuity of muscular tissue or by means of some local nervous mechanism. Therefore, in paralytic states it is merely necessary to consider the paralysis of the sphincter.

(1) Incontinence of fæces is to be expected on account of the paralysis of the sphincter.

(2) But owing to the solidity of the contents, the tolerance of the rectum and sigmoid, etc., the patient usually suffers from retained fæces and constipation—*i. e.* a purely passive retention. If by chance the contents are liquid, incontinence of fæces will

be present, not in the large gushes of a reflex act, but in driblets due to the peristalsis, an active overflow.

The persistence of muscular contraction in the rectum in spite of the general paralysis emphasises the point made above, viz. that similar contractions may be present in the bladder owing to its continuity with the ureters, so causing, not a passive but an active paralytic overflow.

Professor Sherrington ('Journal of Physiology,' vol. xiii, p. 578) pointed out that Mosso and Pellacani were the first to demonstrate the rhythmical contractions and relaxations of the bladder. He also showed that, in the monkey, cross-section of the spinal cord at the level of the twelfth dorsal nerve stopped the muscular contractions of the bladder for two minutes only. The problem of active overflow from the bladder in the paralytic state seems founded upon a fair experimental basis.

The "retentions," both of urine and fæces, in the paralytic state are due to the passive or mechanical resistance of the prostate and urethra which alone has to be overcome by the intra-vesical or intra-rectal pressures, and are therefore *passive retentions* in contradistinction to the *active retentions* of the non-paralytic state, in which both the active and passive resistances have to be overcome.

TABLE I.

(1) *Bladder.*

Non-paralytic state.

(1) A reflex act, unconscious micturition which will be followed by

(2) Active retention, and unless this is relieved there will be

(3) Active overflow, and still later

(4) Passive overflow.

The obstruction to the overflow consists of both the active and passive resistances of the urethra.

Paralytic state.

(1) Passive retention, which if unrelieved will be followed by

(2) Active overflow, and later perhaps and very doubtfully by

(3) Passive overflow.

The resistance to the overflow consists only of the passive urethral factor.

(2) *Rectum.*

Non-paralytic state.

(1) Unconscious defæcation, and most probably later
(2) Active retention of fæces and constipation.

Paralytic state.

(1) Perhaps incontinence of fæces, and later
(2) Passive retention of fæces and constipation.

The active or passive retentions are brought about by the non-paralytic or paralytic states of the sphincter ani.

These considerations have done much to simplify an understanding of the true conditions of the sphincters in injury or disease. The two conditions are very similar, with exception that in the non-paralytic state they are active and in the paralytic state they are passive.

(II) Concussion of the Brain.

Concussion is a condition in which the symptoms are most severe at the time of the receipt of the injury and thence progress favourably. The severity of the symptoms depends upon the degree of concussion. For instance, in mild cases there may be only slight symptoms of short duration; in severe cases they are more marked and prolonged. The examples from which the figures are taken are those in which the concussion was severe enough to demand admission to St. Thomas's Hospital. In arranging these in groups according to the condition of the sphincters, it is most convenient to start with those of the milder degree.

In far the greater number the sphincters were unaffected, fifty-four out of seventy cases—77 per cent.

Bladder.—(1) In the more severe cases of concussion the lumbar centre, in common with the other nervous centres, remained for some time dulled in its excitability, consequently requiring afferent impulses from the bladder which were stronger

than usual in order to excite a reflex act. As a result, the bladder fills up and a condition of active retention of urine is produced.

This retention must be carefully distinguished clinically from diminished secretion. For instance, a boy aged 11 years only secreted 6 oz. of urine during the first twenty-four hours after the accident. Polyuria occasionally follows head injuries and will accentuate the condition. Active retention of urine is the most common affection of the bladder in concussion of the brain, occurring in sixteen out of seventy cases—23 per cent.

(2) If the retention is unrelieved it may proceed to active and perhaps later to passive overflow of urine. As the number of cases of retention which are allowed to proceed to incontinence is not important, it is useless to attempt to give figures.

(3) The retention may remain complete, especially if there is some grosser obstruction in the prostate or urethra.

The pathological condition of the sphincter depends on the degree of the concussion and upon the time when the case is examined after the injury.

Rectum.—The rectum, as the bladder, is most frequently not affected, but in the more severe cases active retention of fæces, followed by constipation, will occur. The dull condition of the reflex lumbar centre is shown clinically by the difficulty experienced in getting the bowels to act.

The failure of a rectal or vesical reflex to take place may be due in part to the fact that in concussion, as in other head injuries, the impulse from the higher centres which ordinarily sanctions that reflex does not arrive, and the act is in consequence delayed.

TABLE II.

The results of this injury may be tabulated as follows and in order of their frequency:

(1) *Bladder.*

(1) Unconscious micturition.
(2) Active retention.
  (*a*) Active overflow.
  (*b*) Passive overflow.

(2) *Rectum.*

(1) Unconscious defæcation.

(2) Active retention and constipation.

FRACTURES OF THE SKULL.

Broadly speaking, fractures of the skull present in their general symptoms the signs of concussion, compression being excluded and the diagnosis of contusion or laceration of the brain being indefinite. Usually they are caused by more severe violence than is needed to produce concussion alone; consequently they show more severe signs and symptoms. Fractures of the skull do occur occasionally without any constitutional signs.

Only sixteen out of seventy cases of concussion (23 per cent.) showed any affection of the sphincters, whilst eight out of thirteen showed them in fractures of the base of the skull—61 per cent. Whether this was due or not to some slight degree of compression it is impossible to affirm or deny. Of the eight cases all had active retention of urine, four being allowed to proceed to overflow; whether of the active or passive variety is unimportant, as the latter is but a further degree to which the former may or may not be allowed to proceed. It is very interesting to note that out of three women with fractured bases two showed incontinence of urine, doubtless due to the very slight passive resistance of their short urethra, which required only a small increase of intra-vesical pressure to produce an overflow when the high centres are dulled in sensibility.

With regard to the rectum, active retention of fæces and constipation was the rule. One man had expulsion of fæces by means of a reflex act—*i. e.* unconscious defæcation.

Of fractures of the vault of the skull, nine in number, two patients showed no sign of concussion, two died of compression, and of one there is only a deficient record. Of the five remaining, two suffered from active retention of urine, going on to overflow. The only woman admitted also suffered from incontinence of urine. Of these cases, three out of five showed affection of the sphincters—60 per cent.

In those cases in which the rectum was affected active retention of fæces followed by constipation was the rule. The exception was a man, aged 45 years, who passed his fæces unconsciously, by a reflex act—unconscious defæcation.

Compression.

The symptoms of compression of the brain differ from those of concussion in that they get progressively more severe if allowed to take their course. Data concerning the sphincters are far more difficult to obtain, as the patients may die before a sufficient amount of urine or fæces has had time to collect, or operation may relieve the symptoms. The conditions will also depend upon the duration of the symptoms when observations are taken. In compression a paralytic state of affairs exists in the latter stages.

(1) In the early stages of compression, the preliminary concussion, urine may be voided by an unconscious reflex act, or even semi-consciously—*i. e.* the non-paralytic state.

(2) Possibly, and rather probably, *active* retention of urine will have occurred during the preliminary concussion, which in compression passes on to the *passive* retention of paralysis, some urine escaping as the bladder slowly passes from one condition to the other.

(3) When the symptoms of compression are marked, paralytic overflow takes place. I cannot say whether this is of an active or passive variety, but rather incline to the former. The bladder is always distended to some extent, and it is not the ideal "simple incontinence" of Sir William Gowers. The filling up of the bladder has caused Mr. H. P. Dean to state in his article in Treves' 'Surgery,' vol. ii, that in compression the bladder is distended and overflows. If the prostate and urethra are healthy, the distension is not nearly so great as that required to cause overflow in the non-paralytic state, as only the passive resistance of the urethra has to be overcome instead of both the active and passive resistances. In such cases passive retention, perhaps followed by active paralytic overflow, occurs.

With regard to the difference of sex, nothing can be said from actual observation; but it is to be expected that women will suffer more easily from overflow of urine, owing to their short, distensible urethra.

As the sphincter of the bladder, so the sphincter ani is paralysed. There is little or no passive resistance to be overcome, and should the consistence of the fæces allow it, incontinence will take place. But the preliminary concussion of

compression will have previously caused active retention, which will be followed by constipation. The fæces will then not allow the mere peristalsis of the rectum to evacuate them, and further retention and constipation must result—*i. e.* passive retention.

TABLE III.

(1) *Bladder.*

(1) Passive retention, followed by
(2) Active paralytic overflow, and very doubtfully by
(3) Passive paralytic overflow.

(2) *Rectum.*

(1) Incontinence of fæces.
(2) Passive retention of fæces and constipation.

TABLE IV.

Sphincters in injury.

	Not affected. Per cent.	*Affected.* Per cent.
Concussion of the brain	77	23
Fracture of the base of the skull.	39	61
Fractures of the vault of the skull.	40	60
Compression of the brain	0	100

(III) SPINAL INJURIES.

Spinal injuries can be divided into two classes—when the injury is slight and transitory, and when it is gross and permanent. The former class will include true cases of spinal concussion and a few of spinal hæmorrhage; the latter will include larger hæmorrhages and transverse lesions.

In a paper in the 'Lancet,' September 22nd, 1906, entitled "Concussion of the Spine," I endeavoured to show the points upon which such a diagnosis could be made clinically, and also in what classes of case it would be recognised. In this variety of spinal injury whether the sphincters are affected or not depends upon the duration of the symptoms of the concussion. In the two cases of local spinal concussion which were recorded (Cases 1 and 2), the symptoms only lasted for a time, the duration of which was far too short for any affection of the sphincters to

be noted. In the case of general spinal concussion recorded in the same paper (Case 6) there was retention of urine which had to be relieved by a catheter. In another case of spinal concussion, which has not yet been reported and which recovered, there was retention of urine. This is what would be expected. In this case, as in the former, the retention was not allowed to proceed to overflow. A similar retention of fæces was present, followed by constipation.

Gross spinal injuries may be divided with regard to the sphincters into two classes—supra-lumbar, above the centres in the cord, and lumbar, involving the centres.

Supra-lumbar.—There are various stages in the conditions of the sphincters which can be seen as the patient recovers.

(1) Owing to the dulling of the excitability of the lumbar centres immediately consequent on the injury and probably due to some hæmorrhage or concussion, active retention of urine occurs, which is of the non-paralytic kind, and if unrelieved will proceed to active, and perhaps later to passive, overflow of urine.

(2) At a variable time after the accident the lumbar centre recovers its tone and micturition occurs reflexly and unconsciously, the bladder periodically emptying itself.

(3) Later still the centre sometimes becomes hypersensitive or spastic; micturition, like other reflex acts, becomes exaggerated, the bladder expelling its contents at shorter intervals than in the second period.

The rectum is affected similarly to the bladder, but differs in its solid contents, its tolerance of the same, etc. Hence, during the stage of active retention of urine, active retention of fæces and constipation will be present. Later, a reflex expulsion of fæces may occur; and later, this act may become more frequent and the reflex exaggerated.

Lumbar.—When the lesion is nuclear and involves the lumbar centre, then the typical paralytic condition described in the later stages of compression exists for both bladder and rectum.

The *infra-lumbar regions* are considered in the next section on the lesions of nerves.

TABLE V.

(*a*) Supra-lumbar lesions.

(1) *Bladder.*

(1) Active retention and its possible sequels.
(2) Unconscious micturition.
(3) Exaggerated unconscious micturition.

(2) *Rectum.*

(1) Active retention of fæces and constipation.
(2) Unconscious defæcation.
(3) Exaggerated unconscious defæcation.

(B) *Lumbar lesions (same as Table III).*

(1) *Bladder.*

(1) Passive retention and its possible sequels.
(2) Active paralytic overflow.
(3) Passive paralytic overflow.

(2) *Rectum.*

(1) Incontinence of fæces.
(2) Passive retention of fæces.

In spinal concussion the sphincters will escape in far the majority of the cases. But should they be affected, they will be like the bladder and the rectum as above stated, according as the concussion is above or involves the lumbar centres. These symptoms will last as long as does the concussion unless it is complicated by a hæmorrhage.

(IV) Lesions of Nerves.

The effect of nerve-lesions upon the sphincters has never been brought to the notice of clinical observers, and it is to do this that I append the following brief descriptions.

Bladder.—Professor Sherrington confirmed previous observers as to the double nerve-supply to the bladder, one from the lumbar and one from the sacral nerves. The latter produces the more powerful contractions. Professor Langley and Dr. Anderson ('Journal of Physiology,' vol. xix, p. 73) confirmed Professor Sherrington's observations, and added that stimulation of the lumbar nerves gave rise to contractions of the bladder which were insufficient to produce micturition. Former observers had adapted von Basch's theory of the double innervation of the

intestine and applied it to the bladder, making one set of nerves, the lumbar, govern the contractions of the longitudinal coat and the other, the sacral, affect the circular coat. All the above authors and Mr. Joseph Griffiths ('Journal of Anatomy and Physiology,' vol. xxv, 1891) failed to confirm this, stating that on stimulation of either set of nerves the whole musculature of the viscus contracted. They were concerned with the contraction of the body of the viscus and not with that of the sphincter vesicæ. The action of the latter was excluded by the method employed to record the contractions of the bladder—namely by means of the movements of a column of fluid connected with the bladder by a catheter in the urethra. The catheter prevented the contraction of the sphincter being seen. It is consequently not so easy to obtain information upon the action of the nerves on the sphincter vesicæ. Professor Langley and Dr. Anderson, also Professor Sherrington, pointed out that stimulation of the lumbar nerves caused contraction of the body of the bladder, and especially the parts at the base—*i. e.* probably the sphincter round the catheter. Professor Thane, in Quain's 'Anatomy,' vol. iii, Part II, quotes Dr. Head for showing that the upper nerve-supply is responsible for "feeble contraction and over-distension of the bladder." It seems probable, therefore, that the upper (lumbar) nerve-supply, when stimulated, causes a weak general contraction of the body of the viscus with a strong contraction of the sphincter; hence the "over-distension" observed by Dr. Head, and the failure of stimulation of these nerves to produce micturition as observed by Professor Langley and Dr. Anderson. Stimulation of the lower set of nerves, the sacral, causes stronger contractions of the body of the bladder with micturition, and also, possibly, relaxation of the sphincter vesicæ.

From the above it is possible that in some clinical cases, such as tumours of the cauda equina, caries of the spine, etc., each set of nerves may be involved separately.

(1) In paralysis of the upper set (dorsal 11 and 12, lumbar 1, in man, according to Professor Thane, *loc. cit.*) there will be paralysis of the sphincter vesicæ, leading to a purely passive retention of urine, which will later be discharged in small gushes as only the *passive* urethral resistance is encountered, active paralytic overflow and later still, possibly but improbably, passive paralytic overflow.

(2) In paralysis of the lower set (2, 3, and 4 sacral in man, according to Professor Thane, *loc. cit.*) there will be paralysis of the body of the bladder, leading to retention of urine of an active kind, which will remain absolute or result probably in a passive rather than an active overflow.

The rectum.—The rectum has a double nerve-supply like that of the bladder. Professor Sherrington (*loc. cit.*, vol. i, p. 672) studied the action of these nerves upon the anus alone—*i.e.* the sphincter ani. Stimulation of the upper set caused contraction of the sphincter ani; whilst stimulation of the lower set caused its relaxation, thus agreeing with what has been said of the action of the two sets of nerves upon the sphincter of the bladder. Professor Langley and Dr. Anderson ('Journal of Physiology,' vol. xviii, p. 104) exhaustively examined the innervation of the lower part of the intestine—*i.e.* the part which corresponds to the body of the bladder. They found that stimulation of the lumbar set of nerves caused a doubtful dilatation of the rectum and colon; whilst that of the sacral nerves caused powerful contraction, in which they included the sphincter ani. The double nerve-supply of the rectum is precisely analogous to that of the bladder, except that the sphincter ani can be contracted *with the bowel* by the sacral set of nerves and *without it* by the lumbar—a social blessing.

Von Basch's theory of the double innervation of the longitudinal and circular muscular coats is therefore possibly as untrue for the lower bowel as it has been shown untrue for the bladder.

If, pathologically, the two sets of nerves were paralysed independently of each other, the following conditions would appear:

(1) Paralysis of the upper set of nerves (lumbar, exact nerves unknown) will cause paralysis of the sphincter and incontinence of fæces provided that the latter are of consistency to allow of their expulsion; otherwise there will be constipation.

(2) Paralysis of the lower set (sacral, precise nerves unknown) will cause paralysis of the gut, leaving the sphincter contracted. Hence there will be an active retention of fæces and constipation.

The results on the bladder and rectum of lesions of one of these two sets of nerves may be briefly stated together, as the nerve-supplies of these viscera are probably the same or thereabouts.

TABLE VI.

(1) *Paralysis of the upper set.*

(1) Unconscious micturition or active overflow of urine.
(2) Incontinence of fæces (perhaps constipation clinically).

(2) *Paralysis of the lower set.*

(1) Active retention of urine and possibly, later, passive overflow.

(2) Active retention of fæces and constipation.[1]

Before concluding, I wish to point out one or two results other than those in the various tables.

It is desired that the different effects of retention in the male and the female should be clear and possible misunderstandings avoided. In both the paralytic and the non-paralytic states the female is far more prone to overflow of urine, apart from her immunity to stricture, etc., owing to her short, dilatable urethra.

It will also be noticed that there is a perfect sequence of states from that resulting from slight concussion on the one hand to the paralytic condition of marked compression on the other. And as the higher or more severe grades in this series are reached there is a greater tendency for the retentions of urine to become overflows more easily, indicating that the greater the violence the greater is the tendency to some paralysis of the sphincters and for the active retention to become a passive retention, owing to the abolition of the active muscular resistance of the urethral and rectal sphincters.

Further, it will be noticed that I have introduced new terms,

[1] A case was sent me by Dr. Meacock, of Wisbech, which illustrated admirably the clinical picture of a growth in the lower part of the cauda equina. The patient had increasing frequence of micturition for some months. There was no obstacle to the passage of urine, but he was unable to empty his bladder from lack of contractile power. The amount of residual urine varied from 15 to 25 ounces. He had not the same difficulty with his bowels, though they were inactive and sluggish. My colleague, Dr. Box, diagnosed a tumour of the cauda equina, the presence of which was suspected from the physiological results quoted above. No opportunity of confirming the diagnosis, however, has occurred. Such a tumour would prevent the emptying of the bladder by paralysing it, at the same time causing an active retention on account of the unopposed action of the lumbar nerves on the sphincter vesicæ.

if not new ideas, in some instances. The distinction between active and passive retention is, that in the former the sphincter is active and in the latter it is passive or paralysed. Similarly, the active overflow is due to the spontaneous and rhythmic contractions of the bladder itself; and passive overflow is the purely mechanical result of more urine entering the fully distended bladder from the ureters and displacing some which was already there. This over-distension paralysis of the bladder can occur in active retention of urine—*i. e.* in the non-paralytic state; but in paralytic retention the bladder will probably never become sufficiently distended for it to be paralysed. Thus, in the paralytic condition it is most probable that the rhythmic contractions of the bladder persist, so that only active overflow is to be expected. It is a great help in understanding the conditions of the sphincters if it is remembered that every passage of urine, paralytic or non-paralytic, is preceded by some variety and degree of retention.

Finally, it would be well to have a clear understanding of the words used to denote the different states of the bladder, etc. Normally, urine is passed by means of a reflex act sanctioned by the higher centres, to which I would give the name of "normal" or "conscious micturition." When the reflex act occurs without regard for the higher centres the name of "unconscious micturition" should be given it. The word "incontinence" should be used for the passage of excreta other than by a reflex act; which, in connection with the bladder, can be resolved into overflows, paralytic or otherwise, active or passive, which carry with their names distinctive meanings. The name "incontinence" in connection with the subject of this paper, need only be retained for the abnormal passage of fæces—*i. e.* solids which cannot overflow. And, further, there cannot be an incontinence or overflow without a previous retention. The name "overflow" indicates this, and is therefore much to be preferred to "incontinence." If such a scheme be adopted as is outlined in this paper, and the word "incontinence" defined and discarded in all other senses, the conditions of the sphincters in surgery may be easily understood.

November 6th, 1906.

6. *Fœtal bone disease.*

By F. S. Dawe.

The specimens shown are the femur, tibia, and fibula of the right side and two ribs.

The two slides are sections of the two beads of another rib.

Clinical history.—The mother, a domestic servant, was a young and apparently healthy woman. There was no history of miscarriages, syphilis, or starvation. She had not had a child before. The father could not be traced.

The child was born eight months after menstruation ceased. It weighed 4 lbs. 10 oz. The presentation was a breech, but labour was precipitate and delivery easy. All six long bones of the lower extremities were fractured, although the legs were not pulled on during delivery. The region of the great trochanters could be felt to be enlarged. The arms, though deformed, were not broken, the tuberosities of the humeri were enlarged, the bones of the forearms bent, and the elbows could not be fully extended. In the skull the bones of the vault presented no bosses or craniotabes, but they were all separated from one another. The anterior fontanelle was tense.

The child took food well at first but succumbed to an attack of diarrhœa seventeen days after birth.

Post-mortem examination.—There was no separation between the ring and middle finger; the limbs were not out of proportion to the trunk nor were the buttocks unduly prominent.

In *the skull* the sutures were all widely open; thus there was half a finger's breadth between the occipital and the squamosal, otherwise the bones of the vault were ossified normally.

The thorax was of normal shape but the ribs were peculiar. Each rib presented a bead at the costo-chondral junction, and most of the ribs presented a second bead half an inch from the first as in the specimen shown.

Microscopic examination of sections of these beads shows a condition very similar to that of rickets.

The pelvis presented nothing obviously abnormal.

The right humerus presented an enlargement in the region of the tuberosities and was enlarged also at the lower end.

The right femur.— Hip-joint normal; the region of the trochanters was occupied by a bony mass larger than a hazel-nut. Below this tumour an oblique fracture devoid of callus, and so presumably of recent origin, ran down the shaft. The lower epiphysis of the femur, as one would expect in an eight months' child, had no centre of ossification.

Right knee-joint.—Normal.

Right tibia.—The shaft was deformed, bent forwards and inwards and flattened laterally. The upper epiphysis was separated and a recent fracture was present at the lower end of the shaft.

Right fibula was bowed inwards; at the centre of the bend there was a small bead like those on the ribs, below which there was a recent fracture.

The bones in the limbs of the left side were not dissected, but felt through the skin they seemed to present similar abnormalities.

The viscera appeared to be normal for a fœtus of eight months. There was no hydrocephalus, and the brain was normal.

This case, I think, resembles the disease described by Ballantyne in his 'Ante-natal Pathology' under the name of "chondro-dystrophia fœtalis hyperplastica," in the following points: (1) fractures at birth, (2) bony masses in the regions of the tuberosities and trochanters, (3) the presence of an organ-pipe arrangement of the cells, but with a disturbed and irregular process of ossification.

It differs from a typical case in the absence of (1) flat pelvis, (2) club foot, and in the presence of a double bead instead of a single bead on the ribs.

It differs from achondroplasia, amongst other points—in the presence of (1) an organ-pipe arrangement of cells; and in the absence of (1) short limbs (2) prominent buttocks, (3) separation of big and middle finger.

November 6th, 1906.

7. *Round-celled sarcoma of the abdominal lymphatic glands and stomach.*

By Norman Dalton.

The subject, G. E—, was a male, aged 15 years. Abdominal pain and swelling had been noticed for about three or four months. At the *post mortem* the body was extremely emaciated. The glands near the junction of the thoracic duct with the veins in the neck were moderately enlarged and very soft. The superior and posterior mediastinal glands were large and soft and nearly all of them were quite white. Several white tumours, like glands, were seen on the upper surface of the diaphragm. One of these had invaded the right pleura and had become quite diffluent. It may be said here that none of the enlarged glands nor of the other growths had become hæmorrhagic. There were no growths actually inside the lungs. The pericardium and the heart were normal, but the liver and kidneys contained a few soft white growths, none being of large size. The spleen was normal. The retro-peritoneal glands throughout were large, soft, and white. A large mass of white growth of medium consistence occupied the upper and middle part of the abdomen, pushing the transverse colon downwards. It was found to consist of—(1) a growth at the pyloric end of the stomach, (2) a growth of the omentum and transverse mesocolon, (3) enlarged retro-peritoneal glands.

The growth in the stomach appears to have commenced in the greater curvature about three inches from the pylorus. It is at that point that the tumour is thickest except for the presence of an ulcer. It had grown from there to the right until it just reached the pylorus, and towards the left for about three inches. It had spread over the anterior and posterior walls of the stomach but it does not quite reach the lesser curvature, so that it is not completely annular. In the middle of the mass on the greater curvature there is a deep rounded ulcer the size of half a tennis-ball, and from this ulcer there is a finger-like prolongation, cut like a groove in the growth and mucous membrane, and extending towards the cardia. The round ulcer and its prolongation have the smooth, punched-out appearance of a typical peptic ulcer,

and are quite unlike the ragged ulcerations of cancer. At the sides of the ulcers the growth bulges out into the cavity of the stomach. The floor of the round ulcer is directly continuous with the mass of growth in the omentum. It is difficult to say whether the tumour began in the stomach and spread to the omentum or *vice versâ*, but I incline to the latter view. The punched-out character of the ulceration suggests that the arterial supply to the stomach was cut off and that digestion of the anæmic piece followed. If this be correct it would favour the view that the growth extended from the omentum to the stomach and destroyed early the arteries at the involved portion of the greater curvature. Such an extension to the stomach is believed to have occurred in the case reported by Perry in the 'Glasgow Medical Journal' 1883, vol. xx, p. 215. The fact that the growth is clearly oldest at the greater curvature might also be supposed to favour this view, but Corner and Fairbank have shown that the pylorus and the lesser curvature are not so much the favourite sites of sarcoma as they are of carcinoma.

Microscopically the growth consists of small round cells with delicate fibrillæ between them. In the stomach the masses of cells infiltrate all the coats. The growth is not very vascular, which explains its white appearance to the naked eye and also the absence of hæmorrhages. The vessels which are present have well-defined walls. It will be seen that the prevailing type of cell, at any rate in the stomach, is not a lymphocyte but of the type seen in an ordinary small round-celled sarcoma. In the lymph-gland there are more lymphocytes. There are no giant cells. Now, although from the histological point of view the growth should be labelled round-celled sarcoma rather than lympho-sarcoma, I am anxious to point out that in other respects and more particularly as regards its distribution and mode of infection it is more like a lymphatic growth than an ordinary sarcoma. The points are:

(1) Even if the stomach tumour be the primary growth it has spread by the glands and not by the blood-vessels. The small growths in the kidney and liver might be considered to be evidence against this statement, but I regard these as the result of a terminal general infection such as occurs even in carcinoma.

(2) There were masses of enlarged retroperitoneal glands

below the direct line of lymphatic infection from the stomach to the thoracic duct. This suggests that there was a general development of growth in many glands, as in lymphadenoma, and not an infection from one primary growth as in ordinary sarcoma.

(3) None of the glands examined had any localised tumour in them. They were all quite uniform in appearance and extremely white. In fact, they might have passed as lymphadenomatous glands except that none of them had become hard.

For the above reasons I think that the growth began in the lymphatic structures of the abdomen, although the cells became rapidly atypical.

December 4th, 1906.

---

8. *Observations upon the poison of the Weever fish* (Trachinus draco).

By H. Muir Evans.

De veneni actione piscis Trachinus.

Summarium.

Apud piscatores saepe reperiuntur læsiones spinis hujus piscis causatæ,—dolor tumorque acuti, forsitan et inflammatio phlegmonosa et gangræna.

Variant effectus ad puncturæ altitudinem et ad anni tempus, veneno genituræ tempore maxime nocente.

Organum veneficum et veneni quidam effectus, veneno sub cute injecto, a Bottard[1] jam descripta sunt.

Illa experimenta et repetivi et amplificavi.

Veneno ex operculi glandulâ per cannulam extracto usus sum.

Venenum siccatur; solvitur, deinde, in liquore sodii chloridi.

[1] 'Les poissons venimeux,' Paris, 1889.

Ex meis experimentis hæc exempla licet proferre.

·015 grm. veneni siccati in Cyprinum injecto, piscis horas post paucas cum paralysis notis mortuus est.

·01 grm. venemi injecto, piscis post dies decem mortuus est, cum tumore atque focis hæmorrhagicis in situ injectionis, peritonæi vasibus quoque congestis.

·005 grm. veneni injecto, piscis post dies octo mortuus est; in situ injectionis tumor repertur mollis, in quo necrosem causari incisio demonstrat.

In ranâ, in mure, et in caviâ, veneno injecto, similia efficiuntur.

Postquam venenum in venas injectum est, sanguinis pressio augetur, descensus, autem, profundus cito consequitur; respiratio, tamen, postquam cor pulsari cessavit paulisper continuit.

Actio veneni hæmolytica.

Accidit hæmolysis sine seri additione quum venenum cum corpusculis lavatis miscetur (*Perca fluviatilis*, *Leuciscus rutilis*).

Experimenta insuper facta sunt cum columbæ sanguine, et cum illo caviæ, ovis, bovis, equi, atque hominis.

Hæc veneni actionem hæmolyticam demonstrant, actionem quæ sine seri additione accidere potest. Animalis ejusdem, aut animalium aliorum seri additio in quantitate quæ per se hæmolysem causare haud sufficit, actionem hæmolyticam auget.

In casubus plurimis, serum addendum si horam unam calefiat (62° C.) potentiam aliquatenus amittit.

Ut amboceptor sic se gerit venenum quod cum sanguinis corpusculorum endocomplementis conjungit.

The painful wounds inflicted by certain fish which are commonly caught by fishermen around our coasts are well known to all who are in any way brought in contact with the men who supply our markets with fish. However, those who most frequently suffer from the pricks from spinous fishes are trawlers, because the weever is less frequently found in the nets of herring or mackerel fishermen. Amateurs are not infrequently stung through ignorance of the dangerous nature of these fish.

There has been comparatively little written in this country upon the subject, and those who would read an interesting account of fish with poison organs will find the whole subject

FIG. 18.

The head of the weever fish (Trachinus), showing the opercular spine. Nat. size. (From a specimen in the Museum of the Royal College of Surgeons.)

EXPLICATIO FIGURÆ.

Piscis (Trachinus) caput, operculi spinam, glandulâ veneficâ præditam monstrans. (Magnitudinis naturalis.)

treated historically and descriptively by Dr. Bottard in a work published in 1889 entitled 'Les Poisons Venimeux.'

It is important to bear in mind that the weever fish is not poisonous, although it has a poison organ; that is to say that the fish is both perfectly good to eat and also has an excellent flavour, yet it has the power of inflicting dangerous wounds by certain spines on its dorsal fin and on either gill-cover or operculum.

The following account of the symptoms of a weever sting is quoted by Bottard:

"I have been pricked several times by *Trachinus vipera*

and I am able to give an exact account of the various phenomena the result of such an injury.

"The symptoms are almost always the same. They differ only according to the depth of the puncture and the site of the wound, also according to the time of the year and the nature of the spine, whether it be dorsal or opercular.

"In the month of October, 1885, I was pricked fairly deep, in the middle of the palmar aspect of the right thumb. The pain was similar to that of a burn. At the end of only a few seconds all the other fingers, as well as that pricked, had become immovable and were painfully numb. In two or three minutes the numbness had reached the forearm. The numbness seemed to follow the course of the nerves. The joints were particularly tender. At the end of from five to seven minutes the poison made itself felt on the heart, as shown by somewhat severe palpitation. I then felt cold and shivered. The wounded hand all this time was very painful and tender to the least touch. I was unable to dress it until three quarters of an hour after the accident, when it was impossible to move the arm and I was unable to undress myself alone. Three days after the surrounding parts were still very painful and the tissues were swollen."

Gressin describes the symptoms as follows: "One experiences at first a very acute pain, lancinating and paralysing, often among nervous persons associated with fainting. Then a sort of painful tingling attacks the wounded part, which swells up and becomes inflamed, and perchance, if one neglects to attend to it this goes on to phlegmonous inflammation and gangrene. Frequently certain general symptoms, as fever, delirium, and bilious vomiting, accompany this state. They may last two or three hours, or make themselves felt for several days. The fishermen attribute, with some reason, this irregularity in the effects according to the amount of poison inserted or the time of year, the spawning season being most dangerous.

My investigations into the poison organ of *Trachinus draco* were the results of observing the pain and suffering among all associated with the fish trade, both fishermen and packers. I must express my indebtedness in the first place to Mr. Borley, of the Marine Biological Association at Lowestoft, who has examined with me the anatomy, both naked eye and microscopic, of the weever, and has also helped me in getting together the literature

of the subject, and in the second place to Professor Sidney Martin, in whose laboratory and with the help of whose assistant, Dr. Stevenson, the experiments into the physiological properties of the venom took place. I must further thank Dr. Stevenson for the great interest he has taken in the subject and the time he has willingly put at my disposal.

The most recent work on the subject of the venom of *Trachinus draco* is to be found in several communications by M. A. Briot in the 'Comptes Rendus de la Société de Biologie de Paris' (1902–1904). The experiments of my own several years later were made in complete ignorance of this work and therefore have the value of being free from any bias. This literature was not referred to in so recent a work as the 'Cambridge Natural History' of 1905.

The methods adopted by Briot in the matter of collecting sufficient poison for investigation differed to some extent from those of Phisalix. The latter macerated the gland in chloroform-water and glycerine, and the fluid resulting from this maceration was used in his experiments. Briot took the venomous spines and adjacent tissues, and pounded them in a mortar and made a glycerine extract. He used the filtered liquid for his researches and for the purpose he used the opercular and dorsal spines of 350 weevers caught between the end of May and beginning of June and 70 caught in September.

The method that I employed was, I think, more scientific and accurate. I obtained freshly caught weevers from a buyer who was in the habit of collecting fish for the Board of Trade and could be thoroughly trusted. These I washed under a tap and with pledgets of absorbent gauze wiped any mucus and dirt from their opercular spines. I then laid the fish in rows and again wiped the heads with wool. With a sterilised syringe I extracted from within the sheath, by means of inserting the needle along the groove of the spine, as much poison as possible, obtaining, no doubt, a certain quantity of cellular elements; but I avoided those heads in which there was *post-mortem* staining of the vascular tissue of the sheath. The fluid thus obtained, say from 100 fish, was collected in a watch-glass and placed in a desiccator (Hempels) the rim being filled with pure sulphuric acid and the air exhausted by means of a pump. In this way from nearly 2000 fish I obtained several grammes of dried

weever poison. This, before making experiments, was finely powdered in a pestle and mortar, and dissolved in either distilled water or normal saline solution. These solutions were used either with a certain quantity of solid matter suspended, or filtered, or better, after being centrifugalised to obtain a resulting clear fluid; control experiments were made with the fresh venom.

Briot says he was the first to make intravenous injections in the rabbit. Half a cubic centimetre of his solution caused death so rapidly that he had not time to finish his injection. With ·2 or ·1 c.c. death was slower, taking several minutes, and according to this observer it was death by asphyxia. To quote (p. 1170) 'Comptes Rendus Soc. Biologie,' in opening the animal immediately after the pupil reflex was abolished one found that the blood was not coagulated in the portal vein or heart. The heart continued to beat for several minutes and artificial stimuli caused it to contract for some little time. There was no doubt that death was due to respiratory failure. I was not able to say precisely whether this was due to a direct paralysis of the respiratory muscles or to an effect on the respiratory centre. But I am inclined to think that it was due to a direct action on the respiratory muscles as much from the rapidity of the death as from the fact that when death did not result in a relatively short time (8 to 10 minutes) it did not occur later. While, if the venom of a snake is injected into the circulation the dose and the length of survival are almost in inverse proportion, it is not more so the case with venom poison.

The local effects of the poison injected subcutaneously have been described by Bottard and Gressin. It produces mortification of the tissues. It appears to produce a local paralysis which is very evident in experiments on fish. If one injects the poison in the region of the lateral line the fish is sharply bent away from the lesion on account of the predominant action of the lateral muscles on the opposite side. These experiments have been repeated in the laboratory of University College.

A gold fish (*a*) four inches in length died in one hour and a half after injecting ·015 grm. dried venom.

Another (*b*) in four hours with the same dose. Seven minutes after injection it lay on its left side, curved away from the site of inoculation which had been made into the muscles of the right lateral line.

Another (*c*) injected with ·01 grm. showed the next day some local swelling at the site of injection and continued to live until ten days after commencement of experiment. The *post mortem* showed extravasated areas of blood at the site of inoculation and great congestion of peritoneum.

Another (*d*) with ·01 grm. died three days after injection and showed a marked hæmorrhagic area along track of needle.

Gold fish (*e*) injected with ·005 grm. died eight days after inoculation. There was a soft, puffy area with swelling where the injection took place. On incision into this there was a small cavity in the muscles, with ill-defined, breaking-down walls. It seemed as if there was a pure necrosis of muscle. The surrounding area showed bloody engorgement well seen on the peritoneal aspect.

Frog.—·015 grm. caused death in 2½ hours with paralytic symptoms.

Mouse (*a*).—·02 grm. dried venom caused the death of a mouse from a dry necrosis at the site of inoculation in two days. During the day after injection there was marked paralysis of the hind quarters, the injection having been made under the skin of the back. The large vessels in neck and axilla were engorged and the sinuses of the brain were full.

Mouse (*b*).—Injected with ·01 grm. dried venom, showed weakness of hind quarters two days after injection, and five days after a small greenish area appeared on the skin at the site of inoculation.

The animal died seven days after the injection with similar local symptoms as described in (*a*), but the brain-sinuses were not so engorged.

Guinea-pig.— ·05 grm. intra-peritoneal injection caused death in three hours. After preliminary pallor and convulsions, the animal became gradually weaker and showed paralysis of the hind quarters. After two hours the heart could not be felt beating, but catchy respirations continued for another hour.

Post-mortem.—There was clotting in the superficial vessels and general venous engorgement.

Intravenous Injections.

The results of experiments as illustrated by simultaneous tracings of carotid blood-pressure and respiratory movements do

not altogether agree with Briot's statement that death, in the case of intravenous injections, is due to respiratory failure. The action appears to follow the course of that which occurs with most snake venoms—*i. e.* a slightly preliminary rise followed by a very rapid and deep fall in blood-pressure.

Experiment 1.—Rabbit. Weight 1900 grm.; anæsthetic ether. After an injection of ·05 grm. dried poison, there was a fall in blood-pressure lasting forty-five seconds. Then, after twenty seconds of irregular low pressure, the pressure gradually rose. After an interval of seven minutes, during which the cardiac pulsations had steadied down to a normal rate, a further ·05 grm. of dried venom was injected into the femoral vein. Immediately the blood-pressure fell rapidly for twenty seconds with almost imperceptible cardiac pulsations and in two and a half minutes a further fall took place immediately preceding complete cardiac failure and death.

Experiment 2.—Cat. ·1 grm. dried venom, weight 3400 grm.; ether. Immediately after injection marked fall of blood-pressure and eighteen slow, powerful beats in ten seconds—*i. e.* 104 per minute (normal 192 per minute). This was followed by a rise of blood-pressure in ten seconds to normal and then another gradual fall with marked slowing of the beats. Thirty-three seconds from first injection the cannula was washed out with ·86 per cent. sodium chloride solution and the cardiac contractions continued to become gradually small and the pressure fell so that two minutes from the commencement of the experiment the heart had ceased to beat. During this time the respiration, although affected so as to become at first shallow and then every fifteenth breath a deep inspiration, continued and there were nine deep inspirations during the period of nearly two minutes which elapsed between the last cardiac beat and the last respiration.

This tracing shows, in a very convincing way, the typical fall of blood-pressure, the result of an intravenous injection of a venom, and controverts the theory that the cause of death is in the case of weever poisoning always due to respiratory failure.

Experiment 3.—Cat. Weight 3300 grm. Ether injected with ·1 grm. dried venom dissolved in 5 c.c. of an 86 per cent. sodium chloride solution; the resulting solution was then centrifugalised and the clear fluid injected into the femoral vein.

For twenty seconds from the commencement of the injection

there was a slight fall in blood-pressure, followed during the next fifteen seconds by a slight rise. Then forty seconds from the commencement of the experiment there was a gradual and deep fall of pressure, reaching its lowest point two minutes from the commencement. During this fall the cardiac pulsations became less strong, the rate being 150 per minute as against a normal of 168 per minute. During the first thirty seconds the respirations were 8 per minute as against a normal of 9 per minute; they gradually quickened until at the end of the second minute they amounted to from 14 to 12 per minute. Four minutes from the commencement the respirations had slowed down to 6 per minute, with cardiac pulsations stronger—96 per minute. At the eighth minute the respirations became very slow, while during the ninth minute respirations were very irregular—4 per minute, with clonic twitching of abdominal and leg muscles. During the tenth and eleventh minutes there were only 2 respirations per minute with clonic twitchings; in fact, death almost resulted from respiratory failure. During the fifteenth minute the animal began to recover—6 respirations per minute and heart 126. The experiment was then completed.

In this case death did not result from the immediate action on the cardiac system, but the later effects on the respiration nearly ended in death.

It would, no doubt, have been interesting from a scientific standpoint to have gone further and repeated these experiments after division of the nerves, but inasmuch as the poison is not in practice ever injected in sufficient quantity to cause death either by heart failure or respiratory failure, it seemed more important to study the local effects and the blood-changes which not infrequently result in man in phlegmonous inflammation and septicæmic conditions.

Hæmolytic Action of Weever Poison.

This has been studied up to a certain point by M. Briot, but only as regards the blood of warm-blooded animals.

It has been stated, according to Calmette, that snake venom only produces hæmolysis in certain animals unless there are also present certain components of serum. If red corpuscles are washed in normal saline and venom is added, no solution

occurs. But if normal serum heated to 62° C. is added, hæmolysis occurs. It is necessary to heat the serum to prevent an anti-hæmolysin present at low temperatures from protecting the erythrocytes against the solvent action of the venom.

Briot has repeated those experiments of Calmette on snake venom with weever poison. In a series of test-tubes he put a drop of washed corpuscles in suspension in 2 c.c. of normal saline; he then added normal serum heated to 60° C. for one hour and variable doses of his solution of weever venom. Complete hæmolysis took place in one and a half hours. Two controls were observed, one without the venom and one without the heated normal serum; in neither tube did solution take place, neither did it take place when unheated serum was added. Briot also observed that the hæmolytic effect of the venom remained intact after heating for an hour at 75° C., and that even after heating for twenty minutes at 100° C. dissolution took place, though slowly.

A most important contribution to the study of venoms was published by Flexner and Noguchi on hæmolysis by snake venom in 1902. These authors found that although red corpuscles whose serum has been removed by washing are agglutinated by snake venom, they are not dissolved. If, however, serum is added, hæmolysis occurs. The conclusion is thus reached that snake venom is made up of substances acting after the manner of amboceptors which are activated by certain complements of the serum. In fact, snake venom does not act as a simple poison after the manner of toxins but in a complex manner, being identical in action with the hæmolysins of blood-serum as this has been conceived by Ehrlich and Morgenroth.

Kyes proceeded to experiment with cobra venom on the blood of different animals and found that there were two groups of blood-cells—(1) those that are in themselves dissolved by cobra venom, (2) those that are only affected by venom after the addition of other substances, complements, etc. He then proceeded to show that the red corpuscles that were in the first group were only acted upon by the venom because they themselves contained endocomplements which allowed the amboceptor of the venom to act on the cell.

It is not for me to discuss the experiments which proved this point; but they are very convincing, and there seems no doubt

that certain blood-cells themselves contain complement-like substances or endocomplements.

The following experiments were carried out with venom extracted from recently caught fish. Hæmolysis took place without the addition of sera with the blood-corpuscles of roach and perch when one drop of venom was added to a suspension of their blood-corpuscles, made according to Briot's technique.

It seemed important, having made these preliminary investigations with the blood of fish, to carry them further into the realm of warm-blooded animals, and for this purpose I provided myself with an excellent centrifuge, worked by water power, made by Baird and Tatlock. The blood of the following was used: pigeon, guinea-pig, sheep, ox, horse, and man. The more exact methods of hæmolytic experiments as employed by Ehrlich's school and fully described in an article by Morgenroth in Ehrlich's collected studies on immunity were used in these investigations.

The blood, having been defibrinated, was centrifuged to remove the serum, which was carefully pipetted off; 10 c.c. of normal saline was added to ·5 c.c. of corpuscles and well mixed, centrifuged, and the clear solution pipetted off. This was repeated three times and finally a 5 per cent. emulsion of red corpuscles was made in ·85 salt solution; either 2 c.c. or 1 c.c. of this solution was put in a series of tubes, the poison added in varying doses, and the mixture put into the incubator for two or more hours.

With pigeon's blood one drop of a 50 per cent. solution of fresh weever poison was sufficient in two hours to produce marked hæmolysis.

The poison solution used was obtained by extracting the venom with a needle and syringe previously sterilised; in order to get all the milky fluid from the syringe an equal quantity of salt solution was added to wash it out, so that one obtained a 50 per cent. solution of fresh poison. This was kept in a cellar on a block of ice in the dark and in this way its virulence remained intact. From a great number of experiments I found that uniform results were obtained if the poison was removed from freshly caught fish and extracted at once. It appears, as the fishermen state, that the poison loses its effects soon after death. With one specimen of venom I got most contradictory results which were due to my using a batch of 100 fish which were not quite fresh although they had been kept on ice.

The effect on birds is interesting, inasmuch as a smacksman has related to me how he has seen gulls fall into the sea as if struck dead when he has thrown live weevers overboard to them. With guinea-pig corpuscles two drops of 50 per cent. weever poison were added to one tube containing 2 c.c. emulsion, and to two other tubes the same quantity of weever poison + in one tube some normal serum and in another serum heated for an hour at 62° C. In all three tubes marked hæmolysis took place, in the control none.

We see here again the presence of endocomplements in the guinea-pig corpuscles, and we had a slightly greater action with the presence of heated serum than with unheated serum.

A similar experiment was made with sheep's blood. In this case with 5 per cent. emulsion and two drops 50 per cent. weever poison there was advanced hæmolysis, and with the same quantity of poison with both normal serum and serum heated for an hour at 62° C. there was complete hæmolysis after two hours in the incubator at 37° C. We have here a very marked example of the amboceptor of weever poison combining with the endocomplement of the sheep-corpuscles resulting in rapid hæmolysis. The increased hæmolysis with the added serum was not affected by heating to 62° C.

With human blood we find that there is hæmolysis of the washed corpuscles without the addition of serum. But unless the venom is quite fresh one drop of the 50 per cent. solution is not sufficient to produce hæmolysis, although two drops suffice. It seemed important in the light of Briot's investigations previously referred to to be quite sure of this. The following experiment was very conclusive. Six tubes, each containing 1 c.c. of 5 per cent. washed human corpuscles, were numbered 0, 1, 2, 3, 4, and 5; 0 was the control.

1 contained 1 drop 50 per cent. weever poison.
2 „ 2 drops „ „ „ „
3 „ 3 „ „ „ „ „
4 „ 4 „ „ „ „ „
5 „ 2 „ + ·1 c.c. normal serum.

0 underwent no change after two hours at 37° C.
1 showed medium hæmolysis with dark red sediment.
2 showed well-marked hæmolysis with dark pink sediment.
3 showed well-marked hæmolysis with dark pink sediment.

4 showed very marked hæmolysis, almost complete, sediment being merely faint pink.

5 showed complete hæmolysis. Whitish sediment.

TABLE I.—*Guinea-pig corpuscles* 2 *c.c.*, 5 *per cent. emulsion in normal saline.*

Control.	2 drops weever poison 25 per cent.	2 drops weever poison 25 per cent. + normal serum ·1 c.c.	2 drops weever poison 25 per cent. + serum heated 1 hour at 62° C.
No change.	Marked hæmolysis.	Hæmolysis slightly less than without serum.	Marked hæmolysis more so than with venom alone.

TABLE II.—*Sheep corpuscles* 2 *c.c.*, 5 *per cent. emulsion in normal saline.*

	Control.	+ 2 drops 50 per cent. weever poison.	+ 2 drops weever poison 50 per cent. + normal serum.	+ 2 drops weever poison 50 per cent. + serum heated 1 hour at 62° C.
2 hours' incubation at 37° C.	*Nil.*	Advanced hæmolysis.	Complete hæmolysis.	Complete hæmolysis.

TABLE III.—*Human corpuscles* 1 *c.c.*, 5 *per cent. emulsion in normal saline.*

	Control.	+ 1 drop 50 per cent. weever venom.	+ 2 drops 50 per cent. weever poison.	+ 3 drops 50 per cent. weever venom.	+ 4 drops 50 per cent. weever venom.	+ 2 drops 50 per cent. weever poison + ·1 c.c. normal serum.
2 hours' incubation at 37° C.	No change.	Slight.	Marked.	Well marked.	Strong.	Complete.
Sediments	Normal.	Dark red.	Pink.	Faint pink.	Faint pink.	Whitish.

There seems no doubt that *trachinus* venom can dissolve human corpuscles without serum and that normal unheated serum does not delay but rather increases the solution. Experiments were made to endeavour to activate venom insufficient to dissolve the human corpuscles by means of sheep serum and ox serum. A venom of which one drop did not dissolve washed human

corpuscles was mixed with ·3 c.c. sheep serum, and a control was made with sheep serum only. The result was that with one drop weever poison + ·3 c.c. sheep serum there was marked hæmolysis; the control showed agglutination but very faint hæmolysis.

A similar experiment was made with ox serum, ·1 c.c. of which was used for activation. There was complete hæmolysis with ox serum + 1 drop weever poison, and slight hæmolysis in ox serum and blood alone. In both the above experiments there were two other controls with the corpuscles and weever poison and no hæmolysis occurred.

A further experiment was made with ox serum heated for an hour to 62° C. With one drop of weever poison the control gave no result, with unheated serum slight hæmolysis, and with heated serum *nil.* With two drops the control had marked hæmolysis, unheated serum medium, and heated slight.

I have made experiments with the idea of activating the venom towards human blood by means of lecithin, and have succeeded on two occasions: but as other experiments have not given uniform results, I am continuing this investigation with lecithin recommended by Preston Kyes.

TABLE IV.—*Horse's blood* 1 *c.c.,* 5 *per cent. emulsion* + *varying quantities* 50 *per cent. weever venom.*

	Control.	+ 1 drop weever venom.	+ 2 drops weever venom.	+ ·05 c.c. normal serum control.	+ ·05 c.c. serum + 2 drops weever venom.	·05 c.c. serum heated at 62° C. for ½-hour control.	·05 c.c. serum heated at 62° C. for ½ hour + 2 hrs. weever poison.
2 hours at 37° C.	*Nil.*	Slight hæmolysis.	Well marked.	*Nil.*	Strong hæmolysis.	*Nil.*	Slight.

TABLE V.—*Ox blood* 1 *c.c.,* 5 *per cent. emulsion, six hours' incubation with* 50 *per cent. weever poison.*

	Control.	+ 2 drops weever poison.	+ ·5 c.c. $\frac{1}{10}$ normal serum control.	+ ·5 c.c. $\frac{1}{10}$ normal serum + 2 weever poison.	+ ·5 c.c. $\frac{1}{10}$ heated serum 1 hour at 62 control.	+ ·5 c.c. $\frac{1}{10}$ ox serum heated + 2 weever poison.
6 hours at 37° C.	*Nil.*	Well marked.	*Nil.*	Well marked.	*Nil.*	Strong hæmolysis.

TABLE VI.—*Activation of human corpuscles with sheep serum.*

2 c.c. 5 per cent. human incubation 2 hours at 37° C.	Control.	+ 1 drop 50 per cent. weever venom.	+ ·3 c.c. sheep serum.	+ ·3 c.c. sheep serum + 1 drop 50 per cent. weever venom.
	No change.	No change.	Agglutination.	Marked hæmolysis.

TABLE VII.—*Activation of human corpuscles with ox serum.*

2 c.c. 5 per cent. human incubation 2 hours at 37° C.	Control.	+ 1 drop 50 per cent. weever venom.	+ ·1 c.c. ox serum.	+ 1 c.c. ox serum + 1 drop 50 per cent. weever venom.
	No change.	No change.	Slight hæmolysis.	Complete hæmolysis.

Horse's blood gives the hæmolytic reaction with washed corpuscles alone.

Seven tubes were filled with 1 c.c. of 5 per cent. emulsion.

With one drop of weever poison slight hæmolysis took place; with two drops of weever poison hæmolysis well-marked; with two drops of weever poison + ·05 c.c. normal serum, strong hæmolysis; with two drops of weever poison + serum heated for half an hour at 62° C., slight. The controls were all negative.

Ox blood gave similar results.

With two drops of weever poison well-marked hæmolysis; with two drops of weever poison + ·5 c.c. $\frac{1}{10}$ normal serum, well-marked; with two drops of weever poison + ·5 c.c. $\frac{1}{10}$ heated serum, strong hæmolysis.

The results of these experiments amount to the establishment of the existence of a hæmolytic property in weever venom capable of dissolving washed corpuscles of all the bloods so far experimented on without the addition of sera; that the addition of the serum of the same animal does not inhibit but rather increases the activity of the venom; that in most cases heating the serum for an hour to 62° C. diminishes its activating power; that doses of the venom can be activated by the sera of other animals in the case of man, or the corpuscles are rendered more

susceptible to the poison; that probably the poison is an amboceptor which unites with the endocomplements of the blood-cells.

The neurotoxic effects of the poison have not been fully worked out at present as I have been unable to spare the time away from practice, but I am continuing my investigations in this direction and also studying the effect of the venom in relation to bacteriolysis.

Treatment.—The part pricked should be separated from the general circulation by a ligature, and if the lips are not sore the wound should be sucked. The wound should be freely incised and a fresh solution of permanganate of potash, or hypochlorite of lime, or chloride of gold 1 per cent. rubbed into the part. The neutralising effect of the permanganate solution has been proved experimentally and practically by treating successfully recent cases of weever sting by these methods.

November 6th, 1906.

BIBLIOGRAPHY.

1. *Günther.*—"An Introduction to the Study of Fishes," p. 190, *et seq.*
2. 'Cambridge Natural History.'
3. *Bottard.*—'Les Poissons Venimeux.'
4. *Gressin.*—'Contribution à l'étude de l'appareil à venin chez les poissons du genre Vive,' Paris, 1884.
5. *Phisalix.*—"Expèriences sur le venin du Vive," 'Bull. Méd. Paris,' 1899, p. 256, *et seq.*
6. *Briot.*—"Sur l'action du venin du Vive," 'C. R. Biol.,' Paris, liv, 1902, pp. 1169—1198; lv, 1903, pp. 623, 624; lvi, 1904, pp. 1113, 1114.
7. *Evans.*—"Treatment of the Wounds Produced by Weevers," 'Brit. Med. Journ.,' 1906.

---

9. *Lateral fractures of the axis vertebra.*

By EDRED M. CORNER.

IN this communication it is intended to introduce only one example of fracture of the axis, but one which is so dependent upon the position of the bone, as the keystone to the arch, that it must be both an important and a fairly common one. As over fifty per cent. of the collected cases of this fracture presented no

severe symptoms and as about the same percentage recovered spontaneously, it will be easy to understand that unless death happened to occur and an intelligent *post-mortem* examination was made, two contingencies not always found together, the lesion was sure to be overlooked. It may be stated that the cases were brought together to a great extent through visits to the various museums of the British Isles in which the specimens lay buried.

I have suggested the name of "lateral fracture" for this injury as it is descriptive of its position. All mishaps to the keystone of an arch are of first-rate importance to the structure of which it forms part, so lateral fractures of the axis must be paramount amongst the lesions of the vertebral column.

Of the twenty-two cases collected here, eleven have been reported before. The fourth case in the series is published for the first time and is well worthy of study, being about the most remarkable of the series. The cases 13–20 have been collected from the museums of the British Isles, the sources being acknowledged in each case, and are recorded for the first time.

The second vertebra, the axis, is peculiar, differing from the others in its mechanical arrangements. These very peculiarities will make its fractures, which are dependent upon the mechanical arrangements of the bone, peculiar also. Thus far, the question of fractures of the axis is one merely of scholarly or academic interest. But this is no longer so, as recently they have been shown to have considerable clinical and practical importance. In 1903 I brought before the Clinical Society of London a man who had fractured his axis and was then, seven months after the accident, perfectly well.[1] He had never had any paralytic symptoms or suffered from anything more than a stiff and painful neck. Without the X rays the lesion must have been overlooked. Further, I have examined the specimens in the various pathological Museums in the British Islands and the literature, with the result that twenty-two examples of this newly recognised fracture are brought forward in this paper. The most important fact in their clinical history is that there was *no paralysis or anæsthesia in over fifty per cent.* of the known cases. It will follow that in all probability, certainly before skiagraphy, at

[1] 'Clin. Soc. Trans.,' 1904, p. 234.

least half of the cases would be overlooked. Considering this and the simple mechanism of the production of the fracture, it may be said that lateral fractures of the axis will be frequently found in sprained necks. This is important because if the injury is not recognised a fatal result may occur. In Cases 2, 5, and 12 death took place suddenly on the third, seventh, and twenty-first day respectively, whilst previously there had been no paralytic symptoms. The fatal result was produced by the sudden, and perhaps temporary, dislocation of the fragments.

The axis presents several differences in its structure when compared with the other vertebræ. It is quite out of place to enter upon an anatomical description of these peculiarities.

FIG. 19.

An anterior view of the axis, showing the relative positions of the superior articular facets and the body of the vertebra.

But, in so far as the physical or mechanical conditions of the bone are affected, it is necessary to consider their influence upon fractures. All indirect fractures, as they are called, are produced by transmitted violence. When, in fractures of the axis, the force is applied either to the head or the trunk, it is necessary to examine the articular facets of the bone, *i. e.* the points of contact, in order to ascertain the method by which the violence is transmitted to that vertebra from the other segments of the spine. The first fact which such an examination reveals is that the weight of the head rests upon the sides or wings of the axis, whilst the same weight is conveyed to the third vertebra by the body, in the middle line. Hence the axis is like a railway truck the buffers at the ends of which do not correspond in position.

To meet this strain, which is a daily or hourly exercise, buttresses of bone are developed.

FIG. 20.

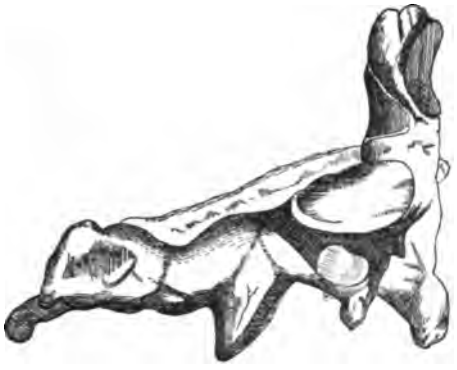

Side view of the axis, showing the opposite inclinations of the body and the inferior articular facets, and also the fact that the superior articular facets have no direct support. (Enlarged.)

If the bone is looked at sideways, it will be noticed that the lower surface of the body is curved, the anterior edge being a good deal lower than the posterior. Consequently the body of

FIG. 21.

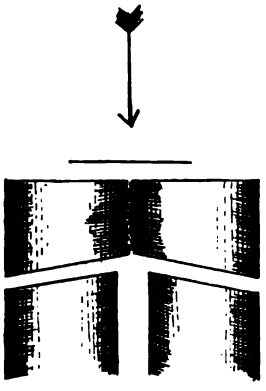

A diagram showing the vertical line of fracture as it occurs through the unsupported part of the axis.

the axis is placed upon an inclined plane which is directed downward and forward. The natural forward inclination of this plane is much increased when the head is flexed. If attention is now paid to the inferior articular surfaces, they will be seen to

be precisely opposite in their inclination, namely downwards and backwards. The superior articular facets are not in corre-

Fig. 22.

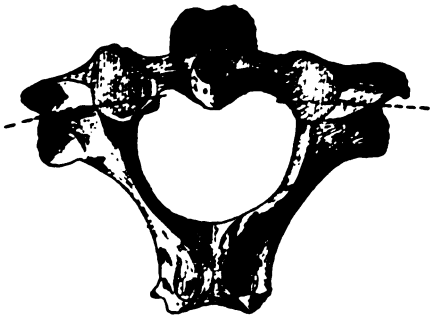

Superior view of the axis, showing the position of the fracture.

spondence with these but are placed between the body and the lower articular surfaces.

Hence, *the axis is supported by the third cervical vertebra upon two oppositely inclined planes which are not continuous with each*

Fig. 23.

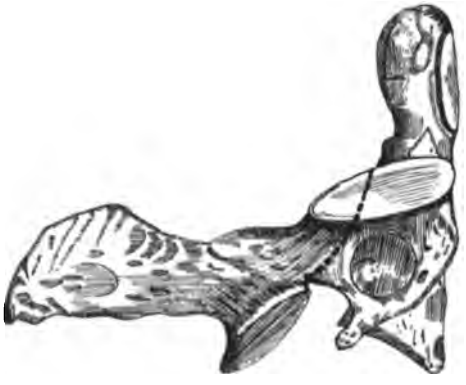

Side view of the axis, showing the course of fracture through the unsupported part. (Enlarged.)

other; and in between them there is a portion which carries the head, unsupported by any structure (Fig. 21).

This unsupported part bears the superior articular facets and is therefore the part whence weight and violence are transmitted to or from the head. Further, this same unsupported arch is

rendered weaker, being split by the canal of the vertebral artery. It is this arch which will and does break when violence is applied to it along the cranio-spinal axis. This is the fracture to which I would direct attention. It is the region most likely to suffer in any accident to the spine. If the pedicles are defined as the bony processes which connect the laminæ and transverse processes with the bodies of the vertebræ, it is a fracture of the pedicles. A specimen, when looked at from above (Fig. 22), shows that the fracture starts in the posterior part of the superior articular facet, opens the carotid canal, and ends by separating the posterior root of the transverse process from the inferior articular surface which is immediately behind (Fig. 23).

Out of the twenty-two instances of this fracture which I have been able to find, seven were the result of hanging. Their production is that violent traction is put, obliquely and in opposite directions, on the inferior articular process and body of the vertebra, breaking the unsupported arch of the axis just as one can snap a bird's merrythought.[1]

CASE 1.—Battle ('Clin. Soc. Trans.,' 1903, p. 232):

A man, aged 56 years, fell down a staircase a month previous to his admission to St. Thomas' Hospital, hitting the back of his head, which was at the time acutely flexed. He had resumed work and continued it for a fortnight. He had a stiff neck, and later there was some pain over the back of the neck and shoulders. The neck was held stiffly and the movements were limited. A skiagraph showed that there was a fracture of the pedicles of the axis. There was no paralysis or anæsthesia. The head was held flexed on the chest. Recovery.

At the time of writing (September, 1906) the man is in St. Thomas' Hospital, with inoperable malignant glands on the left side of his neck. There is no obvious primary growth and it is possible that the glands (sarcoma?) are connected with the fracture.

CASE 2.—Bouvier ('Bull. de l'Acad. de Méd. de Paris,' 1843, vol. ix, p. 344):

A woman, aged 76 years, fell out of bed, head foremost. She complained of pain in the neck, which was rigid, the head being

[1] For "The Lesions which result from Judicial Executions" see 'St. Thomas's Hospital Reports,' 1906.

immovable. The patient sustained her head with her hands. There was slight diminution of sensibility in the left upper limb and occasional embarrassment of speech. Death three days after the accident.

FIG. 24.

A side view of the patient (Case 1), showing the flexion of the head.

Post mortem.—The posterior half of the axis was completely separated from the body. This fracture had evidently taken place in front of the inferior articular processes. The direction of the fracture is transverse from side to side and exactly perpendicular to the bone. On the left side it is immediately in front

of the inferior articular process, the laminæ, and inferior articular processes. It preserved its connection with the third vertebra the posterior part of the atlas, and the body of the axis.

CASE 3.—Corner ('Clin. Soc. Trans.,' 1903, p. 234, also 1905, pp. 212 and 213):

E. T—, aged 50 years, a cabman, was dozing in a chair on a Sunday afternoon and, in nodding, rolled out of his chair into the corner of the room. His head was flexed and there was no great violence. The pain at the time was described as "simply shocking." It was situated high up in his neck. He was assisted to rise, though there was no paralysis or anæsthesia. Having been put to bed, he remained there rather out of expediency than actual necessity. It was not till the fifteenth day that he came to the out-patient department at St. Thomas's Hospital. When seen he was found to have pain and rigidity in the upper part of his neck. He also complained of pain along his right great occipital nerve. A skiagraph was taken by Mr. A. H. Greg which revealed fractures of the pedicles of his axis. He was treated with quiet and rest, followed by massage; he commenced to drive his cab again in about twelve weeks' time. Nearly seven months after the accident he was shown at the Clinical Society. At that time the movements of his head were quite good, but he still complained of curious numb feelings over the area of his right great occipital nerve.

Description of the injury.—The anterior skiagraph of the spine showed nothing. The lateral view showed very distinctly a fracture of each pedicle. That on the right side was displaced a little upwards, so that the ends of the fragments were seen, in the side view, above those of the left pedicle. The fact that the fragments of the broken left pedicle were but little displaced is seen in the obscurity which it leads to in the skiagraph of the lower part of the fracture. The greater displacement of the fragments of the right side explained the injury of the corresponding great occipital nerve. The line of the fracture is as follows: Above, it starts at the outer and posterior part of the superior articular processes of the axis and passes downwards and backwards, to end on the inferior surface of the pedicle just in front of the inferior articular process. The arch of the axis is in consequence completely separated from the body. It is,

however, held in its normal position by the ligaments. The body of the axis can be seen to be displaced a little forwards; this forward movement of the body is checked by the locking of the odontoid process between the anterior arch of the atlas and the transverse ligament, thus saving the man from immediate death. Recovery.

CASE 4.—Corner (St. Thomas's Hospital Museum Catalogue).—Fractures of the atlas, left lateral fracture of the axis, and rotatory dislocation of the right side of the atlas ('Clin. Soc. Trans.,' 1905):

Unfortunately, this most remarkable specimen has no clinical history; but, fortunately, the subject of the injury lived, as is evidenced by the signs of sound repair about the fracture. As a result the bones carry marks which have been engraved upon them by the movements of the neck subsequent to the healing of the fracture. These tell their own tale and enable us to learn something of the history of the accident. The specimen consists of part of the occipital bone and the atlas, the axis being wanting. However, the atlas bears upon it unmistakable signs, articular surfaces, of the condition of the axis.

The *occipital bone* is ankylosed on both sides of the atlas. It is impossible to say whether or no there has been any fracture of the condyles; probably there has not been.

The *atlas* is much misshapen is consequence of fractures which have been completely repaired by bone, ankylosis to the occiput accompanying that repair. A fracture has taken place at the apex of the posterior arch which has not been united by bone. In the region of the right lateral mass there has been a further injury. This fracture has apparently been comminuted, accounting for the great deformity of the lateral mass. The damage to the atlas has been confined to the right side, a point which indicates that the head at the moment of the accident was on the right side, so that all the violence was transmitted to the right condyle. The ankylosis of the corresponding occipito-atlantal joint was a direct consequence of the injury, whilst the ankylosis of the joint of the opposite side was secondary and the result of that on the right.

The fractures of the atlas were two in number. The primary one was in all probability the comminution of the right lateral mass, owing to the right occipital condyle being driven on to it.

On account of the mechanical disposition of the articular surfaces, the same impact would also drive the lateral mass outward and lead to a secondary snapping of the posterior arch, as in the breaking of a bird's "merry-thought."

The condition and disposition of the *axis* can only be inferred by the articular facets on the under surface of the atlas. The left articular facet is markedly smaller than it usually is, and has been covered with cartilage in the recent state. The facet for the odontoid process presents many peculiarities. Instead of being more or less circular, it is much elongated from above downwards, and the process had evidently articulated

FIG. 25.

The specimen in the Museum of St. Thomas's Hospital described in the text.

with the left side of the foramen magnum. Its vertical or long axis is oblique, and quite out of harmony with the left facet just described. Therefore between these two facets there must have been a fracture of the axis, as there is no joint to have become dislocated to give rise to the abnormal disposition of the articular surfaces. Under the large deformed right lateral mass of the atlas, and continuous with the articular surface for the odontoid process just mentioned, is a new facet which must have been an articulation between the atlas and the body of the axis. To the right of this impression there is the place where the right articular facet for the axis should be. This can be traced in outline but the surface has evidently not been covered with cartilage in the fresh state. There must have been a dislocation

here as there has been no ankylosis of the atlanto-axoid joints. To sum up, the articular surfaces on the under part of the atlas indicate that there had been a lateral fracture of the left side of the axis, involving the outer part of the superior articular facet, and there has been a dislocation of the rest of this joint and also of that of the right side. That is to say, *there has been a lateral fracture of the axis with rotatory dislocation of the atlas without causing death or paralysis, as the bones have worn new facets for themselves.*

The dislocation has resulted also in the displacement of the right fragment of the atlas bodily backwards and slightly inwards and the left fragment forwards and outwards. There is also some rotation of the vertebræ on their transverse axes.

A few words must be said as to the possibility of a fracture of the odontoid process having occurred. This seems not an unlikely thing when the presence of the unilateral dislocation of the atlas is taken into account.[1] But there are several reasons to make us think otherwise. In the first place, the process has worn for itself a well-marked facet, which a broken-off process would hardly be expected to do for itself. Such might occur if the fragments united with bone. But it is known that fibrous union occurs in 97 per cent. when this fracture is repaired.[1] Also, the articular facet for the odontoid process is continuous with the new facet for the body of the axis, as has been pointed out above. This continuity of articular surfaces naturally suggests continuity of bony structure, and therefore no fracture. Apparently it has preserved its proper anatomical relationship with the body of the axis, as is shown by the facets. The integrity of the process would, moreover, have a great deal to do with the prevention of instantaneous death, for by locking between the anterior arch of the atlas and the transverse ligament it will limit the displacement of the axis and prevent damage to the spinal cord and its membranes. In this we may compare Lowson's case (8). As there was a left lateral fracture of the axis present, the consequent displacement would save the odontoid process from fracture.

At the meeting of the Clinical Society of London at which this specimen was shown to illustrate some living cases it was suggested that the fractures and displacements were the results of

[1] 'Med.-Chir. Trans.,' 1907.

disease and not of the healing of an injury. The lesions, however, are so uniform with those found in the atlas and axis as the result of trauma that the author has not seen reason to change his opinion.

CASE 5.—Delbet ('Bull. et Mém. Soc. de Chir.,' Paris, 1900, 47):

A female, aged 59 years, fell downstairs. She was taken to the hospital three days later and was found to have a fracture of the left radius, another of the surgical neck of the left humerus, and violent pains in the nape of the neck. A diagnosis of lateral dislocation of the atlas and axis was made. There were no paralytic or anæsthetic symptoms. Death on the seventh day.

Post mortem.—The fracture was found to be in the right lamina of the axis, at the point of union between that lamina and the articular process.

CASE 6.—Francis ('Brit. Med. Journ.,' 1886, vol. i, p. 116): Fracture of the atlas with lateral fractures of the axis.

A man, aged 50 years, fell twenty feet backwards off a ladder, striking the back of his head against a plank. There was pain on rotation of the head, paralysis of the upper limbs and the left lower limb. For a time he made steady progress; then pains appeared in his joints, with effusion into the right knee. Complete paralysis followed and death. Death on the twenty-seventh day.

Post mortem.—The posterior part of the ring of the atlas was broken off. The axis was also fractured. The line of fracture passed through the posterior parts of the atlanto-axial articular surfaces, between the pedicles and the body of the vertebra. The arch was quite separated from the body. There was no displacement or sign of repair.

CASE 7.—Milner ('St. Bart.'s Hosp. Reports,' 1874, vol. x, p. 315): Fractures of the atlas, with lateral fracture of the axis.

A man, aged 38 years, fell from the top of a house, a distance of seventy feet. Death was instantaneous.

Post mortem.—On making an incision over the spinous pro-

cesses of the cervical vertebræ there was found a complete dislocation of the occipital bone on the atlas. All ligaments which connected this and the axis with the occiput were torn across. The superior articular surfaces of the atlas were uninjured, but the posterior arch, where it joins the lateral masses on either side, was broken transversely. There was no dislocation between the atlas and the axis. There was a fracture of the axis, commencing at the posterior part of the superior part of the articular process, descending downwards and outwards nearly to the posterior inferior angle of the inferior articular surface, the portion of bone not being quite detached. The medulla oblongata and both vertebral arteries were divided. There were multiple severe injuries to the abdominal viscera.

Case 8.—Lowson ('Med.-Chir. Trans.,' 1885, vol. lxviii, p. 135): A man, aged 65 years at the time of the accident, in the dark fell into a well six feet deep. He lay unconscious for some time and when he recovered complained of excruciating pains in the neck and that movements of the head caused agony. Rotation of the head was not impossible, but limited and painful. The chin was tilted upwards and the occiput depressed. The mouth was kept open and all respiration was oral. The swallowing of solids was difficult. On examining the throat, the soft palate and uvula were seen to be pushed forwards by a tumour projecting from the posterior wall of the pharynx. The apex of this mass resembled the projecting lip of a cervical vertebra. No paralysis. Death from other causes ten years later.

Post mortem.—The axis and the odontoid processes were bent backwards at an angle of 60° with the horizon. There was complete ankylosis between the bodies of the second and third vertebræ, with the exception of a small angular interval the front of which was filled with the remnant of the intervertebral disc. The arch of the axis overlapped, enclosing that of the third vertebra, and was ankylosed to it. The upper articular processes of the third cervical vertebra were merged in the pedicles of the axis. The lower articular processes of the axis were widely separated from the transverse processes and situated on a level with the corresponding processes of the third. The atlas showed two anomalies: (1) there was a foramen instead of a

groove for the vertebral artery, and (2) a bony process projected from the posterior arch to rest on the root of the spinous process of the second.

In accounting for the mode in which the injuries had occurred, it seems probable that in falling the vertex came first in contact with the ground and the impetus of the trunk impacted the upper articular processes of the third vertebra into the second. The trunk then, falling backwards, doubled up the neck and burst the anterior common ligament and drove the body of the axis forwards and so gave the odontoid process the tilt.

One half of the specimen is at Leeds and the other at Aberdeen (Aberdeen University Pathological Museum Catalogue).

692, Professor Ogston's Collection: "The line of fracture was through the posterior part of the upper articular processes of the axis and probably also through the laminæ of the same bone." Yorkshire College, Leeds, Pathological Museum Catalogue, A 81.

CASE 9.—Professor Paterson ('Journ. Anat. and Physiol.,' 1889–1890, vol. xii):

From a case of judicial suspension. The axis was fractured through the pedicles, causing separation of the arch from the body and the odontoid process; on the left side the transverse process was broken off. The transverse processes of the third cervical vertebra were broken, that on the left side only incompletely. There was a dislocation between the second and the third vertebræ.

CASE 10.—Picou ('Bull. de la Soc. Anat. de Paris,' 1894, vol. lxix, p. 873):

A man, aged 52 years, whilst seated on the box of a carriage had an attack of vertigo and fell, head foremost. The arms and shoulders were painful, the muscles of the neck contracted. Rotation of the head was possible; flexion and extension were painful. There was a depression along the spinous processes of the neck, and there was a projection in the pharynx indicating a displaced vertebra. There were urinary, respiratory, and motor "troubles." Death three and a half days after the accident.

Post mortem.—The ligaments between the occipital bone, atlas,

and axis were intact. The two first vertebræ were found closely united together by their fibrous bands; but the inferior face of the body of the axis was completely detached from the intervertebral disc between it and the third cervical vertebra and fractured transversely. The anterior common vertebral ligament was torn completely across between the axis and the third vertebra. A portion of the subaxoid intervertebral disc remained adherent to a "beak" of the axis. The fibrous capsules of the articular processes of the axis and the third vertebra were torn on both sides. The atlas had a bilateral incomplete transverse fracture of its posterior arch. It also had a transverse incomplete bilateral fracture opening below and dividing the axis into two parts; the anterior one comprised the body with the odontoid process intact, the right superior articular facet, and the anterior two thirds of the left. The posterior one consisted of the left transverse process, the two inferior articular processes, the laminæ, and the arch with the spinous process. The right transverse process, of which two roots were fractured, was completely detached from the rest of the vertebra.

Case 11.—Wyman ('Boston Med. and Surg. Journ.,' 1862, vol. lxv, p. 333):

The bones were taken from a dissecting-room subject and nothing was known of the history.

The first four cervical vertebræ, the second, third, and fourth were ankylosed with each other, and the following abnormalities were noted: A part of the body of the axis, with the odontoid process, the whole of the (superior) articulating surface of the left side and a large portion of the right had been detached from the arch, carried obliquely forward, depressed in front of the third vertebra, and ankylosed with it. The line of the separation, though obscured by subsequent changes in the surface of the bone, appears to have been from above downwards obliquely forwards through the body of the bone, through the left pedicle just behind the foramen for the vertebral artery, and on the right side through the hinder part of the articular process, leaving the foramen for the vertebral artery in connection with the arch behind it. The base of the odontoid process was in front and on a level with the body of the third vertebra. The body of the axis, when seen in front, has its natural texture, but

is continued downward by a thick accidental ossific deposit and is ankylosed with the front of the fourth vertebra, which is mostly concealed by it. The arch of the axis remains in its natural position, and is ankylosed with the third vertebra by means of its articular processes. The space corresponding with the intervertebral foramen is bridged over by adventitious bone. Behind the odontoid process the remaining portion of the obliquely truncated body of the axis is seen in its natural position. The foramen for the vertebral artery in the axis on the left side, instead of being above that of the next vertebra below, is in front of it, but is in its natural position on the right side.

The atlas presents several abnormal conditions. Its upper articulating surface on the left is polished from direct contact with the condyle of the occipital bone. The arch is not closed up posteriorly, as if from the effects of disease (fibrous union of a fracture); on the under edge of the arch there exists on each side an accidental articular surface corresponding with similar ones on the upper edge of the axis, where the two bones had rubbed on each other. These "false" articulating surfaces are in the direct line of the true ones below. When placed on the axis, the atlas is in advance of its natural position, in consequence of the odontoid process having been carried forwards, and its arch, instead of being just above that of the axis, overhangs that of the spinal canal and thus very materially diminishes the diameter of it. Sufficient space is left to lodge the spinal cord without compression, but not enough to admit of freedom of motion.

Case 12.—Gayet ('Mém. de la Soc. de Sci. Méd. de Lyon,' 1870, vol. x, p. 8): Lateral fracture of the axis, fractures of the atlas and odontoid process.

A woman, falling downstairs, clutched at a support and stopped herself with a jerk. Afterwards she complained of pain in her neck and had to support her head with her hands. Three weeks later there was a distinct prominence of the spine of the axis. One night on attempting to rise from bed she fell and immediately became paralysed. Death three weeks after the accident.

Post mortem.—There was a fracture of the left lateral mass of the atlas, another of the right lateral portion of the axis; the

odontoid process was broken off at its base. The axis was carried forward, compressing the cord.

CASE 13.—St. Thomas' Hospital Museum Catalogue:

188. The cervical vertebræ, wanting the atlas. The axis is fractured on each side through the upper articular processes, and the fractures involve the foramen for the vertebral artery and apparently detach the arch from the body of the vertebra. The intervertebral substance and the articular ligaments between the axis and the third vertebra are ruptured. The spinal cord was crushed at this situation. The spinous processes of the sixth and seventh cervical vertebræ have also been detached in the fracture.

Obtained by the late Mr. Le Gros Clark in 1885 from a woman, aged 58 years, who died on the fourth day, quite suddenly, after an accident. She had also a fractured base of her skull and lower jaw.

CASE 14.— University of Cambridge Pathological Museum Catalogue: Fractures of the atlas and lateral fractures of the axis.

1334 A. Fracture of the atlas through both sides of its arch. Fracture of the axis through both sides, traversing the hinder parts of the upper articular facets and passing in front of the lower articular facets. The anterior and lower part of the body of the axis is broken off.

History.—From a man, aged 50 years, who fell from a hay-stack on to the back of his head. At first there was nearly complete paralysis of the limbs, though not of the thumb muscles. The paralysis to a great extent subsided but returned again later. He became feverish and died five weeks after the accident. There was a small abscess at the base of the skull and another amongst the muscles of the back; the latter was not connected with the fracture.

CASE 15. — Trinity College, Dublin (Pathological Museum Catalogue. Judicial Series):

(1) *Atlas,* no lesion. Lateral fracture of the axis.

Axis.—The left transverse process removed in such a manner

as to leave intact the canal for the vertebral artery, except for a small portion near the junction of the anterior and posterior root. The tubercle, with nearly the entire extent of the inferior aspect of the anterior and posterior roots, was removed, the line of the fracture being obliquely upwards and outwards. The third and fourth vertebræ were fractured and separated from each other.

CASE 16.—Trinity College, Dublin: Fracture of the axis.

(2) *Atlas.*—The right transverse process had its anterior root removed close to the lateral mass and again at the junction with the posterior root, laying open the canal for the vertebral artery on its lateral aspect.

Axis.—The right transverse process had its extremity broken off, but the fracture did not extend into the canal or the vertebral artery. The posterior root of the transverse process was broken from its junction with the pedicle and the inferior articular process. The anterior root of the transverse process was fractured at the junction of the superior articular process and the body, but still remaining adherent as far as union with the posterior root. The canal for the vertebral artery was opened on its lateral aspect. The third and fourth vertebræ were also fractured. Dislocation had taken place between the axis and the third vertebra.

CASE 17.—Trinity College, Dublin: Lateral fracture of the axis.

(3) *Atlas.*—No fracture.

Axis.—The left transverse process had been broken so as to open the canal for the vertebral artery posteriorly. There was a fracture through the left pedicle close to the body; there was also a similar fracture through the right pedicle.

Third, fourth, and fifth vertebræ were also broken. Dislocation had taken place between the axis and the third vertebra.

CASE 18.—St. Mary's Hospital Museum Catalogue:

113. The arch is separated from the body of the bone by a fracture on each side situated between the superior and inferior articular facets. From a criminal who had been hanged. Presented by Mr. Edmund Owen.

CASE 19.—University College Museum Catalogue:

160. An axis separated into two parts by a fracture passing through the left superior articular surface of the left side and the posterior extremity of the lamina of the right side. From a woman aged 39 years who was found dead at the bottom of a flight of fourteen stairs. There were no other fractures.

CASE 20.—The London Hospital Museum Catalogue:

207 A. The laminæ of the second cervical vertebra have been detached from the body by a vertical fracture which, on each side, has passed through the superior articular process, leaving the anterior three quarters in connection with the body. This fracture gapes on each side to the extent of a quarter of an inch, the laminæ being on a lower plane than the body. The laminæ of the third cervical vertebra are similarly broken, but through the pedicles. The intervertebral discs between the third and fourth vertebræ were ruptured.

It has been possible to obtain details of portions of the clinical histories of fourteen of the twenty cases. Of these, seven were males and five were females. Nine were over fifty years of age, the oldest being a woman aged 76 years. Only two were known to have been under fifty and their ages were thirty-eight and thirty-nine respectively. In eight, over 50 per cent. of the cases, there was neither paralysis nor anæsthesia; in three, paralysis occurred and in three death was instantaneous. Five recovered and nine died; in three cases, which had had no nervous symptoms, death occurred very suddenly. Of those who died, in three cases it was instantaneous: one died on the 3rd, 4th, 7th, 21st, 35th, and 37th days respectively. In every known case, except those due to hanging, the violence was applied to the head, in far the majority of which it was applied to the back of the head. In eight cases the fracture was bilateral; in five it was unilateral and on the right side. In two more cases the skiagraphs make it appear that the fracture was on both sides. In four instances the fracture of the axis was accompanied by a lesion of the atlas which was twice a fracture, once a fracture with rotatory dislocation, and once it was complicated with fracture of the odontoid process. *To sum up, lateral fractures of the axis occur in people over fifty, are usually bilateral; only* 50 *per cent. show any spinal cord symptoms;*

nearly 70 *per cent. recover; the violence is always indirect and is usually applied to the back of the head.* Beyond these few statistical points, clinical details are lacking, in spite of the fact that five cases recovered. But in Wyman's and the author's second case the injury was only discovered *post mortem* many years after the accident. The chief symptoms of the injury are pain and rigidity of the neck. In both Battle's and the author's first case the head was flexed. In Lowson's case it was extended. In all, the original limitation of movement has gradually passed away, but not always completely. In the author's first case (Case 3) the man complained of curious numb feelings over the distribution of the right great occipital nerve. This nerve is situated immediately behind the superior articular facets of the axis and may be easily included in the callus uniting the fragments. Hence a lesion of the axis may be looked for in cases of intractable neuralgia of this nerve.

Of the five who recovered, in two the injury was discovered by chance after death, one was examined after death had occurred ten years later from epithelioma of the jaw, and two are alive and well. These cases make it very probable that there are a number of undetected instances of this fracture and that it is more frequent than is thought. Considering its simple mechanical production and the absence of severe symptoms in over 50 per cent. of the cases, it will be found to be a common lesion in injuries of the neck.

In connection with this statement a case of great interest has been placed at my disposal by Mr. Wagstaffe, formerly one of the surgeons attached to St. Thomas' Hospital. As it occurred in 1887 no skiagraph was taken, under which circumstances the exact nature of the injury must remain doubtful, the man having recovered. But it may well have been a lateral fracture on each side of the axis which separated the posterior arch from the body of the bone.

J. H—, a labourer, aged 45 years, when eleven years old fell about ten feet on to his head. He was picked up unconscious and "as one dead." His head was twisted to one side and was placed straight by a workman. After recovering from his unconsciousness he did not go to bed or lay up in any way. But for two years afterwards a bone in his neck was frequently seen

to slip out in the middle line of his neck just below the occiput. Until it was replaced he could neither breathe nor speak. Two years later he was quite well except that when he stooped he had pain and numbness in both legs In time this cleared up until he fell two feet from a plank shortly before he was seen by Mr. Wagstaffe. Then he had bruised his left shoulder and his old spinal cord symptoms had returned. This time his hands were affected, as well as his legs, with pain and numbness whenever he stooped.

The bladder was unaffected. The second cervical spine was noticed to be prominent and when tapped the nervous symptoms could be reproduced. Steady pressure on the spine did not do so. His neck was treated with a splint and he gradually recovered.

In the light of the knowledge gained from an examination of the proved cases of lateral fracture of the axis, Mr. Wagstaffe's case may have been an example of the injury which was followed by recovery. The diagnosis made by him was "fracture of the second cervical vertebra with concussion of the spine." But the spinal cord symptoms may have been due to stretching rather than to true concussion. As the discussion of this point is without the subject of the present communication, the reader must be referred to my paper in the 'Lancet,' September 22nd, 1906.

In conclusion, I have great pleasure in offering my thanks for the kindness and courtesy which were extended to me by the curators of the various museums visited or written to in the course of my inquiry.

To this paper are appended two more examples of lateral fractures of the axis. They were obtained from criminals who suffered the extreme penalty of the law. As they have no clinical bearings, the substance of the paper has not been altered to include them.

Capital Sentences Commission, 1886.

(1) There was a complete separation between the second and third cervical vertebræ. The spinal cord was severed. The axis sustained fracture through its left pedicle at the margin of the superior articular facet and through the posterior arch of the canal of the vertebral artery, accompanied by downward displacement of that side. The tip of the transverse process of the

left side was broken off. On the right side there was an imperfect fracture of the pedicle at its junction with the superior articular facet.

(2) The dislocation was between the second and third vertebræ. The axis had sustained a fracture through the canal for the vertebral artery on the left side. The tip of the transverse process was also separated. On the right side, the transverse process was broken off but there was no fracture into the vertebral canal.

The tips of the transverse processes of the fourth cervical vertebra were also broken off.

The following references are added as the subject-matter of the paper has been mentioned in this communication:

"The Regional Frequency of Fractures of the Spine," 'St. Thomas's Hosp. Rep.,' 1905, vol. xxxiv.

"The Lesions which Result from the Execution of Criminals," *ibid.*

"Dual and Distinct Fractures of the Spine," *ibid.*

"Spinal Concussion, with some Remarks of Concussion in General," 'Lancet,' September 26th, 1906.

"Fracture of Both Pedicles of the Axis," 'Clin. Soc. Trans.,' 1904, pp. 112–114.

"Five Cases of Recovery, without Spinal Cord Symptoms, after Severe Injury to the Neck," *ibid.*, 1906, vol. xxxix, pp. 212, 213.

"Rotatory Dislocations of the Atlas," 'Annals of Surgery,' 1907.

"Rotatory Subluxation of the Atlas," 'Clin. Soc. Trans.,' 1907.

"Fractures of the Odontoid Process of the Axis," 'Med.-Chir. Trans.,' 1907.

December 4th, 1906.

---

10. *On the origin and differentiation of the red blood-corpuscles in mammals.*

By C. E. Walker.

(With Plates I and II.)

De erythrocytorum origine apud mammalia.

(Cum tabulis I, II.)

Summarium.

Leucocytorum quorundam in nucleis (in ossium

medullâ) discernuntur phenomena quæ cum illis in nucleis cellularum testiculi animalium diversorum repertis comparari possunt.

Ut de his sic de illis dubitari non potest quin degenerationis effectus repræsentent.

Dum leucocytorum nuclei, in ossium medullâ, degenerant, hæmoglobinum in cellularum cytoplasmate apparet.

Granula in serie disposita in cytoplasmate cernuntur; hæc granula per rimas membranæ nuclearis parvas transire videntur.

Hoc phenomenon in erythrocytis discerni potest apud Amphibia, quum moriuntur cellulæ postquam ab animali auferuntur.

Aut hoc modo aut membranæ diruptione nuclearis, erythrocytorum nuclei destruuntur.

Post cellulæ mortem solum accidit extrusio nuclei totius.

In ossium medullâ erythrocyti permulti granula, nucleorum diruptorum residua, continent.

Paucis in erythrocytis hæc granula postquam cellulæ in sanguinem jacentur perstant.

In erythrocytis apud Axolotl centrosomata normaliter inveniuntur, duo nonnunquam, sæpius autem plura.

Nonnunquam reperiuntur, insuper, centrosomata in leucocytis illis ex quibus erythrocyti oriuntur; hæc dum nuclei dirumpuntur persistere possunt.

In medullâ mutantur erythrocyti ut formam convexo-concavam acquirant.

In leucocytis illis ex quibus erythrocyti oriuntur chromatini particularum numerus definitur, — pars quattuor, videlicet, chromosomatum quæ in cellulis somaticis animalis ejusdem reperiuntur.

Among the leucocytes[1] found in the bone-marrow of mammals is a numerous class the members of which differ from the other cells in their smaller size, in being generally more or less spherical in shape, and in possessing a single large and rounded nucleus. The nuclei are large in comparison to the size of the cells, and each of them contains a number of masses of chromatin connected to each other by strands of linin containing chromatin granules (Figs. 1–3).

If several such cells be examined carefully, it is found that the number of chromatin masses, where it is possible to count them, is fairly constant, and amounts to one quarter of the number of the chromosomes exhibited by the dividing cells in the soma of the same animal. The possible significance of this apparently constant number will be dealt with later.

A careful study of these cells shows that the condition of the chromatin and linin seems to vary by almost insensible gradations until the nucleus presents quite a different appearance (Figs. 4–7). The chromatin masses in such cells appear to coalesce, and the linin tubes to become thicker and to contain more chromatin, the nucleus presenting the appearance shown in Fig. 7. In other cells the chromatin masses and the linin with its contained chromatin, seem to be losing their sharply defined appearance, until we arrive at a condition where the nucleus stains more darkly throughout than was the case in the earlier stages, and contains only irregular and ill-defined masses of chromatin and but slight traces of the linin (Figs. 8–10).

Up to this point the gradual changes in the nucleus run parallel with what happens in certain cells in the testes of mammals and Amphibia, which are, without any doubt, in process of degeneration. In the testis of Triton, for instance, it is possible to trace with the greatest accuracy the sequence of events in the different generations of cells. Without this parallel it would probably have been impossible to interpret the varying condition of the nuclear contents in the leucocytes of the bone-marrow as being stages in a process of degeneration. (Cells from the testis of Triton containing such degenerating nuclei are shown in Fig. 33, for the purpose of comparison.)

[1] Here, as upon a previous occasion ("Observations on the Life History of Leucocytes," 'Proc. Roy. Soc.,' B, vol. lxxviii, 1906) the term "leucocytes" is used in the widest sense, and is intended to include all the wandering nucleated cells and their immediate ancestors.

From cells containing nuclei in the condition shown in Fig. 10 it is possible to pass, again by almost insensible gradations, to cells where the nucleus is apparently almost homogeneous in structure (Figs. 11 and 12).

While the condition of the contents of the nucleus has been undergoing these alterations, certain changes have also taken place in the cytoplasm. In a few of the cells where the nuclei have not advanced very far in the process of degeneration (Figs. 8 and 9), the cytoplasm is seen to contain a certain amount of hæmoglobin. As the later stages described as occurring in the nucleus are reached so does the number of cells containing hæmoglobin, and the amount of hæmoglobin contained by them, increase. At the stage where the nuclei are apparently almost homogeneous the cytoplasm contains a relatively large amount of this substance.

In a small proportion of these cells a careful search will reveal the presence of centrosomes, and in the later stages of the degeneration of the nucleus these seem to hypertrophy and even occasionally to divide, so that one sometimes sees three, four, and even more, joined by minute threads (Figs. 4, 5, 7, 9, and 12).

Sometimes, particularly in the neighbourhood of a number of unmistakable red corpuscles, cells are found in the bone-marrow which, having reached the later stages described above, exhibit branching strings of granules, generally starting from the nucleus (Figs. 8–12). These are apparently identical with the strings of granules described elsewhere[1] that appear in the red corpuscles of Amphibia, reptiles and birds, during the process of disintegration. It will suffice to say here that while in the red corpuscles of Axolotl the cytoplasm is quite clear when the blood is first removed from the body of the animal (Fig. 34), after the lapse of a certain period of time, what have been interpreted as strings of chromatin granules connected by or contained by linin, appear, which seem to proceed from small breaks in the nuclear membrane (Fig. 35). In the red corpuscles of the crocodile the strings of granules seem to make their appearance in a shorter time, while in the pigeon it is either impossible to get the blood under observation quickly enough to avoid the appearance of

[1] Ross, Moore, and Walker, "On the Existence of Centrosomes and other Structures in the Red Blood-corpuscles of Vertebrates." 'Path. Soc. Trans.,' 1907.

these strings of granules in some of the red corpuscles, or some of the corpuscles are in this condition normally in the blood-stream (Figs. 36, 37, and 38).

The changes in the nuclei of the red corpuscles of Axolotl as they are dying are parallel with what happens in the degenerative cells of the testis of Triton, and in those leucocytes in the bone-marrow of mammals that have just been described. In the crocodile, many of the nuclei of the red corpuscles seem to be normally on the road to degeneration, while in the pigeon they seem to be always in this condition when free in the blood-stream.

Occasionally a cell is seen in the condition shown in Fig. 13.[1] Here the nuclear membrane would seem to have given way and the nuclear contents to be in process of distribution into the cytoplasm. Cells in this condition are, however, comparatively rare, and it is probable that the nucleus is often disintegrated by the oozing out of its contents through smaller breaches in the membrane, as apparently takes place always to a certain extent in the red corpuscles of Amphibia, reptiles and birds, while they are dying. It is possible that what are apparently the strings of granules in the red corpuscles of mammals which are about to be described may upon further investigation prove to be shreds of nuclear membrane in some cases.

The ejectment of the whole nucleus *en bloc* from the cytoplasm of the cell has been described as the manner in which the mammalian red corpuscle normally gets rid of its nucleus. The present investigations indicate that while this happens very frequently in certain *post-mortem* conditions, it does not happen normally in the body of the living animal. If fresh bone-marrow be crushed under a cover-glass and watched, it will be seen that after the lapse of a considerable period of time, which will vary according to the temperature of the room and certain other conditions, many of the nucleated red corpuscles certainly do eject their nuclei bodily. Nuclei may be seen at the periphery of the cytoplasm (Fig. 23), half way through, and attached to the margin of the cytoplasm (Fig. 24), but no

[1] All the previous observations are best made upon tissue fixed within a few seconds after removal from the body of the animal. This stage, however, shows best with the fresh marrow crushed under a cover-glass, with a drop of polychrome methylene blue dissolved in water.

trace of this phenomenon is to be found in marrow that has been fixed immediately upon removal from the body of the animal, nor in fresh marrow for some time after removal.

Even a cursory examination of the red corpuscles in the bone-marrow will show that a very large proportion of them contain strings of granules in varying quantities. In some there seems to be a quantity that would be sufficient to make up the nucleus, while in others there are but a few small strings. (Figs. 14–22.)

These branching strings of granules, when regarded in the light of the preceding observations, would seem to consist of chromatin and linin. In the blood of mammals, as has been stated elsewhere,[1] red corpuscles containing branching strings of granules are found, but they are comparatively scarce. In normal human blood, for instance, only about 1 per cent. exhibit this "chromo-linin" granulation (Figs. 25 and 26). It would therefore appear that normally the granulation vanishes in the great majority of the red corpuscles before they are thrown into the blood-stream. For, in the bone-marrow hundreds of them may be seen close together, all exhibiting these strings of granules (Fig. 39).

Some further changes in the red corpuscles may be observed in the bone-marrow after they have lost their nuclei. In the fresh condition when the marrow is crushed under a cover-glass with a drop of polychrome methylene blue solution many of them are seen to be normally almost perfect spheres. They are, however, plastic to an almost incredible degree, squeezing, under the action of the currents produced by pressure and other causes, through the most minute spaces between leucocytes that have adhered to the glass. In specimens of bone-marrow that have been fixed and cut in sections the result of the plasticity is, apparently, that the red corpuscles that have not been completely differentiated are pressed as they lie among the other cells into the various shapes (Figs. 21, 22, and 39). As will be seen in the figure, while they lie in such a position they almost invariably contain strings of linin which may or may not contain granules of chromatin. Later they appear to be arranged in regular lines, losing their plasticity to some extent and assuming a more or less concavo-convex shape (Fig. 40).

In fixed preparations of bone-marrow the staining reaction of

[1] Ross, Moore, and Walker, *loc. cit.*

EXP[illegible]

[illegible] the [illegible] | W[illegible]
[illegible] Ob[illegible] | [illegible]
[illegible] Mammals

[illegible]

Ad di[illegible] | **[illegible]oud [illegible]**

[illegible] | [illegible]
[illegible] | [illegible]
[illegible] | [illegible]

[illegible]
[illegible]
[illegible]
[illegible]
[illegible]
[illegible]
[illegible]
[illegible]
[illegible]

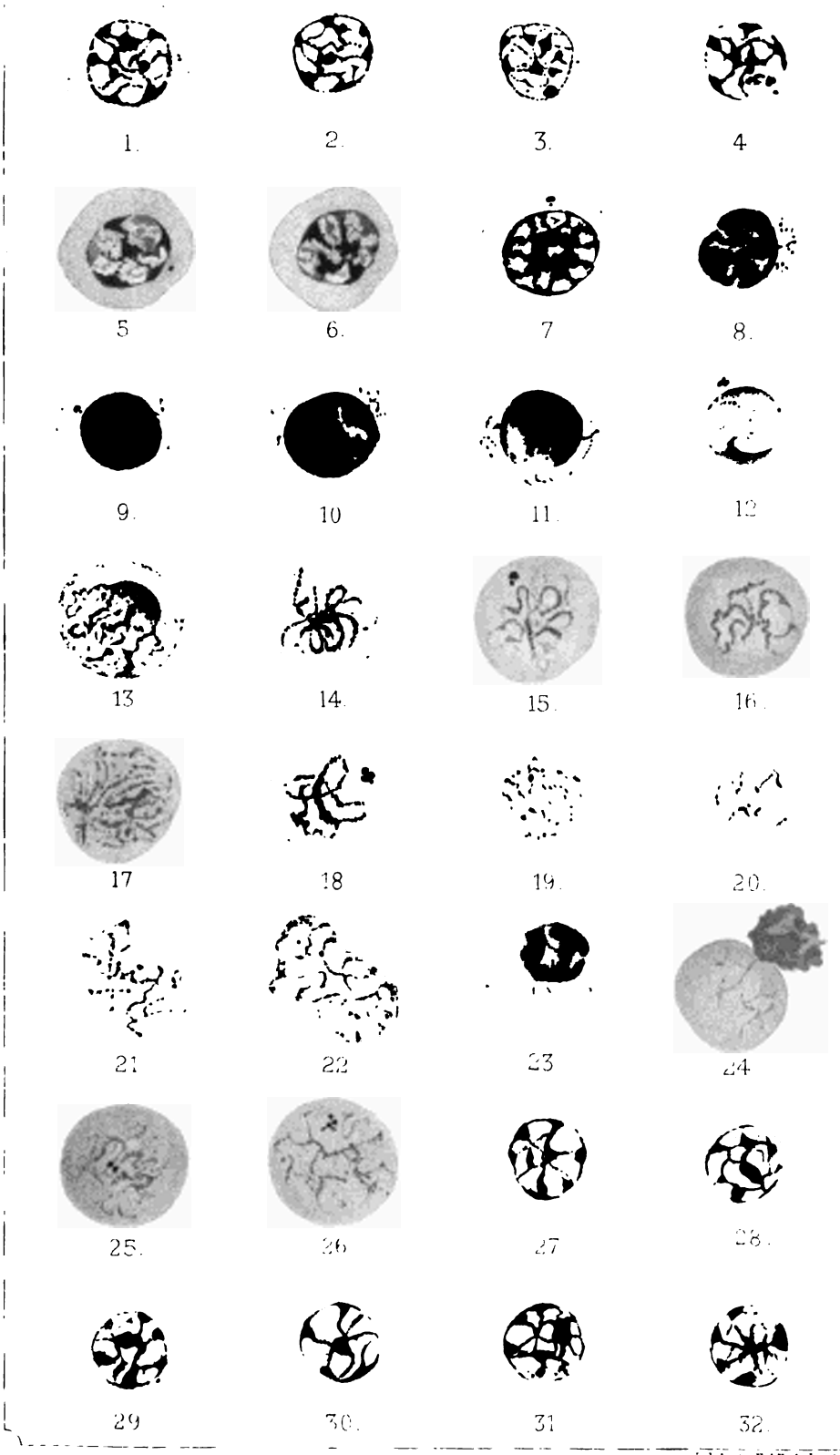

Lith. Anst. v. E. A. Funke, Leipzig

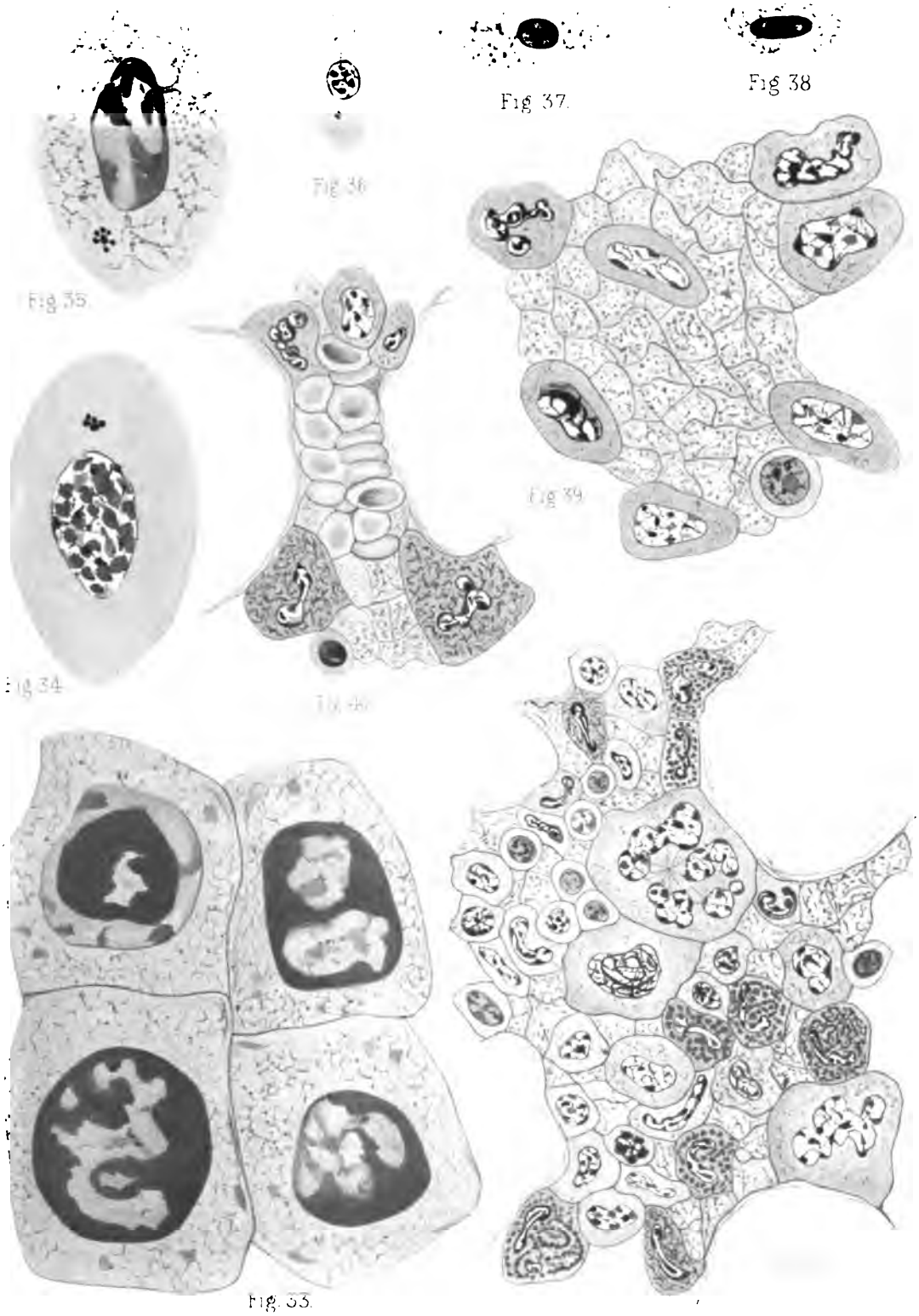

Lith. Anst. v. E. A. Funke, Leipzig.

the strings of granules seems to vary. In what are apparently the earlier stages—that is, shortly after the disintegration of the nucleus—the linin tubes or threads seem to contain a relatively large number of granules which stain with the more basic dye. Later on the amount of chromatin seems to decrease until in the majority the strings seem to consist of linin alone, and to stain with the less basic of two basic stains or with the acid if a basic and acid stain are used.

In the red corpuscles of Axolotl centrosomes are apparently always present (Figs. 34 and 35). They are, when the blood mixed with polychrome methylene blue is examined in the fresh condition, one of the most striking features of the corpuscle. They are sometimes two in number, but more often there are more than two, and they are frequently joined together by minute filaments. They seem to be hypertrophied, for they are usually much larger than is the case with centrosomes in other cells. Centrosomes are also present in some of the red corpuscles of reptiles and birds, and it has been seen that they are to be found in the cells which eventually become converted into red corpuscles in mammals. Apparently the centrosomes persist in a small proportion of those corpuscles in the blood which exhibit the "chromolinin" granulations (Figs. 25 and 26).

It would seem, then, that the red corpuscles in mammalian blood are derived directly from that particular class of leucocytes described at the beginning of this communication. It is, however, advisable to point out here that some mistake may have been made with regard to the exact sequence of events. The cells found in the bone-marrow do not seem to be arranged in any kind of order, and there is no suggestion from their relative positions of one kind having anything to do with any other. The extraordinary jumble of all the different kinds of cells indicates that various processes of differentiation are taking place and various generations being produced, without any apparent regard to position (Fig. 41). In the complicated cell changes taking place during spermatogenesis in those mammals in which the process has been described, where the exact sequence of events is often extremely difficult to follow, a valuable check was available, for it was possible to compare the stages with similar stages in the testis of Amphibia. In the testis of Triton, for instance, the whole process of spermatogenesis is started afresh every year

from a few resting cells, and by examining the testis at intervals it is possible to trace the changes that take place in each succeeding generation of cells with the greatest certainty and to place them in the exact order in which they normally occur. In the present instance there is no similar series of changes in which the exact sequence of events is known with which it is possible to make a comprehensive comparison. Those comparisons of which use has been made, when taken together, cover the greater part of that series of changes which is here described as ending in the complete differentiation of the red blood-corpuscles, but the same can hardly be claimed for any individual comparison. The task of tracing a long series of changes in cells where many different stages are inextricably mixed together, with no other guide than the relative appearance of their nuclei and other constituent parts, would be almost impossible; even with such comparisons with similar series as were available in this case it is possible, as has been said before, that some errors may have crept in.

It was stated at the beginning of this communication that in the nuclei of that class of leucocytes from which the red corpuscles are apparently derived there are usually to be found a fairly definite number of chromatin masses, this number being one quarter of that of the somatic chromosomes observed in the same animal. The only other cells in which the chromatin masses have been observed to occur in this proportion to the somatic number of chromosomes is in the very early prophase of the first maiotic (heterotype) division.[1] In view of the fact that the maiotic phase (reduction) has been described as taking place among the leucocytes in mammals,[2] and of the probability that the various kinds are only different generations of cells derived from the same immediate ancestors, the occurrence of this particular number of chromatin masses is particularly interesting.

Cells which are indistinguishable from the leucocytes here described as giving rise to the red corpuscles, form a large proportion of the cells in the spleen and the majority of those in the lymphatic glands (Figs. 27–32). In the lymphatic

[1] Moore and Walker, "On the Maiotic Process in Mammalia," 'Thompson Yates Reports, University of Liverpool,' 1906.

[2] C. E. Walker, "Observations on the Life History of Leucocytes," 'Proc. Roy. Soc.,' B, vol. lxxviii, 1906.

glands, however, the number of chromatin masses does not seem to be very constant, and even in the spleen not constant to the same extent as in the bone-marrow. Whether these cells, if thrown into the blood-stream, proceed to differentiate along different lines to those that some of them, at any rate, follow in the bone-marrow is a matter for further investigation. In the germinal areas of lymphatic glands they frequently divide mitotically, apparently often exhibiting the post-maiotic (reduced) numbers of chromosomes.[1] This, again, is most suggestive, but it is impossible at present to draw any definite conclusions therefrom.

The conditions of the nuclei in these cells, and the number of the chromatin masses they contain when in the blood-stream, remain to be ascertained.

Note.—These observations are possible only in the case of very well preserved material, and attention is suggested to the remarks upon this matter in the note following the communication "On the Life History of Leucocytes," 'Proc. Roy. Soc.,' B, vol. lxxviii, 1906. The stains used were thionin and Bordeaux red, basic fuchsin and orange G, saffranin and toluidin blue. The latter combination gives a very fine differentiation in the case of the degenerating nuclei. *December 18th*, 1906.

---

11. *On the existence of centrosomes and other structures in the red blood-corpuscles of vertebrates.*

By Ronald Ross, C.B., F.R.S., J. E. S. Moore, and C. E. Walker.

(With Plate III.)

De centrosomatibus et structuris aliis in erythrocytis apud animalia vertebrata.

(Cum tabulâ III.)

Summarium.

In animalium vertebratorum erythrocytis (includitur homo) granula quædam reperiuntur quæ centrosomata et nucleorum residua habenda sunt.

[1] C. E. Walker, "Observations on the Life History of Leucocytes," *loc. cit.*

Apud Axolotl, in sanguinis guttâ secundum artem tinctâ (polychrome methylene blue) centrosomata discerni possunt in omnibus erythrocytis, nonnunquam duo solum, sæpius plura filamentis tenuibus conjuncta.

Erythrocytorum cytoplasma sine structurâ primo apparet, sed paulatim cernuntur granula quæ e diruptionibus parvis in membranâ nucleari egredi videntur.

Hæc granula eodem modo quo chromatinum et lininum nuclei tinguntur: et chromolinini granula ea appellare proponimus.

Dum granula apparent, nucleus paulatim mutatur sicut in cellulis testiculi degenerantibus apud amphibia et animalia alia vertebrata.

In Crocodili erythrocytis apparent granula in cytoplasmate citius quam apud Axolotl.

Erythrocytorum nuclei apud Crocodilum etiam in corpore sæpe degenerant.

Hoc semper accidere in Gallo videtur.

Erythrocyti quidam in homine (circa 10 per centum) granula includunt chromolinini. Ex his cellulis in paucis (circa 5 per centum) centrosomata inveniuntur, unum nonnunquam, aut duo, plura sæpius, filamentis tenuibus fere conjuncta.

Chromolinini granula, apud hominem, e modis orire videntur similibus illis quibus arte fieri possunt in erythrocytis apud amphibia, apud reptilia, atque aves.

Apud mammalia erythrocytos cognoscimus, nucleis amissis, quoad evolutionem progressos esse.

Opinamur, ergo, phenomena arte causata in animalibus aliis, normaliter accidere in corpore apud mammalia.[1]

Quibusdam in varietatibus anæmiæ erythrocyti

[1] C. E. Walker, *vide* dissertationem præcedentem, p. 99.

nucleati in sanguine reperiuntur, in quem ex ossium medullâ jacentur antequam ad normam evoluti sunt.

Harum cellularum chromolinini granulis præditarum numerus pendere videtur ex evolutionis gradu quum in sanguinem jacentur; et hoc ad conditionem morbidam variabit.

It has long been known that certain granules are to be found in the red blood-corpuscles of man. Hitherto, however, there has been much uncertainty as to the nature of these granules, and but little has been proved as to their significance or origin or with regard to the conditions under which they occur. Apparently the recently developed refined cytological methods have not been used in examining blood-corpuscles, but dried films have been generally employed. This throws considerable doubt on the soundness of the existing observations, for methods involving the drying of cells have been shown to be barbarous where the morphological structures are to be investigated. The results of even partial drying are so disastrous in their effect upon the structures contained within a cell and to the form of the cell itself—more particularly, perhaps, in the case of animal cells—that but little reliance can be placed upon any observations made upon dried specimens. In fact, a structure found in a dried cell does not necessarily imply that it existed during life, and cannot be taken as a safe guide to its nature, properties, significance, or origin.

It is with a hope of clearing up some at least of the doubtful points in this connection that the present communication with regard to our recent investigations is made.

The red blood-corpuscles of several animals have been studied, and, for the purpose of making the significance of these observations clear, a certain sequence has been adopted. The normal red blood-corpuscles of an amphibian will be described first; secondly, those of a reptile; thirdly, those of a bird; and fourthly, those of man. This will be followed by a description of the occurrence of the centrosomes and certain other structures in the red blood-corpuscles in man under certain pathological conditions, and certain deductions therefrom.

Fresh blood from an amphibian (Axolotl) mixed with poly-

chrome methylene blue solution was examined.[1] A microscopic examination with a high power[2] showed that the nuclei of the red blood-corpuscles began to stain faintly within a few minutes. The colour was at first a faint but pure blue. Outside the nuclei, however, one or more small bodies appeared. These were very sharply defined and stained bright red. Very often there were but two, one larger than the other, and frequently they were kidney- or bean-shaped (see Fig. 1). Often, however, there were more than two, sometimes as many as seven or eight or even more (see Figs. 2–4). They were almost invariably close together in one group, frequently connected by filaments,[3] and generally near the nucleus (Fig. 3). To those familiar with the appearance of different cells in animals and plants there could be no doubt as to their being centrosomes, though they were often hypertrophied, and have apparently multiplied without the cell having divided. They were quite different in appearance, structure, texture, arrangement and staining reaction to the granules which appear in leucocytes, and which apparently originate in the archoplasm,[4] or, indeed, to any of the other granules that are so frequently found in the cytoplasm of various cells.

This is what was observed within a few minutes of the blood being mixed with the stain, but after the lapse of an hour, more or less (the time varying with the temperature and other conditions), it was seen that some granules, which were stained more lightly but in the same way as the chromatin, began to appear close to the nucleus in a few cells. These granules were invariably arranged in strings which were generally branching (see Figs. 2–4), the shreds between the granules being more faintly stained than the granules themselves. As time went on these strings of granules appeared in more and more cells, until it was quite the exception to find a cell without them.

[1] For details of process see Note 1 at end of the paper.

[2] We have used a Zeiss 2 mm. objective specially constructed for the 10-inch tube. This allows high eye-pieces to be used without losing definition. The drawings were made with a 27 compensated ocular. A mono-chromatic light was frequently used.

[3] Presenting in this case the same appearance as Heidenhain's "micro-centrum" in the myeloplaxes of bone-marrow.

[4] C. E. Walker, "Observations on the Life History of Leucocytes," Part II, "On the Origin of Granules." (This paper was sent to the Royal Society of London in July, 1906, but has not yet been published.)

At this period it was seen that the nuclei of the red blood-corpuscles were deeply stained. They had, however, changed in appearance. The chromatin seemed to be almost always in large, irregular, and ill-defined masses (see Fig. 4), whereas when first observed the network of the linin with its contained chromatin granules was sharply defined (see Fig. 1). It was easy to follow the nuclear membrane in most cases. A careful examination of several nuclei showed that the nuclear membrane was broken through at certain spots, and it was exactly at these spots that strings of granules appeared to be continuous from its margin into the cytoplasm.

These observations suggest strongly that the strings of granules, which stain more lightly but in the same way as the chromatin and linin, arise from the nucleus and escape into the cytoplasm as the nucleus begins to disintegrate. The chromatin in the nucleus is contained in the tubes of linin when the cell is under normal and healthy conditions. In the disintegration of the nucleus, therefore, it does not seem improbable that the chromatin granules would be held together in strings by the linin.

This suggestion appears to be still further strengthened by what was observed in the case of red corpuscles fixed with suitable reagents immediately upon their removal from the body of the axolotl.[1]

The red corpuscles prepared in this manner showed the nuclei and centrosomes but not the strings of granules staining in the same manner as the chromatin and linin of the nucleus (see Fig. 5).

A further experiment was made with the view of confirming the suggestion conveyed by those which preceded. Some fresh blood was dropped into normal salt solution. It was allowed to stand for over an hour, and was then fixed. The red corpuscles in the preparations made from this blood almost all showed the strings of granules which were absent in the blood that was fixed immediately, but present in the fresh blood some time after removal from the body (see Fig. 6). It was seen also that the nuclei of the corpuscles fixed immediately and those fixed after the lapse of an hour vary just as do the nuclei of fresh blood before and after a similar period (see Figs. 5 and 6).

[1] For details of this process see Note 2 at end of paper.

The blood of a reptile (crocodile) was examined by the same methods as that of the axolotl. The results were essentially the same, and varied in only a few details. The nuclei of the red corpuscles often showed the chromatin in ill-defined masses, and the centrosomes were not always present as they were in the case of axolotl. The strings of granules which stain in the same way as the chromatin of the nucleus seemed to appear more rapidly (Figs. 7 and 8).

We cannot at the present moment assert definitely that this "chromo-linin granulation"[1] appears more quickly in the red blood-corpuscles of the crocodile that in those of the axolotl, as we have not been able to examine them upon the same day and so under exactly the same conditions of temperature, etc. But as the difference in conditions can have been but slight, and those of time were considerable, it is comparatively safe to assume that the chromo-linin granulation does appear more rapidly in the red blood-corpuscles of the former than in those of the latter animal. This assumption is further justified by what we have observed in the case of the red blood-corpuscles of a bird.

The bird used was a fowl, and the same methods were employed. The chromo-linin granulation appeared within a few minutes; indeed, it was very difficult to get a preparation under observation quickly enough to avoid having a few corpuscles which were in this condition (see Figs. 9 and 10). When it is realised that the normal temperature of birds is generally considerably higher than that even of mammalia, it will readily be understood that this is exactly what would be expected, for the sudden alteration of temperature would probably hasten the disintegration of the nucleus very considerably.

In a relatively large number of the red blood-corpuscles of the fowl the centrosomes are absent, and the chromatin of the nuclei seems to be always arranged in irregular and ill-defined masses.

In the case of normal blood in man mixed with polychrome methylene blue and examined in the fresh condition,[2] it was

[1] We propose to use the term "chromo-linin granulation" to indicate the strings of granules that stain in the same way as the chromatin and linin of the nucleus.

[2] The details of the best method for examining blood with this object are given at the end of the paper in Note 3.

EXPLANATION OF PLATE III,

Illustrating the paper by Messrs. Ross, Moore, and Walker, on "The Existence of Centrosomes and other Structures in the Red Blood-corpuscles of Vertebrates." (P. 107.)

FIG. 1.—Red blood-corpuscle of axolotl immediately after removal from the body of the animal. Centrosomes very obvious.

FIG. 2.—Red corpuscle of Axolotl some time after removal from the animal. Branching strings of granules are appearing in the cytoplasm, and the chromatin and linin are coarser in appearance.

FIG. 3.—A similar cell later. The strings of granules are increasing, and the chromatin and linin becoming less well defined. The whole nucleus is darker.

FIG. 4.—A later stage in a similar cell.

FIG. 5.—Red corpuscles of Axolotl fixed with Flemming's fluid (strong formula) immediately upon removal from the body of the animal.

FIG. 6.—Red blood-corpuscle of Axolotl fixed after being kept for about an hour in normal salt solution.

FIG. 7.—Red corpuscle of the crocodile immediately after removal from the body of the animal.

FIG. 8.—Red corpuscle of the crocodile some time later.

FIG. 9.—Red corpuscle of the fowl immediately after removal.

FIG. 10.—Red corpuscle of the fowl, later.

FIGS. 11, 12.—Red corpuscles from human blood exhibiting chromo-linin granulation.

FIGS. 13–17.—Red corpuscles from human blood, showing granulation and centrosomes.

TABULA III,

Ad dissertationem "De Centrosomatibus et Structuris aliis in Erythrocytis apud Animalia Vertebrata," illustrandam.

Ronald Ross, J. E. S. Moore, and C. E. Walker. (P. 107.)

FIGURA 1.—Axolotl erythrocytus ut apparet statim ut e corpore animalis ablatus sit. Præclara sunt centrosomata.

FIGURA 2.—Axolotl erythrocytus, paulum post tempus quam e corpore animalis ablatus est. In cytoplasmate apparent granula in filamentis ramosis disposita. Chromatinum nuclei atque lininum crassiora esse videntur.

FIGURA 3.—Erythrocytus alius, serius ut apparet. Granulorum filamenta angescent; chromatinum atque lininum minus clara fiunt.

FIGURA 4.—Erythrocytus alius serius ut apparet.

FIGURA 5.—Axolotl erythrocytus in liquore Flemming conditus, statim ut e corpore animalis ablatus sit.

FIGURA 6.—Axolotl erythrocytus qui conditus est postquam in liquore sodii chloridi (·75 per centum.) horam unam manserat.

FIGURA 7.—Crocodili erythrocytus, statim ut e corpore animalis ablatus sit.

FIGURA 8.—Crocodili erythrocytus ut paulum post tempus apparet.

FIGURA 9.—Galli erythrocytus statim ut apparet quam e corpore avis ablatus sit.

FIGURA 10.—Galli erythrocytus ut palum post tempus apparet.

FIGURÆ 11, 12.—Hominis erythrocyti granula chromolinini monstrantes.

FIGURÆ 13–17.—Hominis erythrocyti granula chromolinini atque centrosomata monstrantes.

PLATE III.

Ross, Moore, and Walker,
Structures in
(P. 107.)

after removal from the

from the animal.
and the chro-

and the
darker

fluid at long
removed.

but an

after removal from the

removed.

ing chromo-linin

showing granulation and

Structuris aliis in
illustrandam.

(P. 107.)

annulis

ramosis
fila

ut

abiatus

abiatus

Fig. 1.

Fig. 2



Fig. 3.

Fig. 4.

Fig. 5.

Fig. 6.



Fig. 9

Fig. 7.

Fig. 8.

Fig. 10.

Fig. 11.

Fig. 12

Fig. 13.

Fig. 14

Fig. 15.

Fig. 16.

Fig. 17.

Lith. Anst. v. F. A. Funke, Leipzig.

found that branching strings of granules staining blue were found in about 1 per cent. of the red blood-corpuscles (see Figs. 11 and 12). In a certain proportion of these, about 20 per cent., one or more bodies of a different nature were found. These bodies stained bright red, were sharply defined, homogeneous, often two in number, one larger than the other, bean- or kidney-shaped, sometimes connected by filaments, and indistinguishable from the centrosomes of the red blood-corpuscles of axolotl (Figs. 13–17). They have not been found in any cells that did not exhibit the chromo-linin granulation. The same results were obtained with fixed human blood.

The conclusion we draw from the above observations is that in the red blood-corpuscles of man two kinds of granules normally occur. The sharply defined bodies staining red with polychrome methylene blue in the fresh condition are the centrosomes which have been retained after the nucleus has disintegrated. The branching strings of granules staining blue with the polychrome blue method we regard as identical with the chromo-linin granulation described in Axolotl, in the crocodile and in the fowl. We believe that they arise as follows: Nucleated red blood-corpuscles are to be found in the bone-marrow of man. The chromatin of their nuclei is arranged in irregular and ill-defined masses. This arrangement of the chromatin is characteristic of the nuclei of degenerating cells, and may be observed in certain cells in the testis of Triton which are without any doubt in process of disintegration. It is quite unlike the arrangement of the chromatin of any cell in which further division or any prolonged activity is probable. We have seen that this appearance becomes evident as the red corpuscles of Axolotl are dying. The conditions described in the red blood-corpuscles of the reptile, bird, and mammal dealt with are extremely suggestive from the evolutionist's point of view. In the crocodile we find that in the majority of the red corpuscles the chromatin of the nuclei is in the condition found in the red corpuscles of the Axolotl some time after they have been removed from the body. In the bird they are all in this condition of approaching disintegration, while in man we find in the free corpuscles in the blood only a few individuals containing the remnants of a pre-existing nucleus.

It thus appears that the chromo-linin granulation found in

the red blood-corpuscles of man is produced by a series of changes, parallels to which may be produced by certain artificial conditions in the red blood-corpuscles of amphibia, of reptiles, and of birds. We know that the red blood-corpuscles of man have gone some stages further in the process of evolution in having got rid of the nuclei they originally possessed. We therefore believe that the phenomena artificially produced in the red blood-corpuscles of the other animals dealt with occur normally within the bodies of mammalia, and are carried some stages further, so that we find but a small percentage of the red corpuscles showing any trace of the original nucleus and a still smaller percentage retaining the centrosomes.[1]

This belief is further justified by what is found in certain pathological conditions.

As we have said, in presumably healthy normal blood the ratio of red corpuscles containing strings of granules is about 1 per cent. or a little over. In a case of slight malaria the ratio was 2·4 per cent., and in a chronic case with anæmia it was 11·5 per cent. In a case of abscess of the liver, whose red and white corpuscles numbered 4,500,000 and 23,600 per c.mm. respectively, the ratio of granular corpuscles was 6·6 per cent. The ratio is usually very high in cases of kala-azar and ankylostomiasis, and in rats with many trypanosomes. Further researches are being made in this important connection.

We interpret the occurrence of a larger number of red blood-corpuscles with chromo-linin granulation as follows:

In certain cases of anæmia nucleated red corpuscles are found in the blood. This suggests that these corpuscles are thrown into the blood-stream at an earlier stage of their development than is normally the case. The instances we have recorded we regard as intermediate between the extreme quoted above and the normal conditions. Thus it would appear that the percentage of red blood-corpuscles with chromo-linin granulation and centrosomes depends upon the stage of development at which the corpuscles are thrown into the blood-stream, and that the period of development at which they are thrown into the blood-stream will be materially affected by certain pathological conditions.

[1] C. E. Walker, "On the Origin and Differentiation of the Red Blood-Corpuscles of Mammals," 'Path. Soc. Trans.,' vol. lviii, p. 99.

In conclusion, we would point out the possible diagnostic value which the observation of the percentage of red blood-cells containing these bodies may possess. If our observations are correct, it should indicate any change from the normal in the production of the red blood-corpuscles. It should show whether they are being thrown into the blood-stream at an earlier stage than usual, and would very probably indicate changes that it would be quite impossible to discern by estimating the relative proportions of red and white blood-corpuscles.

TECHNIQUE.

(1) Fresh blood from axolotl, from the crocodile, and from the fowl was prepared as follows: A solution of polychrome methylene blue, after having been kept for several months, was filtered so as to be clear of granules. A drop of this solution was placed upon a slide, and a drop of blood drawn directly from the animal was mixed with it. A cover-glass was then placed gently over the mixture and rimmed with vaseline (C. E. Walker).

(2) The following method of fixing, and of making preparations of the blood so fixed, has been used in these investigations. The fresh blood is dropped direct from the animal into a test-tube containing Flemming's fluid (strong formula), glacial acetic acid (1 part), and absolute alcohol (3 parts), Hermann's fluid, or some other suitable fixative. The blood is then allowed to settle as a sediment at the bottom of the tube. In the case of acetic and alcohol the supernatant fluid is then drawn off with a pipette, and the tube is filled up with absolute alcohol. The sediment is allowed to settle again at the bottom of the tube, the supernatant fluid drawn off, and the tube again filled with absolute alcohol. This process is repeated until no smell of acetic acid is left. This completes the first stage of the method in the case of blood fixed with acetic and alcohol.

In the case of Flemming's fluid and most other fixatives, when the blood has settled at the bottom of the tube the supernatant fluid is drawn off with a pipette and the tube is filled up with 20 per cent. alcohol. When the sediment has again settled the supernatant fluid is again drawn off and the tube filled with

40 per cent. alcohol. The process is repeated with 60 per cent., 80 per cent., 90 per cent., alcohol, and two changes of absolute alcohol. This completes the first stage of the method with Flemming's fluid and most other fixatives. It is most important that the tube should be kept well corked throughout, whatever fixative is used. The period between the time that the 20 per cent. alcohol is added and that at which the 80 per cent. alcohol is arrived at should not exceed an hour and a half or two hours at the most. To keep to this condition it will probably be necessary to sacrifice a certain proportion of the blood-corpuscles, as all will not have settled down at the bottom of the tube. This, however, is not a matter of any importance. The use of the centrifuge is not recommended.

When the blood-corpuscles have been for several hours (not less than six) in the last lot of absolute alcohol, most of the alcohol should be drawn off. The test-tube is then held obliquely, and some cedar-wood oil is poured in. The oil all passes beneath the alcohol, and the sediment of blood is left floating at the bottom of the alcohol and on the surface of the oil. The tube is then left standing upright until the blood has sunk through the oil and formed a sediment at the bottom of the tube. The alcohol, and as much as possible of the oil, is then drawn off and more oil poured in. When the sediment has again formed at the bottom of the tube, as much of the oil as possible is drawn off, and the tube is then stood upright in an incubator at a temperature of 45° C. for about five minutes. The tube is then filled with melted paraffin (45° C. melting point), and the sediment allowed to settle at the bottom of the tube. The paraffin is drawn off with a *hot* pipette without removing the tube from the incubator, and this process is repeated two or three times in order to get rid of the cedar-wood oil. When the sediment has settled for the last time the tube is removed from the incubator and plunged into cold water. It is important that up to this time the paraffin should not be allowed to partially solidify. When the paraffin has solidified the tube is broken and the glass removed from the block of paraffin. This block is cut in serial sections with a microtome and the sections mounted on a slide in the ordinary way, care being taken that in fixing the sections to the slides the paraffin is not allowed to melt. When the sections are fixed to the slide

they may be stained by any of the usual methods. We have found basic fuchsin and orange, gentian violet and Bordeaux red, iron alum and hæmatoxylin and acid fuchsin, among the best. The greatest care must be taken that the preparations are not allowed to become even partially dry at any stage in the process, after the paraffin has once been dissolved off. Another way of dealing with them is, after dissolving off the paraffin with xylol, to take the sections through the alcohols down to water. Then add a solution of polychrome methylene blue in glycerine and place a cover-glass gently over it. When the cover-glass has settled down and the excess of the solution has been removed with blotting-paper, the cover-glass may be rimmed round with shellac. This process must be carried out with care, as the glycerine frees the blood-corpuscles from the slide (C. E. Walker).

(3) The simplest method for detecting centrosome and chromolinin granulation in red corpuscles in mammalia and birds, and for estimating the percentage of red corpuscles in this condition, is the following:

A drop of blood is placed upon a clean slide, and in close proximity to it a drop of concentrated and filtered aqueous solution of polychrome methylene blue is placed by means of a rather finely pointed glass rod. Care should be taken that the drop of stain solution is roughly not larger than the drop of blood, in order to avoid the hæmolytic action of the watery solution. The blood and the stain are then rapidly mixed together; and then small droplets of the mixture are taken up with another finely pointed glass rod and placed upon a succession of glass slides, from which the dust has just previously been removed with a clean rag. Cover-slips are now lowered gently upon each of these droplets, and if no dust lies between the two surfaces of glass each droplet will spread out in a very fine film, which is admirably suited for examination. This technique of transplantation is useful, because it enables the observer to obtain films of any tenuity he pleases. On examination, it will be found that most of the leucocytes have stained at once. The blood-plates begin to stain somewhat later. At first the red corpuscles remain unstained, but in about half an hour they take up the colour and show the centrosomes and chromolinin granulation very distinctly. In order to make differential counts, an eye-piece with a counting-square can be used; but an ordinary

eye-piece will suffice if fields containing only a very few corpuscles are selected. Care should, of course, be taken that in the field selected for counting all the corpuscles remain entire (R. Ross). *January*, 1907.

12. *A case of eosinophilic pleurisy.*

By J. J. Perkins and L. S. Dudgeon.

Clinical Examination.

M. R—, housemaid, aged 23 years, was admitted to St. Thomas's Hospital under the care of Dr. Acland, to whose kindness we are indebted for permission to publish the case, on April 4th, 1906, having been ill five days.

The *family history* and her own *previous history* were unimportant.

The onset of her illness was sudden, on March 31st, with feelings of chill and shivering. From that day till admission she remained in bed, suffering from cough and pain in the back and chest, the only other important symptom in the interval being the development of *herpes* on the lip.

On admission, the breathing was rapid (32); temperature 102·6° F., pulse 100. The percussion note over the posterior bases of both lungs was impaired, and on the right there was dulness extending upwards to just above the angle of the scapula. The breath sounds were generally feeble, and loud rhonchi were heard over both lungs, while on the right, at one small spot just internal to the angle of the scapula, the breathing approached the tubular in type, and the vocal resonance was here increased. This was the only evidence suggestive even of consolidation. No crepitations were heard anywhere, and on April 7th this patch of subtubular breathing was noted as no longer present.

The sputum was "viscid," but there was never any mention of it being "rusty."

Nothing else abnormal was detected; the spleen was not palpable. Urine (April 9th) 1025, no albumen, no sugar.

On April 7th the right knee was swollen, but not tender; the inflammation was considered to be in the soft parts round the joint, and no fluid was detected in the joint itself. The swelling was evidently evanescent, as no further mention is made of it in the notes.

From April 9th the patient's condition was one of increasing

dyspnœa (respiration 48), with increasing dulness at the right base and other signs of effusion. On April 20th nine ounces of clear yellow fluid were aspirated from the pleura, pleural friction being heard for the first time *after* its removal. The same evening (April 20th) pericardial friction, general over the cardiac area, was present. For a time the patient was in great danger from cardiac failure; gradually the friction diminished, but signs of pericardial adhesion and its results (increased area of cardiac dulness) remained. On April 26th a systolic murmur was first noticed as distinct from the to-and-fro friction rub. It persisted and was taken as evidence, and rightly so, as the *post-mortem* examination showed, of endocarditis. The condition of the right pleura remained unchanged to the last, dulness with friction being noted from time to time.

About the middle of May the temperature, which for the first three days after admission had been continuous, 101° F. to 103° F., and afterwards had averaged 101° F. at night, the morning temperature varying from normal to 99·6° F., reached the normal, and thereafter continued so with little change. Though the general condition in many respects improved, albuminuria appeared on May 10th, and on May 28th signs of mental change developed; drowsiness, delusions, and delirium, necessitating removal to a small ward. From June 7th the patient lost weight, increasing signs of cardiac failure appeared, with no change in physical signs otherwise, and on August 25th she died.

Pathological Investigation.

A *cytological examination* of the *pleural exudate* was made on April 20th:

		Per cent.
Coarsely granular eosinophils	173	34·6
Polymorphonuclear neutrophils	50	10·0
Small lymphocytes	115	23·0
Endothelial cells	162	32·4

Well-marked fatty change was present in the polymorphonuclear neutrophils; fine fat droplets were seen in a few of the coarsely granular eosinophils. The lymphocytes and endothelial cells failed to show any fat.

None of the cells of the exudate contained any red blood-corpuscles. No micro-organisms were seen in the film preparations of the exudate.

It was impossible to make a *bacteriological examination* of the fluid owing to the manner in which it was sent to the laboratory.

Chemical Examination of Pleural Exudate.

Straw-coloured fluid with slightly alkaline reaction. Specific gravity 1019. A small deposit of blood was present. The serum albumen amounted to 19 grm. per litre. Globulines were present in very small amount, and also albumoses. No reducing substances were present. The urea was found to measure 3½ gr. to the ounce.

A complete *blood examination* was made on April 28th, and the result was as follows:

Red cells	4,896,476 per c.mm.
Hæmoglobin	75 per cent.
Colour index	0·79
Leucocytes	1820 per c.mm.

The examination of the *fresh blood* showed rouleaux formation to be well marked, fibrin formation normal, blood-platelets normal, and the presence of some poikilocytosis.

A differential count of 400 cells was made:

		Per cent.	Per c.mm.
Polymorphonuclear neutrophils	105	26·25	477·75
Coarsely granular eosinophils	33	8·25	150·15
Small lymphocytes	143	35·75	650·65
Large lymphocytes	49	12·25	222·95
Large hyalines	66	16·50	300·30
Mast cells	4	1·00	18·20

A few microcytes were seen.

The *blood serum* showed no evidence of hæmolysis.

The *typhoid serum reaction* was negative. Some loose clumping and some loss of motility occurred at the end of thirty minutes with a dilution of 1 in 20, but no reaction occurred with a dilution of 1 in 50.

A *cytological examination* of the *sputum* was made on April 23rd, with the following result:

		Per cent.
Polymorphonuclear neutrophils	370	92·5
Coarsely granular eosinophils	2	0·5
Small and large mononuclear cells (non-granular)	28	7·0

Most phagocytes contained many diplococci.

A *bacteriological examination* of the *sputum* was made on the same date.

A saline emulsion of the sputum was made, and "nasgar" and blood agar plates were inoculated; pure cultures were obtained of the *Staphylococcus aureus* and *Staphylococcus albus.* The former was by far the most predominant organism.

A *second blood examination* was made on May 10th:

Leucocytes . . . . 1980 per c.mm.

The *fresh blood* examination showed rouleaux formation to be perfect, fibrin formation very slight, blood-platelets very scarce, and poikilocytosis well marked.

A differential count of 300 leucocytes was made:

		Per cent.	Per cmm.
Polymorphonuclear neutrophils	114	38·0	752·4
Coarsely granular eosinophils	18	6·0	118·8
Small lymphocytes	39	13·0	257·4
Large lymphocytes	63	21·0	415·8
Large hyaline cells	61	20·3	401·94
Transitional leucocytes	1	0·3	5·94
Mast cells	3	1·0	19·8
Finely basophilic cells	1	0·3	5·94

Some microcytes were seen, and slight polychromatophilia was found to be present.

The *third blood examination* was made on June 12th:

Red cells	4,162,500 per cmm.
Hæmoglobin	65 per cent.
Colour index	0·79
Leucocytes	5100 per cmm.

A fresh blood examination showed rouleaux formation and fibrin formation to be normal, blood-platelets very numerous, and some poikilocytosis to be present.

A differential count of 400 cells was as follows:

		Per cent.	Per cmm.
Polymorphonuclear neutrophils	254	63·5	3238·5
Small lymphocytes	76	19·0	969
Large lymphocytes	44	11·0	561
Large hyalines	26	6·5	331·5
Coarsely granular eosinophils	—	—	—

A few ghosts were seen and some microcytes.

On August 25th an attempt was made to withdraw fluid from the pleural cavity immediately after death. A few drops of fluid were obtained, suitable media were inoculated with it, but all proved to be sterile at the end of several days' incubation at 37° C. Film preparations were made, but only blood-cells were seen.

A *post-mortem examination* was made on August 27th, by Dr. P. N. Panton, thirty-six hours after death. The body appeared to be fairly well nourished, but there was considerable œdema of both legs and trunk.

Thorax.—There were numerous pleural adhesions on both sides, chiefly basal. A little greenish and gelatinous material was attached to the visceral layer of the pleura at the site of the adhesions. There was no free fluid present.

The *lungs* (right 16½ oz., left 14¾ oz.).—The lungs were normal on section, except for some hypostatic congestion of both bases.

The *mediastinal glands* were *normal.*

The two layers of the *pericardium* were tightly adherent and were only separated with considerable difficulty. A little gelatinous material, similar to that found in the pleural sacs, was enclosed among the pericardial adhesions.

The *heart* (16¼ oz.) was generally enlarged. The right auricle and the right ventricle were dilated, the pulmonary and the tricuspid valves were normal. The left ventricle was dilated and hypertrophied. The aortic valves were thickened and showed numerous, somewhat recent, vegetations. Similar, but less numerous, vegetations were present also on the mitral valves.

The *abdomen.*—There was some excess of free fluid in the peritoneal cavity, but there was complete absence of any adhesions.

The *intestines* were found to be normal.

The *liver* was considerably enlarged (65¼ oz.), and presented a typical nutmeg appearance.

The *spleen* (6¾ oz.) was tough, but otherwise normal.

The *kidneys* (11½ oz.) were tough and congested.

The *uterus, uterine appendages, vagina, and bladder,* were found to be normal.

The *brain* (40¾ oz.) was normal.

Microscopical Examination.

Sections of the *lung* with the adjacent *pleura* were made and stained with Leishman's stain, but failed to show any coarsely granular eosinophil cells. No tubercle bacilli were present, and there was no histological evidence of tubercle.

A piece of the *heart-muscle* and thickened *pericardium* were subjected to microscopical examination. There was well-marked fatty, and hyaline change in the muscle-cells, only few of which appeared to be normal in the sections which were examined, but we failed to find any coarsely granular eosinophils. In one portion of the sections a small, hæmorrhagic infarct was found to be present. There was very little recent inflammatory exudation in the region of the infarct, and no micro-organisms were detected. There was no microscopical evidence of tuberculosis, and no tubercle bacilli were seen.

Diagnosis.

In this case there was evidently a systemic infection (as shown by the acute endocarditis and the transient inflammation round, or in, the knee) which caused pleurisy and pericarditis, and ultimately led to death by the mechanical embarrassment resulting from the pericardial adhesion and myocardial degeneration. Of any invasion of the lung proper, apart from the bronchi, there was no evidence, either during life or after death. The *Staphylococcus aureus* and *albus,* which were present in the sputum, were probably absent from the pleural effusion, as the differential cell count shows. Pneumococcus infection, which would fit in with some of the features of the onset, must be ruled out on similar grounds. In acute rheumatism, which the arthritis and the endocarditis might suggest,

polymorphonuclear leucocytosis is the rule, though one case of eosinophilia has been quoted. The cell count of the pleural exudate might be thought to favour tuberculosis, but the lymphocytosis was far below, and the endothelial count far above, what occurs in this disease. The absence of any evidence of tuberculosis in the glands, the pericardium, and pleura must be held decisive.

Syphilis causes a lymphocytosis and eosinophilia, but in our case there was absolutely no sign or symptoms of syphilis, nor was there any marked anæmia.

Gonorrhœa, though causing eosinophilia, must be discarded; repeated careful inquiry during life never showing the presence of any discharge, and at the autopsy a most thorough examination showed all the pelvic organs perfectly healthy in every respect.

In influenza there is an absence of leucocytosis, and marked leucopenia has been recorded. In malignant endocarditis (and in our case there was acute endocarditis) our experience is in agreement with those who consider that leucocytosis, to any extent, is a rarity; usually the number of the white cells is either normal or slightly in excess, while sometimes the number is below normal. The absence of the influenza bacillus from the bronchial tracts is the chief difficulty in the acceptance of this view.

For the leucopenia, so profound, and yet transient, and without marked anæmia, we have no explanation to offer.

The slight typhoid serum reaction obtained is common to any acute disease, but is without any diagnostic value.

Remarks.

Ever since Widal[1] drew attention to the important results which might be obtained by a cytological study of the fluid removed from the various serous sacs, considerable work has been done on this subject. Cases in which either lymphocytosis, or the increase of the polymorphonuclear neutrophils, or of the endothelial cells is the predominant feature, are known to all who have made a study of cyto-diagnosis, but an inflammatory

[1] Widal et Ravaut, "Applications Cliniques de l'Étude Histologique des Épanchements Séro-fibrineux de la Plèvre," 'Soc. Biol.,' 30, vi, 1900.

exudate, associated with the presence of large numbers of eosinophil cells, is exceptionally rare. During the last five years we have examined very large numbers of specimens of fluid removed from the various serous sacs, but we have never met with a case in which the eosinophils were the chief feature of the cell account. E. A. Ross, in his exhaustive monograph, recently published in the 'Transactions of the Pathological Society of London,' failed to quote a case of this kind.

Widal himself draws attention to four instances of eosinophilic pleurisy:—

CASE 1.—An instance of secondary pleurisy in which 37 per cent. of eosinophils were present in the pleuritic effusion, and 5 to 6 per cent. in the blood.

CASE 2.—A sero-fibrinous effusion occurring during the course of typhoid fever. Twenty-three per cent. of eosinophils were found in the effusion, but only 2 to 4 per cent. in the blood.

CASE 3.—Hæmorrhagic pleuritic effusion which contained 54 per cent. of coarsely granular eosinophils, but only 9 per cent. were found in the blood.

CASE 4.—An encysted sero-fibrinous pleuritic effusion occurring in a man who had been living in the tropics, and who was also suffering from hepatic and general glandular enlargement. In this case there were 14 per cent. of eosinophils in the pleural exudate, but only 1 to 4 per cent. in the blood.

The pleuritic effusion in each of these cases was injected into the peritoneal cavity of guinea-pigs, and found to be very toxic.

Barjon and Cade [1] give an account of five cases which came under their observation.

CASE 1.—Acute pleurisy with onset marked by definite chill, recovery rapid and complete. Twelve per cent. of eosinophils in the first count of pleuritic effusion, and 18 per cent. in the second count. The endothelial cells amounted to 42 per cent. Guinea-pigs, which were inoculated with the sero-fibrinous effusion, failed to show any evidence of tuberculosis or any acute illness. There were no signs of tuberculous disease in the patient, and the serum diagnosis for tuberculosis was negative.

[1] Barjon et Cade, 'Archives générales de Médecine,' August, 1903.

CASE 2.—A case of chronic interstitial nephritis which occurred in a painter. There were 10 per cent. of eosinophils in the effusion, and 73 per cent. of endothelial cells. The fluid was found to be non-pathogenic to guinea-pigs.

CASE 3.—A case of contracted granular kidneys in an alcoholic man. A hæmorrhagic pleural effusion occurred in the left pleural sac, and was tapped on three occasions. At the first tapping there was no eosinophilia; at the second there were 23 per cent. of eosinophils and 27 per cent. of endothelial cells; and at the third tapping there were 13 per cent. of eosinophils and 17 per cent. of endothelial cells. There was no evidence of tuberculosis at the *post-mortem* examination.

CASE 4.—Acute pleurisy in a healthy man who completely recovered. Blood-stained fluid was removed twice from the pleural sac. At the first occasion, there were 46 per cent. of eosinophils and 15 per cent. of endothelial cells; at the second tapping the eosinophils amounted to 74 per cent., and the endothelial cells to 10 per cent. A blood examination made on the same day showed 17 per cent. of eosinophils.

CASE 5.—Acute rheumatism associated with endocarditis and pleurisy. Blood-stained fluid was removed from the pleural sac and 35 per cent. of eosinophils and 10 per cent. of endothelial cells were present in the pleural exudate. There were 10 per cent. of eosinophils present in the blood. At the second tapping the fluid was sero-fibrinous, but no longer hæmorrhagic. The eosinophils amounted to 8 per cent., while at the third tapping no eosinophils were present. The fluid from all these tappings, when inoculated into guinea-pigs, was found to be non-pathogenic.

Reviewing these cases, the most striking point in the cell-count, next to the eosinophilia, is the abundance of the endothelial cells which were so numerous in our own case. Further, one is struck by the multiplicity of diseases with which eosinophilic pleurisy is associated—syphilis, typhoid, acute rheumatism, renal disease, pulmonary tuberculosis, and acute pleurisy of undetermined origin; and, indeed, no relationship to any organism can be proved, for cultures, as far as the reports show, appear to be negative in every instance. It may be noted that Barjon and

Cade fail to confirm the intense toxicity of the fluid such as was observed by Widal.

Considering this constant failure to cultivate any micro-organism from the fluid, it is most unfortunate that we were unable to submit the fluid which we obtained from the pleural sac in our case to a bacteriological examination, and test its pathogenicity on animals. If eosinophilic pleurisy is due to such an organism as the influenza bacillus or the gonococcus, failure to cultivate the micro-organism might depend upon the fact that incorrect media were employed for the purpose, but in our case no micro-organisms were seen in the pleuritic effusion, either in the cells or otherwise, and also the influenza bacillus was not cultivated from the sputum, or seen in it, and there was no evidence of gonorrhœa. Dudgeon and Ross[1] have shown that eosinophilic effusions are known within the first few hours subsequent to intra-peritoneal inoculation of micro-organisms, either living or dead, of toxins, and of sterile non-toxic substances. In such instances, although the number of eosinophils in the peritoneal effusion was often very considerable, yet a marked eosinophilia was seldom met with in the peripheral blood. Eosinophilia was produced in their experiments whatever substances were employed, while eosinophilia usually occurs in man either through non-bacterial products or at the termination of acute infective processes.

December 4th, 1906.

---

13. *A histological study of the human parathyroid glands.*

By W. L. Harnett.

(With Plates IV and V.)

This paper deals with the results of the histological examination of the parathyroid glands from forty autopsies upon persons dying as the result of various accidents and diseases.

The work was undertaken in the hope that thereby some few indisputable facts might be brought to light concerning an organ whose variations of structure appear to have hitherto been practi-

[1] Dudgeon and Ross, 'Path. Soc. Trans.,' 1906.

cally ignored, physiologists having, with few exceptions, confined themselves to observations of the results of operative procedures, and having arrived thereby at somewhat contradictory conclusions.

Moreover, attention has been directed to these glands as factors of great pathological importance in certain diseases. The evidence for this appears to rest rather upon a similarity between certain of the symptoms of these diseases and those obtained by some observers after operative removal of the parathyroids, than upon definite anatomical changes in the glands occurring in fatal cases of these diseases.

A brief introductory survey of the principal points in the history of the observations upon the parathyroids may be of use, the subject being at present in a state of confusion owing to the number of statements directly contradictory of each other which have been published.

Discovered by Sandström in 1880, they were regarded by him, as well as by others who afterwards independently observed them, as embryonic residues of thyroid, destined to form fresh thyroid tissue when required. Sandström accurately described the four parathyroids usually present in man, and noted the different types of microscopical structure to be met with, and the occasional occurrence of small masses of a substance having the micro-chemical reactions of thyroidal colloid. He also examined some of the common mammals, and in all found similar organs, but only one on each side; the existence of the internal parathyroids in these animals was not discovered till a later date.

From time to time these glands were re-discovered by various observers and described as embryonic thyroid tissue, particularly noteworthy being the account given by Rogowitch (1), in 1888, of the structures in the dog, which we now know to be the internal parathyroids.

General attention was first drawn to the subject by the remarkable work of Gley, published in 1891. Briefly summarised his main results were: (1) That removal of both thyroid and parathyroid in the rabbit led almost invariably to death, with acute symptoms within a few days. This had been previously shown by Horsley to be the usual result of thyroidectomy in the carnivora. According to Gley the parathyroids in

the carnivora lay close to the thyroid and were invariably removed with it, hence the acute symptoms and rapidly fatal result; whereas in rodents they lay at a distance and were left behind by previous operators. The dissimilar results of the operation in these two classes of animals were, therefore, to be attributed to the two operations, as previously performed, being essentially dissimilar. The existence of the internal parathyroids was, of course, at this period unknown. (2) Removal of the thyroid in dogs and in rabbits, leaving the (external) parathyroids *in situ*, caused usually no symptoms, but subsequent removal of the parathyroids led to death with acute symptoms, as in the above experiments. (3) Extirpation of the (external) parathyroids alone caused no ill effects. As to whether the parathyroids left, after removal of the thyroid, underwent development into thyroid tissue, Gley made contradictory statements in his papers, but finally pronounced against the occurrence of this change. Reference will be made later to the possible interpretation of Gley's description of what he found.

Edmunds, in 1895 (2, 3, 4), repeated Gley's experiments, obtaining similar results, and describing, also, a condition resembling myxœdema in rabbits whose thyroids had been removed, leaving the parathyroids.

The recognition of the internal parathyroids in the cat, dog, and rabbit, was the work of Kohn, and was published in 1895 (5, 6); this was a discovery of the greatest importance, and one which sharply divides the history of these investigations into two periods. The results obtained up to this date were explicable by the view that the parathyroids are able, when necessary, to functionally replace thyroid tissue, but are not themselves essential to life.

Experiments were now brought forward which, if they are accepted, compel us to regard the parathyroids as organs of the first importance for the continuance of life.

Vassale and Generali, in 1896, were the first to claim to have shown that removal of the four parathyroids, leaving the thyroid *in situ* in cats and dogs, led to death with acute convulsive symptoms within a few days. From this it would follow that the rapidly fatal result of complete thyro-parathyroidectomy is due to the absence, not of thyroid secretion, but of parathyroid secretion.

Various observers published the results of similar experiments, some confirming, some denying, the truth of these statements, but they appear to have gradually gained acceptance, as they are now to be met with in most text-books of physiology.

In 1904, however, Swale Vincent and Jolly (7, 8, 9), published the first of a series of papers in which they attack these conclusions. They bring forward an extensive series of experiments, performed with very great care. To review all their experiments would be outside the scope of this short summary, but one set must be quoted on account of their enormous importance. In a series of nine cats they removed all four parathyroids, leaving the thyroid *in situ*, taking the precaution to ascertain by histological examination that the bodies removed were really parathyroids. Six of the animals survived without showing any symptoms and were killed some time after, when the most careful search, macroscopic and microscopic, failed to show a trace of parathyroid tissue remaining. Three of the animals died with acute symptoms, but in these the thyroid had been severely damaged during the operation. Several series of experiments on different animals gave uniform results. They describe also changes in the parathyroids left after thyroidectomy, which will be again referred to. Very great weight must, in my opinion, be attached to the conclusions reached by these workers, as in their experiments many sources of error, which could be objected against the earlier work, were eliminated.

MacCallum (10, 11), and Kishi (12), have also published experiments in recent years, but as their methods are open to objections which do not apply to those of Vincent and Jolly, they cannot be considered to have added anything material to our knowledge of the subject.

With this brief survey I leave this branch of the subject, and pass on to detail the results of my histological studies, indicating as I proceed points which appear to me to allow of legitimate deductions as to function being drawn from structure.

Technique.

In every case the attempt was made, but not always with success, to dissect out all the parathyroids. They were fixed in

formalin (10 per cent.), and paraffin was employed as the imbedding medium, but in most cases one gland from each subject was sectioned by the freezing method and stained with Scharlach R, this dye being now generally allowed to be superior to all others for the detection of minute quantities of fat. For the paraffin sections, hæmalum and eosin was found to be the most generally useful staining method, but for the minute study of the cells under high magnification Leishman's stain, used in 0·5 per cent. solution, according to the method introduced by Dudgeon, was found to be by far the most useful. In the delicacy and certainty with which the minutest features of the granulations of cell protoplasm are differentiated this stain is immeasurably superior to any other which has ever been introduced for cytological work. The only drawbacks it possesses are that a considerable amount of experience in using it is necessary to obtain the best results, and that the preparations are apt not to be permanent.

General Anatomy and Histology.

I need not here go over the macroscopic anatomy of the human parathyroids. A paper by Welsh (13, 14) gives the best description published in recent years, and to it I have nothing to add. Microscopically the gland consists of masses of cells, imbedded in a varying amount of connective tissue, which carries the blood-vessels, etc.

The cells.—Welsh, in 1898, was the first to point out that in most parathyroids two apparently different kinds of cell can be observed:

(A) *The so-called "principal" cell.*—This has a relatively large, lightly staining nucleus, with a variable amount of cytoplasm which is perfectly clear and structureless and entirely devoid of granularity. As a rule the cytoplasm of this cell cannot be stained by any of the ordinarily used dyes, but occasionally it takes on a very faint, diffuse bluish tinge with the basic dye. It is stated by Welsh that this cell is smaller than the one next to be described, but I find, as the result of examining large numbers, that its size varies within very wide limits.

(B) *The "oxyphil" cell.*—This has a relatively smaller, darkly staining nucleus and a relatively abundant cytoplasm, which

stains vividly with acid dyes, and under high magnification shows a very fine oxphil granulation. In its typical form it appears larger than the principal cell, and bears a striking resemblance to the cells of a glandular organ—such as the liver.

These cells are sometimes called "eosinophil," but the use of this term is best avoided on account of the very definite significance which it has now acquired in hæmatology. Sharply as these two varieties of cell appear to contrast with each other, a study of their characters in glands from persons of all ages, with the aid of Leishman's stain, which brings out clearly the least trace of oxyphil granulation of the cytoplasm, shows that they are linked together by numbers of intermediate forms. A section showing well-marked oxphil cells will show, also, cells with smaller and smaller amounts of oxphil granulation, till we reach a cell with merely a trace of fluffy-looking oxphil substance in the midst of the clear cytoplasm; the distinction between such a cell and the "principal" cell can only be made by careful examination under high magnification. In size and staining character of the nucleus, also, we find the two connected by numerous intermediate varieties. The conclusion is irresistible that the two are merely phases of one and the same cell—a phenomenon almost universally met with in the cells of secreting glands. The oxyphil cell is the resting stage, the principal cell the discharged stage, and, naturally, cells are met with in all intermediate stages, since we know of no periodicity in the parathyroid secretion as in that of the pancreas or salivary glands. It is for this reason that we hardly ever meet with glands composed entirely of resting cells, or entirely of discharged cells. In the fœtus and infant the gland at first sight appears to consist entirely of discharged cells, but I shall give reasons later for holding that these are cells which have not yet commenced to secrete.

Arrangement of Cells.

Welsh, in his paper, describes four types of arrangement of the principal cells: (1) A uniform mass of cells in apposition with each other with no intercellular stroma, except a few strands of connective tissue carrying blood-vessels. (2) A slightly more developed type, the cell masses showing a

tendency to be broken up by strands of connective tissue into anastomosing columns. 3, The cells forming branching columns, appearing in cross-section as acini without a lumen. 4. Well-formed acini with a lumen, containing a substance having the appearance and micro-chemical reactions of thyroidal colloid.

This classification may be conveniently used for descriptive purposes, so long as it is recognised at the outset that one practically never meets with a gland conforming wholly to any one of these types, except in the case of the first, which represents, as will be detailed presently, the common appearance of the gland in the fœtus and young child. In the actively-functioning gland areas corresponding to the first three types may always be picked out, whilst the fourth type must be regarded as representing the highest stage of development of the gland, and is usually only represented here and there by single vesicles in a gland showing elsewhere evidence of great activity.

Welsh also describes several types of arrangement of the oxyphil cells. Accepting the view that these are the same cells as the principal cells, but in different stages of their activity, any classification of their arrangement becomes unnecessary, more especially as it follows from what has been already said that the distinction between what is and what is not an oxyphil cell is very artificial when the cells are examined under high magnification with the aid of Leishman's stain. The typical oxyphil cells occur singly or in groups, mixed up with principal cells and with the intermediate forms already referred to. Such terms as "oxyphil," "principal," and "intermediate," or "transitional" type of cell are retained in this paper for convenience of description only.

A few other points remain to be dealt with under this heading. In the first place it is frequently noticed that many of the cells at the extreme periphery of the gland are smaller, and the nucleus therefore relatively larger, as though they were pressed together more closely. Welsh stated that the oxyphil cells occur in greater numbers at the periphery. My specimens do not bear out this statement, in fact, it is at the periphery of the gland that the greatest difficulty is generally experienced in determining whether the cytoplasm is oxyphil or not, by reason of this crowding together of the cells.

Another commonly noticed point is that the arrangement of

the cells in the third type, columns appearing in cross section as acini without lumen, is most frequent at the periphery.

The Secretion of the Parathyroid.

In appearance and micro-chemical reactions the parathyroid secretion closely resembles thyroidal colloid. It is homogeneous, and stains usually with eosin, when hæmalum and eosin are employed, but with Leishman's stain it most commonly takes up both dyes and appears as a greenish blue, though occasionally it takes up the eosin only.

It may be seen as droplets lying free amongst groups of cells, or as small masses enclosed in vesicles, or lying in spaces which seem to be lymphatics in the interstitial tissue. As regards the cells lining the vesicles they are sometimes clear, sometimes slightly granular, rarely one or two typical oxyphil cells may form constituents of the lining layer.

The following specimen seems to me to throw some light on the way in which vesicles may be formed. It is the parathyroid of a child, aged 9 months, who died from broncho-pneumonia following whooping cough (Case 33). As a result of the enormous back-pressure during the paroxysms of coughing, many of the capillaries have ruptured, and blood has been effused between the cells of the gland. Large spaces, lying in the midst of cell-masses, from which they are not delimited by any bounding septa of connective tissue, have been opened out in several places, and strikingly resemble thyroid vesicles. They are lined by the clear cells of the gland, and contain the remains of effused blood. Had this taken place in a gland of a higher type—that is to say, one in which the gland-cells were more broken up by septa of connective tissue, the resemblance to thyroid tissue (imagining the blood to be replaced by colloid) would have been much more remarkable.

This is, of course, an extreme instance of what may occur, and one rarely sees a parathyroid showing colloid-containing vesicles which in any way approach these in size; but Forsyth (15) has recorded the appearances of the parathyroid in a case of myxœdema, and his figures show vesicles of a size quite comparable to these.

The formation of vesicles in the parathyroid may, therefore, be dependent upon mechanical conditions. As long as the secretion is in small amount it is carried away by the efferent channels as fast as formed, but in the more active glands the secretion tends to accumulate faster than it can be removed. It follows from this that the greatest number of vesicles should be found in the most active glands, and none at all in those showing evidence of slight activity. I find that this is so, and I shall refer again to

FIG. 26.

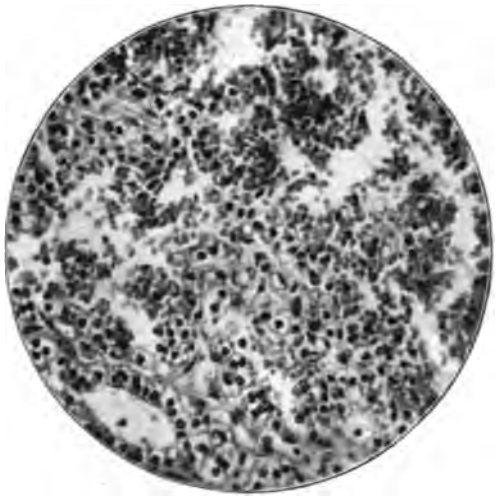

A section of the parathyroid described in the text (Case 33), showing the manner in which the extravasated blood has insinuated itself between the epithelial cells. At the lower border of the figure there is a well-formed vesicle. Zeiss D, Oc. 2.

the point in dealing with the evidences of differing activity met with in various parathyroids.

When only a few vesicles are present, they are found, for the most part, near the periphery of the gland, but when they are in large number they occur in the central parts as well. From this it may be argued that the normal path of the secretion is towards the periphery; accumulating faster than it can be removed it therefore aggregates and separates the cells to form vesicles, first at the periphery, and later in the central parts. It will be remembered that it is at the periphery that one meets most frequently with that arrangement of the cells into columns,

which, when distended with secretion, would form the most perfect vesicles.

Swale Vincent and Jolly, in one of their papers, give figures of portions of the parathyroids some weeks after removal of the thyroid and two parathyroids. The figures show colloid-containing vesicles similar in every way to those met with in sections of active glands. The authors do not give any information as to the amount of oxyphil granulation in the cells of the glands. The mere presence of colloid vesicles, however, is evidence of great activity, and may reasonably be attributed to the extra work thrown on the parathyroids in attempting to compensate for the lost thyroid.[1]

Fat in the Parathyroid.

About a year ago Humphry (20) published a description of the histology of the parathyroid gland in Graves' disease, in which he stated that, in the four cases examined, the salient feature was the presence of large quantities of fat, intruding itself between the gland cells and leaving in places only islets of epithelial tissue. This appearance he regarded as pathological, and adduced it as evidence that the function of the gland was interfered with in this disease, a suggestion first made by Edmunds (4), in 1896, upon experimental grounds.

It was then pointed out by Shattock (21) that fat, in variable amount, is normally present in the connective tissue of the parathyroid, and is a recognised feature of the histology of the gland.

I have investigated this point in thirty-three of my cases, using Scharlach R to stain the fat.

I find that two forms of fatty change in the parathyroids may be recognised: (1) Interstitial, large globules enclosed in attenuated cells, and differing in no way from fatty tissue as met with elsewhere in the body; this form of fat is readily recognised in specimens prepared with alcohol as vacuoles lying amongst the gland cells, and is presumably the form referred to by Humphry.

[1] Gley and Nicholas denied the occurrence of colloid in the parathyroid after thyroidectomy. They describe hypertrophy and an alteration in the staining reactions of the epithelial cells, an increase in their power of taking up the dye. Possibly what they saw was an increase of oxyphil granulation, which would be evidence of increased activity.

(2) Intra-cellular, minute droplets of fat in the cytoplasm of the cells, which can be detected only by appropriate staining. In specimens dehydrated with alcohol there is no indication of the presence of this fat, and the cells containing it may be either oxyphil, transitional, or with perfectly clear cytoplasm. It gives rise to no vacuoles in the cell, and a cell with perfectly clear homogeneous protoplasm may be loaded with fat or may contain not a trace; only the use of an appropriate stain will settle the point.

In the majority of instances the fat is present in both situations and in the same relative quantity. In only one case of my series was the fat wholly intra-cellular, and in one case wholly interstitial.

In most glands the distinction between what is here called the interstitial and intra-cellular forms of fatty change is well marked and readily recognised with the aid of Scharlach R, but if a gland in which the fatty change is very advanced be carefully studied it is found that, as in the case of the oxyphil and principal cells, the distinction is one of degree rather than of kind. Although the interstitial fat is contained in cells which are quite unrecognisable as parathyroid gland-cells, yet a few cells are met with containing small fat vacuoles which in other respects are ordinary principal cells. Sparsely as these cells are found, their presence is evidence that the interstitial form of fat is merely an exaggeration of the intra-cellular. They are cells in various stages of replacement by fat, and one may conclude that the ordinary form of interstitial fat is contained in worn-out cells which are possibly about to be disintegrated. However this may be, the two terms represent a distinction which is usually readily made, and one which is useful for descriptive purposes.

Analysing the thirty-three cases in which Scharlach R was used, I find that fat was present in twenty-three, and absent in ten; whilst in the remaining seven cases interstitial fat could be seen in the eosin, and hæmalum specimens in five instances, making twenty-eight cases out of forty in which fat was present.

A striking fact which appears in this series is that in every case in which fat is present, well-marked oxyphil cells are also present, and furthermore, the relation is roughly quantitive. Glands in which the cells are all clear, or show only faint indi-

cations of oxyphil granulation of the protoplasm, present not a trace of fat when stained with Scharlach R and examined with a $\frac{1}{12}$ in. objective, where moderate activity is indicated by a fair number of oxyphil cells, numerous intermediate types of cell, and perhaps a few droplets of colloid, the Scharlach specimen usually shows droplets of fat in most of the cells, and a few large interstitial globules; whilst other glands are met with where every cell is loaded with fat, and there are enormous areas of interstitial fat. In these will be found large clumps of oxyphil cells, great numbers of intermediate cells, and many colloid-containing vesicles, all of which I take to be evidence of intense activity.

I have not succeeded in satisfying myself as to whether the fat is present in greater amount in the discharged cells than in the resting or oxyphil cells; I am inclined to think that it is so, but the difference is not a very marked one, and it must be borne in mind that the frequently larger size of the oxyphil cell is apt to give the impression that it contains absolutely less fat, when it may contain only relatively less.

The fat in the parathyroid appears, then, to be in some way closely related to the functional activity of the gland. One is tempted to surmise that it may be a by-product in the manufacture of the colloid, but there is absolutely no chemical evidence of this being so, nor did I find any similar relation in the thyroid itself between the amounts of colloid and of fat respectively. This view also involves the assumption that the secretion of colloid is the only function of the parathyroid, and I do not think that the evidence is as yet sufficient to warrant us in going thus far.

As will be shown in the following sections, the fat in the parathyroids increases as age advances, *pari passu* with the increase in the number of oxyphil cells.

Basophil cells.—Cells with large, coarse, basophil granules are very abundant in the interstitial tissue; they differ in no way from the basophil cells met with normally in connective tissue, and no special significance is to be attached to their presence.

The Parathyroid at Various Periods of Life.

In the fœtus at four and a half months the gland presents a simple type, consisting of masses of clear cells broken up by

a few strands of connective tissue carrying capillaries. Not a trace of oxyphil granulation in the cells, of fat, or of colloid is to be seen. From the entire absence of these three features one may conclude that the gland is not as yet functioning.

The following statements are based upon the examination of a series of glands from subjects most of whom died as the result of disease, but some from accidents. The series is so incomplete that no attempt is made to give more than the roughest approximation for the periods of life at which the various types are met with; indeed, it is probable that the limits of variation in this respect are too wide to allow of any precise statements being made.

The fœtal type of gland persists during early infant life, but at some period, probably extremely variable, the commencement of activity is indicated by the appearance of slight oxyphil granulation in some of the cells. The youngest gland in which this was seen was from an infant, aged 15 weeks; but, on the other hand, many glands were met with up to three years of age in which no trace of oxyphil cells could be seen. No colloid was ever seen in these glands, nor was any fat present.

These statements are based upon the pathological series of cases, as no glands were obtained from accident cases in these young children.

The youngest gland showing well-marked oxyphil cells of the ordinary type, with many transitional cells, was from a child, aged 10 years, dying of tuberculous peritonitis. Fine, fatty change was well marked, but no colloid was present. This case is the link between the gland of childhood and that next to be described.

In the young adult the gland shows a higher stage of development. Connective tissue is present in greater amount, dividing up the cell columns to form the second and third types of Welsh. Numerous large oxyphil cells are present, often in groups of two to six, and large numbers of cells show some degree of granularity. Fat is present in moderate amount, both in the cells and interstitial, and colloid droplets are often seen, either free or in lumina.

Passing on to the gland as met with later in life, we find evidence of increasing activity as age advances. The arrangement of the cells in the fourth type is more frequent; oxyphil

cells occur in great number, and colloid is often present in considerable quantity. On the whole, the most striking feature of glands from old subjects is the amount of fat, both interstitial and intra-cellular; the encroachment of the interstitial fat, however, usually leads to no diminution in the amount of the secreting tissue, so that in the very fatty glands the size of the organ is sensibly increased. Evidence of active proliferation of cells to replace those converted into fatty tissue was not seen, but as the whole of this material was obtained from the *post-mortem* room no weight can be attached to the failure to find mitotic figures.

Fibrosis is rarely seen in the parathyroids from old people, whereas in the thyroid it is of frequent occurrence, the parathyroid, on the other hand, presenting signs of great activity. A large quantity of colloid in the parathyroid is not necessarily associated with any appreciable diminution in the amount of it to be seen in sections of the thyroid.

The general conclusion to be drawn is that the parathyroids commence to function in infancy, become more active as age advances, and attain the acme of their activity in later life, at a time when, if one may judge by the commonly occurring fibrosis, the thyroid is beginning to fail.

The Parathyroid in Disease.

Undertaken with a view to ascertaining whether the gland underwent any changes in disease, this investigation has from this point of view been productive of practically no result.

Congestion of the vessels of the gland is frequently met with in acute toxic conditions, but in no other way do these glands differ from the normal.

The majority of the material was obtained from subjects who had died from conditions associated with well-marked cachexia, but the parathyroids presented no feature which could not be exactly paralleled in the glands of normal persons at about the same period of life dying as the result of accident. It might be anticipated that in cases of wasting disease the glands would show some evidence of alteration, either in the direction of increased or diminished activity. Bearing in mind the enormous variations which may be met with in the normal glands at different periods of life, it is impossible to be certain that the

appearances found may not be those normal to the individual at that age.

Eight glands were examined from children up to twelve years of age dying from tubercle or marasmus, and all showed the usual inactive or slightly active gland which is apparently normal. A series from persons of all ages dying from tubercle, carcinoma, diabetes, and other diseases, did not markedly differ from the organs obtained from subjects at the same period of life dying as the result of accident.

Amyloid change was once seen in the vessels of the gland from a subject showing advanced amyloid change in other viscera. A special interest attaches to a case of Addison's disease in a man, aged 33 years, but here, too, the gland presented nothing abnormal.

The Parathyroid in Disease of the Thyroid Gland.

On the view that the function of the parathyroid is closely related to that of the thyroid, that it is capable of providing a similar, if not identical, secretion, and that, as shown by Vincent and Jolly, it undergoes great change in the direction of increased activity after thyroidectomy, great importance attaches to its appearance in disease of the thyroid.

Forsyth (15) has lately published a description with figures of the gland in a fatal case of myxœdema in a woman, aged 58 years. He finds that the gland shows evidence of an activity far transcending anything ever seen under any other conditions, with an enormous amount of colloid secretion and a slight increase of the fibrous tissue. This observation is of the greatest importance, and is in entire accord with the views here advocated. Opportunities of obtaining the parathyroids *post-mortem* in cases of thyroidal disease are necessarily rare, and thyroids removed at operation are generally useless, as the parathyroid is almost invariably left behind.

I was fortunate enough to obtain the parathyroids from a girl, aged 18 years, with a small parenchymatous goitre of the ordinary type, who died from tuberculous meningitis. The gland presented large numbers of oxyphil cells and colloid in considerable amount, such as I have never seen in any other gland at this period of life. It is held by many that in parenchymatous

goitre the hypertrophy of the gland is compensatory for some deficiency in quality of the secretion, a view borne out by the fact that the subjects of goitre frequently show signs of myxœdema, and are benefited by thyroid feeding. If this be so, the fact that the parathyroid may share in this hypertrophy is further evidence of its close relation to the thyroid. Further observations upon this point will be of great interest.

Two diseases have been held to be specially related to deficiency of the parathyroid—exophthalmic goitre and tetany.

Exophthalmic Goitre.

I have already discussed the question of fat in the parathyroid, said by Humphry to be a pathological change met with in this disease, and it is unnecessary to go over the same ground again. One case of exophthalmic goitre is included in this series, from a female, aged 39 years, and the gland was found to be perfectly normal in the amount of fat present as well as in every other way; it showed no signs either of degeneration or of unusual activity.

A theory has been put forward that tetany is due to a failure of the parathyroid to neutralise a toxin of intestinal origin. One case was met with, in a child, aged 3 years, in which the glands showed no departure in any respect from the usual infantile type.

The Parathyroid in relation to the Embryonic Thyroid.

The parathyroids in man originate from the hypoblast of the third and fourth branchial clefts in close relation to the lateral thyroid diverticula, though separate from them even in the earliest stages. I have not myself seen sections of the thyroid at its earliest origin, but the figures in Wölfler's monograph (17) appear to depict a structure which closely resembles that of the infantile parathyroid. In Plate I, figs. 2 and 3, are illustrated a section of the thyroid of a fœtus, aged 3½ months, and one of a portion of a parathyroid in which the development of the acinar type of cell arrangement is remarkable. The acini contain no colloid nor do those of the thyroid at this early stage. The likeness between the two is very striking.

The structure of this thyroid is identical with that of the fœtal type of thyroid adenoma, and it was suggested by Horsley that this tumour might originate from a parathyroid imbedded in the thyroid. The possibility that this may be so, though incapable of direct proof, is supported by these specimens, and by the fact that, as shown by Forsyth (18), parathyroids are occasionally to be met with imbedded in the substance of the thyroid.

It cannot, however, be argued from these premises that the parathyroid is nothing more than a piece of embryonic thyroid tissue. All observers are agreed as to their separate origin and early differentiation from each other (see Prenant [19]), and although the parathyroid seems in almost all cases to approximate in structure to thyroid tissue as age advances, yet I have never met with an instance in which the whole gland was converted into colloid-containing vesicles. However far the change may have advanced, the distinctive structure of the parathyroid was always in evidence, and I have never found myself in doubt as to whether a given tissue was thyroid or parathyroid in nature. This is a consideration of great importance and one which requires further investigation in a large series of observations both human and comparative. For the present it must weigh very heavily against the view mentioned.

The Pituitary Body.

The likeness between the parathyroid and the pituitary body in certain points of their structure is very striking. Oxyphil cells are constantly present in the latter, and the occurrence of small masses of colloid is not infrequent. In many cases of the present series the pituitary body was examined, but although considerable variations of structure were met with, these could never be correlated in any way with the variations in the thyroid or parathyroid.

Conclusion.

Although I realise to the full the danger of attempting to draw conclusions as to function from anatomical facts, yet it seems to me that certain deductions may legitimately be drawn from a consideration of the foregoing facts.

Unfortunately, the usual order of scientific procedure has been reversed in the case of the parathyroids; experiments have preceded, instead of following, anatomical studies. Were the experimenters unanimous in their results, one would not venture to challenge their conclusions on histological grounds alone. But there is no such unanimity; the earlier experimenters made no extravagant claims for the importance of the glands, and the most recent workers interpret their results as showing that the glands, themselves unessential to life, are able to functionally replace the thyroid, and must therefore be regarded as a part of the thyroid apparatus.

Any collateral evidence is therefore admissible, and the results here brought forward, though based on very few cases, are yet entirely in accord with these latter views. They seem to me to allow of the following deductions being drawn: (1) The activity of the parathyroid increases as age advances; (2) the parathyroid normally forms a secretion indistinguishable microscopically from that formed in the thyroid; in diseases such as myxœdema and goitre this secretion is formed in greater quantity; it is possible, though not as yet proved, that the colloid may not be the only secretion formed by the parathyroid; (3) there is no histological evidence in favour of the view that the gland has a function of its own essential to life (a view disproved also by the most recent experiments), nor are there any grounds for supposing it to be the organ specially affected in any diseases.

To Mr. Shattock I offer my thanks for the interest he has taken in the work, and for much kindly advice and help.

Appendix.

A brief summary is here given of the cases upon which the foregoing pages are based.

The description given of the parathyroids in each case is the combined results of the examination of several sections from each gland, but in no case were serial sections prepared of each of the glands. For absolute accuracy of description this would, of course, be essential.

The terms "interstitial," "intracellular," "transitional," etc., are used for descriptive purposes, but it has been already explained that no very rigid interpretation can be placed upon

them. In every case the thyroid was examined, but where it was found to present no gross change, such as fibrosis, great diminution in amount of colloid, etc., it is omitted from the summaries. Minute changes of various kinds were often seen in the thyroid sections, but as they do not appear to have any bearing upon the subject of this paper they are not referred to.

CASE 1.—*Alcoholism, pulmonary tuberculosis.* Male, aged 26 years. Alcoholic history five years. Symptoms of phthisis three months. Peripheral neuritis. *Post mortem:* Extensive phthisis; hypertrophic fatty cirrhosis of liver; wasting of forearm and leg muscles. Parathyroids: Types 3 and 4; much interstitial fat; a few oxyphil cells; fair number of transitionals; some lumina containing colloid seen; no Scharlach preparation.

CASE 2.—*Diabetes.* Female, aged 37 years. Symptoms of diabetes three months. Six months pregnant. Died suddenly. *Post mortem:* Ante-mortem clot in pulmonary artery. Pancreas: Islands of Langerhans diminished in number and fibrosed. Thyroid: Extreme congestion; hardly any colloid present; the part from which the sections were taken, though not encapsuled, resembled in structure a fœtal adenoma. Parathyroids: Type 2; intense congestion of vessels; single oxyphil cells seen here and there, and all the cells are more or less of the transitional type; no colloid seen; interstitial fat scanty; no Scharlach preparation.

CASE 3.—*Sarcomatosis.* Male, aged 23 years. Symptoms seven weeks. Tumour in abdomen. Jaundice three days. *Post mortem:* Large masses of glands in mesentery, pressing on portal vein and bile-duct; glands in neck and post-mediastinum; masses in liver and spleen. Histologically the tumours were all round-celled sarcomata. Parathyroids: Mainly type 2; scattered single oxyphil cells; no colloid; interstitial fat scanty; no Scharlach preparation.

CASE 4.—*Primary carcinoma of liver.* Male, aged 44 years. Several months' history of diarrhœa and hæmatemesis. Enlarged nodular liver and ascites. *Post mortem:* Multiple growths in liver; columnar carcinoma with cirrhosis, probably primary. Thyroid: Congestion and active proliferation of cells; marked fatty change in cells lining vesicles; very little colloid present, in parts resembles adenoma. Parathyroids: Type 2; large

EXPLANATION OF PLATE IV,

Illustrating the communication upon "The Histology of the Human Parathyroid Glands," by Mr. W. L. Harnett. (P. 128.)

FIG. 1.—The parathyroid of a fœtus, aged 4½ months. All the cells have a clear cytoplasm, and are imperfectly parted into groups by fine strands of connective-tissue carrying capillaries. ¼-inch obj.; oc. 2.

FIG. 2.—The infantile type of parathyroid (from Case 8). The structure is precisely the same as that shown in the preceding figure. Zeiss obj. D.; oc. 2.

FIG. 3.—The parathyroid of a young adult (Case 18). The gland is more highly developed than the preceding, the breaking-up of the cell masses into columns by strands of connective tissue being much more pronounced. Oxyphil cells and intermediate types are scattered amongst the rest, though not to be distinguished under the magnification shown. Zeiss obj. A.; oc. 4.

FIG. 4.—The parathyroid from an aged subject (Case 36). There is a large amount of interstitial adipose tissue. An island of eosinophil cells may be recognised near the centre, by the darker colour in the photograph. Zeiss A.; oc. 4.

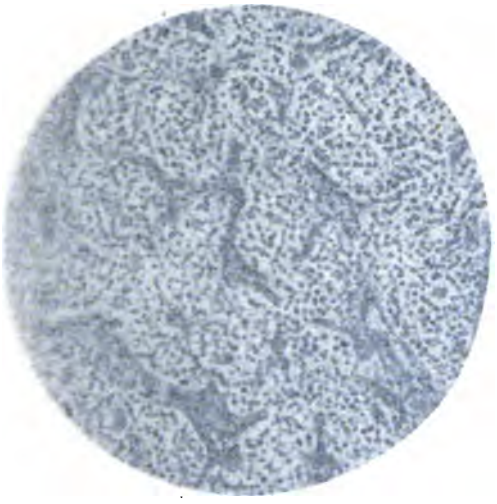

Fig. 1.

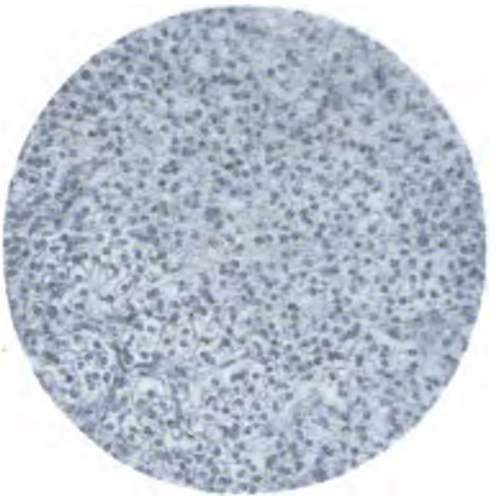

Fig. 2.

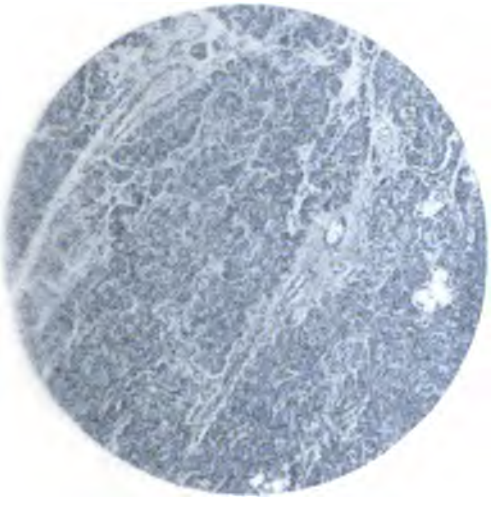

Fig. 3.

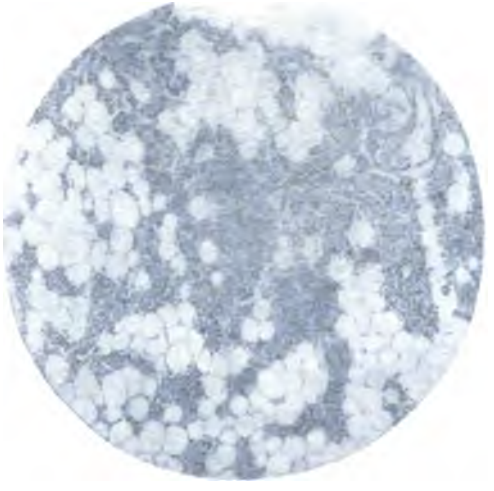

Fig. 4.

[illegible] LIMITED LONDON WALL

EXPLANATION OF PLATE V,

Illustrating the communication upon "The Histology of the Human Parathyroid Glands," by Mr. W. L. Harnett. (P. 128.)

FIG. 1.—A parathyroid showing the fourth arrangement of the cells—a portion of one of the glands from Case 22. Zeiss D.; oc. 2. Compare with Fig. 2.

FIG. 2.—The thyroid of a fœtus, 3½ months old. There is no colloid as yet present. The structure is similar to that of a fœtal adenoma of the thyroid. Zeiss D.; oc. 2. Compare with Fig. 1.

FIG. 3.—A group of oxyphil cells from Case 10, showing the fine granulation in the cytoplasm and the deeply-staining nuclei. Zeiss $\frac{1}{12}$; oc. 4.

FIG. 4.—A colloid-holding vesicle (from Case 10). Oxyphil and transitional types of cell are also shown. Zeiss D.; oc. 2.

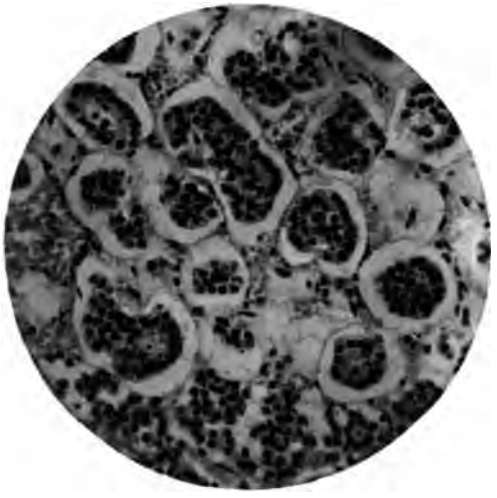

Fig. 1.

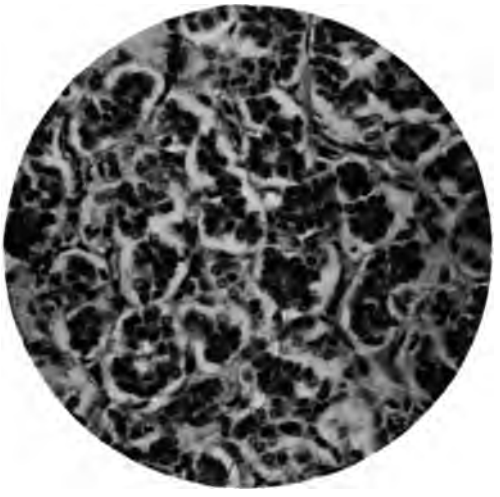

Fig. 2.

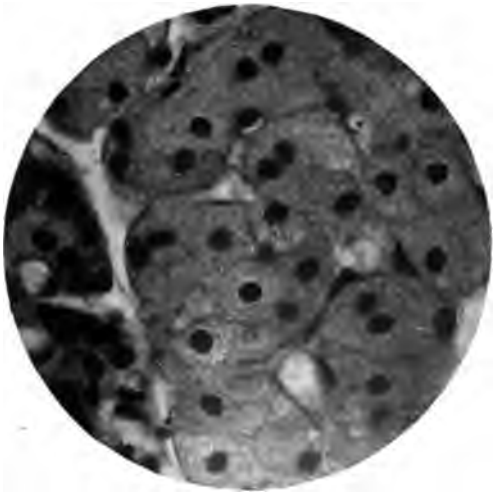

Fig. 3.

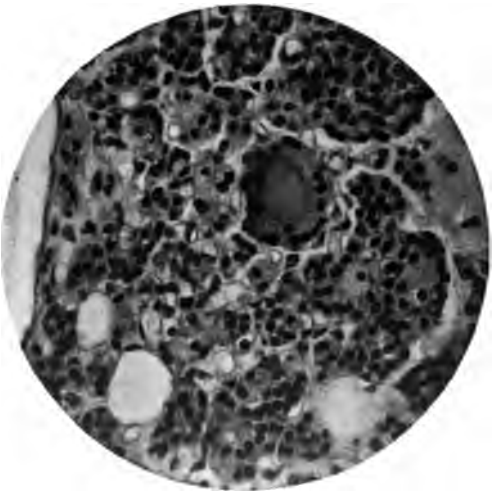

Fig. 4.

WATERLOW & SONS LIMITED, LONDON WALL.

masses of oxyphil cells in anastomosing columns; much colloid present. Scharlach: Much fatty change in cells and fair quantity of interstitial fat.

CASE 5.—*Chronic intestinal tubercle; fæcal fistula; marasmus.* Male, aged 14 years. Old tuberculous hip. Symptoms of tuberculous peritonitis one year. Operated upon twice, and adhesions separated; subsequently developed fæcal fistula. *Post mortem:* Profound emaciation; fæcal fistula found opening into ileum near cæcum; masses of caseous mesenteric glands; tubercular ulcers in small intestine and cæcum; caseous bronchial glands and tubercle at both apices; amyloid liver and spleen. Parathyroids: Marked fatty change; slight fibrosis; thickening of capillary walls, some of which were amyloid.

CASE 6.—*Tuberculous peritonitis.* Female, aged 10 years Symptoms three months. Very rapid emaciation. *Post mortem:* Tuberculous peritonitis, with many adhesions and purulent exudate; caseating bronchial glands, tubercular pleurisy, and tubercular periostitis of ribs. Parathyroids: Scharlach; very slight, fine, fatty change in cells; much interstitial fat; mainly type 2; a few scattered oxyphil cells; no colloid seen. The pituitary body contained a mass of colloid imbedded between the anterior and posterior lobes. Many intermediate types of slightly granular cells were present in the parathyroid, and altogether it was a very active gland for a child of this age.

CASE 7.—*Carcinoma of pylorus.* Female, aged 28 years. Two months' history. *Post mortem:* Carcinomatous ulcer just within pylorus; numerous secondary nodules in intestines and mesenteric glands; old tubercle at apices. Parathyroids: Types 2 and 3; intra-cellular fatty change marked (Scharlach); all the cells more or less oxyphil; colloid present in very small amount; an active gland.

CASE 8.—*Marasmus.* Male, aged 1 year and 2 months. Diarrhœa and vomiting two months. *Post mortem: Nil.* Parathyroids: Type 2; cells all with very translucent, non-staining protoplasm; no traces of oxyphil granulation, no colloid, and no fat.

CASE 9.—*Broncho-pneumonia.* History of broncho-pneumonia twelve days. Usual *post-mortem* findings. Parathyroids: Types 1 and 2; cells clear, but here and there traces of oxyphil granulation; no typical oxyphil cells; no fat or colloid.

CASE 10.—*Diabetes.* Female, aged 58 years. Symptoms five months. Died in coma. *Post mortem:* Pyelonephritis found, *nil* else. Thyroid: Distinct fibrosis, but colloid not reduced in amount. Parathyroids: Types 2 and 3; Scharlach; fat in large quantity, both interstitial and intra-cellular; enormous numbers of oxyphil cells, both scattered and in clumps; many lumina containing colloid seen, the oxyphil cells in some cases forming constituents of the walls of these; one clump of oxyphil cells contained two droplets of colloid in its midst (a most unusual occurrence). The colloid was present in enormous quantity; all the glands showed the same appearances.

CASE 11.—*General tuberculosis.* Female, aged 3 years. Wasting and pulmonary symptoms eight months, following measles. *Post mortem:* General tuberculosis—lungs, glands, intestines, spleen, and brain. Thyroid: Colloid scanty; proliferation of cells of vesicles. Parathyroid: Mainly type 3; most of cells clear, but traces of granularity seen in some; no colloid or fat.

CASE 12.—*Fractured spine.* Male, aged 57 years. Concussion and fractured spine. Death from bronchitis. No marked arterio-sclerosis. Thyroid: Well-marked fibrosis, with round-celled infiltration and collapsed alveoli; colloid not markedly diminished in amount. Parathyroids: Mainly types 2 and 3; a fair amount of interstitial fibrosis is present; some congestion; Scharlach; large quantity of fat, both interstitial and intra-cellular; much colloid and enormous numbers of oxyphil cells; colloid mostly near edges of gland, and one large space, probably a lymphatic, in the hilum, filled with colloid. Pituitary: Much colloid present.

CASE 13.—*Fractured skull.* Male, aged 64 years. Fractured skull and meningeal hæmorrhage. Arterio-sclerosis not marked. Thyroid: Well-marked interstitial fibrosis, very little colloid. Parathyroids: Type 3 predominated; enormous increase of interstitial fat, and all cells loaded with fat; no fibrosis; typical

characters of principal cells marked; large numbers of oxyphil cells; type 4 frequent; lumina containing colloid very numerous.

CASE 14.—*Vincent's angina; acute nephritis.* Male, aged 4 years. History three days. *Post mortem:* Sloughing ulcers of pharynx and acute nephritis. Parathyroids: Type 1 approximating to type 2; all cells principal, fat, colloid, and oxyphils completely absent.

CASE 15.—*Fractured skull.* Female, aged 11 years. Parathyroids: Types 1 and 2; no fat, oxyphils, or colloid.

CASE 16.—*Abdominal carcinoma.* Male, aged 63 years. Symptoms of carcinoma of stomach three months. *Post mortem:* Extreme emaciation; widespread affection of abdominal viscera, with carcinoma. Thyroid: Marked fibrosis; fair amount of colloid. Parathyroids: Mainly type 2; well-marked thickening of fibrous tissue-septa, but no definite intercellular fibrosis; enormous quantity of fat, both interstitial and intra-cellular; large numbers of oxyphil cells and traces of colloid.

CASE 17.—*Marasmus.* Male, aged 10 weeks. Appearances as in Case 8.

CASE 18.—*Intra-peritoneal hæmorrhage.* Female, aged 29 years. Operation for dermoid of ovary. Death from intra-peritoneal hæmorrhage. Parathyroids: Types 2 and 3; fat and oxyphil cells plentiful; no colloid seen in the glands, but one large mass seen lying in a lymphatic.

CASE 19.—*Bronchiectasis.* Male, aged 12 years. Bronchiectatic signs three to four years. Very wasted. *Post mortem:* Bronchiectasis in both lungs; no tubercle. Thyroid: Some increase of interstitial fibrous tissue; very little colloid present. Parathyroids: Types 1 and 2, some areas of type 3; fat present in small amount, wholly intra-cellular; a few oxyphil cells, no colloid seen; the pituitary body contained a large mass of colloid at junction of anterior and posterior lobes.

CASE 20.—*Lymphocythæmia.* Female, aged 60 years. Symptoms of anæmia three months; no oral sepsis. *Post mortem:* Dilated flabby heart. Organs showed usual leukæmic changes.

Parathyroids: All were very large (three times usual size), and contained enormous quantities of interstitial fat; all cells loaded with fat; types 1 and 2; oxyphil cells very numerous; small quantity of colloid seen; intermediate types of cell very frequent throughout the glands. Thyroid: Normal except for some œdema. Pituitary: Anterior lobe much enlarged, and large quantity of colloid present in well-formed lumina.

CASE 21.—*Marasmus.* Male, aged 9 months. Wasting, etc., one to two months. Except for faint traces of granularity in some of the cells the gland presented the usual simple type, colloid, fat, and oxyphil cells being entirely absent.

CASE 22.—*Fractured base of skull.* Male, aged 31 years. Died day of admission. *Nil* else *post mortem.* Thyroid: Marked fibrosis and breaking up of vesicles, with colloid lying free in the interstitial tissue. Parathyroids: Type 4 very frequent; enormous interstitial infiltration with fat, separating the cell columns widely; cells loaded with large droplets; oxyphil cells plentiful, some colloid seen in lumina.

CASE 23.—*Addison's disease.* Male, aged 33 years. Symptoms of Addison's disease three months. Well-marked pigmentation of skin of face, hands, and mouth. *Post mortem:* Fibro-caseous tuberculosis of adrenals; general peritoneal tuberculosis; calcareous nodules in lungs; deposits in liver. Thyroid: Slight fibrosis; colloid abundant. Parathyroids: Types 2 and 3; moderate amount of fat, interstitial and intra-cellular; a few scattered oxyphil cells, very poorly developed; no colloid seen. Pituitary: Contained large quantity of colloid.

CASE 24.—*Diabetes.* Male, aged 25 years. Symptoms two months; very rapid wasting. *Post mortem: Nil;* pancreas normal microscopically. Parathyroids: Type 2; congestion of vessels very marked; moderate amount of fat (both forms); fair number of oxyphils; no colloid seen.

CASE 25.—*Marasmus.* Male, aged 15 weeks. History of diarrhœa, vomiting, and wasting for about one month. Thyroid: Most of the vesicles collapsed and empty; colloid scanty. Parathyroids: The faintest possible traces of granularity were seen

in some of the cells; in other respects it was the typical infantile gland.

CASE 26.—*Fractured skull.* Male, aged 40 years. Death a few hours after accident. Organs healthy. Parathyroids: Types 3 and 4; a high type of parathyroid; fatty change well marked; colloid in large quantity, mostly in lumina; oxyphil cells plentiful, as also intermediate cells.

CASE 27.—*Marasmus.* Female, aged 11 months. Signs of congenital syphilis; marasmic since birth. Usual infantile type of gland.

CASE 28.—*Diabetes.* Male, aged 43 years. Diabetic symptoms two and a half years; death in coma. *Nil post mortem.* Parathyroids: Types 2 and 3; much broken up by the abundance of interstitial fat; large amount of intra-cellular fat; slight congestion; abundant oxyphils; large amount of colloid in lumina, some of which have oxyphils amongst the cells lining them.

CASE 29.—*Péritoneal carcinomatosis.* Male, aged 44 years. Gastric symptoms nine months. *Post mortem:* Carcinoma of stomach with extensive secondary deposits. Thyroid: Slight fibrosis. Parathyroids: Type 3; moderate amount of interstitial fat; enormous quantity intra-cellular; oxyphils abundant, no colloid.

CASE 30.—*Diabetes.* Male, aged 42 years. Symptoms one year; death from coma. *Nil post mortem.* Thyroid: Slight interstitial fibrosis; some congestion; colloid normal in amount. Parathyroids: Type 3; congestion marked; enormous quantity of fat (both forms); fair number of oxyphils; no colloid.

CASE 31.—*Exophthalmic goitre.* Female, aged 39 years. Enlarged thyroid and slight exophthalmos twenty years. Occasional exacerbations, with cardiac symptoms. Death in coma. Thyroid: Mostly not typical; some parts showed proliferation of cells, with sub-columnar type of epithelium and absence of colloid, but most of the gland was normal, with abundant colloid. Parathyroids: Types 1 and 2; slight congestion; moderate quantity of fat; fair number of oxyphils and

many intermediate cells; a very small quantity of colloid seen. The pituitary body contained a good deal of fat.

CASE 32.—*Hypostatic pneumonia; bed-sores.* Male, aged 73 years. Amputation after accident. Death fourteen days later from causes as above. Thyroid: Considerable fibrosis, but fair amount of colloid. Parathyroids: Types 2 and 3; enormous quantity of both forms of fat; great numbers of oxyphil cells, which seem to contain less fat than the others; no colloid seen.

CASE 33.—*Broncho-pneumonia.* Female, aged 9 months. Pneumonia three days, following whooping-cough. *Post mortem:* Diffuse broncho-pneumonia. Thyroid contained no colloid. Parathyroids: Types 1 and 2; extensive hæmorrhages were present, separating the cells and forming spaces lined by regular layers of clear principal cells; some of these spaces are in the centres of masses of cells; some traces of oxyphil protoplasm; typical oxyphils, fat and colloid absent.

CASE 34.—*Tetany and intestinal toxæmia.* Male, aged 3 years. Convulsions twelve hours after food-poisoning, with diarrhœa, etc. Death twelve hours later. *Post mortem:* Congestion of Peyer's patches; acutely inflamed mesenteric glands. Parathyroids: Types 1, 2, and 3 represented; congestion marked; minute traces of fat (both forms) visible only with $\frac{1}{12}$th in. objective; traces of granulation in some cells, but most were quite clear; no colloid.

CASE 35.—*Spina bifida; rupture; sepsis.* Male, aged 2 days. Ruptured meningo-myelocele. Septic meningitis. Thyroid: Intensely congested; small amounts of colloid in some vesicles. Parathyroids: Type 1, with intense congestion, and here and there hæmorrhages; otherwise corresponds to the usual infantile type.

CASE 36.—*Strangulated hernia; cerebral thrombosis.* Male, aged 85. Cerebral thrombosis subsequently to operation upon hernia. Thyroid: Marked fibrosis, but colloid abundant. Parathyroids: Large size, mainly due to enormous increase of interstitial fat; all cells loaded with fat; oxyphils very numerous;

colloid abundantly present in lumina, and a mass also seen lying in a lymphatic in the connective tissue; no fibrosis made out.

CASE 37.—*Broncho-pneumonia.* Male, aged 16 months. History one week; bilateral. Parathyroids: The usual infantile type; traces of granulation in some of the cells; slight congestion.

CASE 38.—*Carcinoma of prostate.* Male, aged 67 years. Thyroid: Normal; no fibrosis. Parathyroids: Rather large; type 2; interstitial fat in fair amount; no Scharlach preparation; large number of oxyphils and transitionals; no colloid seen.

CASE 39.—*General peritonitis.* Male, aged 23 years. Perforated gastric ulcer. General peritonitis. Parathyroids: Types 1 and 2; congestion marked; interstitial fat in moderate amount; no Scharlach preparation; a few scattered oxyphils and some transitionals; several small masses of colloid between the cells, but none seen in lumina.

CASE 40.—*Tubercular meningitis; parenchymatous goitre.* Female, aged 18 years. Thyroid enlarged to about twice its normal size; no encapsuled tumours. Death from tuberculous meningitis. Thyroid: Normal thyroid structure, but many of the vesicles much enlarged; colloid abundant. Parathyroid: Type 2; moderate amount of interstitial fat; no Scharlach preparation; numerous oxyphils in clumps and scattered, and many transitional cells; colloid in fair amount, in lumina as well as between the cells; no other gland of the present series showed as much colloid in cases at the same period of life.

BIBLIOGRAPHY.

1. *Rogowitch.*—'Archiv. de Phys.,' 1888.
2. *Edmunds.*—'Journ. of Physiology,' 1895.
3. *Edmunds.*—*Ibid.*, 1896.
4. *Edmunds.*—'Journ. of Path. and Bact.,' vol. iii, 1896.
5. *Kohn.*—'Arch. f. Mikr. Anat.,' Bd. xliv, 1895.
6. *Kohn.*—*Ibid.*, Bd. xlviii, 1897.
7. *Vincent and Jolly.*—'Journ. of Phys.,' vol. xxxii, 1904, p. 65.
8. *Vincent and Jolly.*—*Ibid.*, vol. xxxiv, 1906, p. 295.
9. *Vincent.*—'Lancet,' August, 1906, p. 430.
10. *MacCallum.*—'Medical News,' October 31st, 1903.
11. *MacCallum.*—'Brit. Med. Journ.,' November 10th, 1906.

12. *Kishi.*—'Virchow's Archiv,' Bd. clxxvi, 1904, s. 260.
13. *Welsh.*—'Journ. of Anat. and Phys.,' vol. xxxii, 1898, p. 380. (This paper contains a bibliography up to 1898.)
14. *Welsh.*—'Journ. of Path. and Bact.,' vol. v, 1898, p. 202.
15. *Forsyth.*—'Lancet,' January 19th, 1907.
16. *Gley and Nicholas.*—'Compt. Rend. de la Soc. de Biol.,' No. 11, 1895.
17. *Wölfler.*—Berlin, 1880.
18. *Forsyth.*—'Journ. of Phys.,' December, 1906.
19. *Prenant.*—'La Cellule,' t. 10.
20. *Humphry.*—'Lancet,' 1905, vol. ii, p. 1391.
21. *Shattock.*—'Brit. Med. Journ.,' 1905, vol. ii, p. 1694.

14. *The parathyroid glands in man.*

By David Forsyth.
From the Physiological Laboratory, Guy's Hospital, and the Pathological Laboratory, Charing Cross Hospital.

(With Plates VI and VII.)

Introduction.

Although it is a full quarter of a century since the parathyroid glands were first described, it cannot be said that their functional importance has even now been appraised. This unsatisfactory state depends on no lukewarm investigation, for not only in this country, but in Germany, France, Sweden, Italy, the United States, and Canada, numbers of physiologists and pathologists have been busy in their attempts to dissipate the mists that enshroud these structures. Unfortunately their efforts have, with advancing years, tended rather to confuse the issue than to effect a solution. The explanation of this result is not far to seek.

The essential points concerning the parathyroids—their distribution throughout the animal kingdom, their anatomy, their histology, and their topical relations to the thyroid gland—have never been established, and yet in spite of this ignorance, which necessarily leaves operations on the glands beset with difficulties, almost all the work hitherto accomplished has been by way of attempted removal of the organs from domestic animals. In the absence of these fundamental data, such a line of research

was warranted to lead to contradictory ends. Until 1891 the existence of the parathyroids had not been practically recognised, and all the thyroidectomies performed before that year are valueless to our present purpose. From 1891 to 1895 the extirpation of the glands proceeded on the assumption, fathered by Sandström, that there were but two parathyroids in each animal. At the latter date Kohn (2) maintained that in the dog, the cat, and the rabbit there were customarily four glands all told—two on each side. One, the external, lay in a fairly accessible position on the lateral aspect of the thyroid lobe, while the other, the internal, was hidden away between the median surface of the thyroid and the trachea. It followed, therefore, that the operation, which before 1895 was termed a complete parathyroidectomy, must often have been merely a partial parathyroidectomy, and this fallacy detracts considerably from the results obtained. From 1895 to the present time Kohn's dictum has been accepted, and every operator has been satisfied provided he was able to remove two glands from each side of the neck.

It will be shown in a future paper embodying the results of a detailed macroscopic and microscopic examination of nearly eighty different animals, including about seventy different species, that the parathyroids are not constant in number, that there is often an inequality in their numbers on the two sides of the neck, that their anatomical relations vary between wide limits, and that it is by no means uncommon for their total number to exceed four.

The fuller consideration of these points, and their bearing on the operation of parathyroidectomy as hitherto practised, will be postponed for future discussion, when they can be correlated with other evidence of a similar import.

Notice, however, must be taken of a tendency on the part of many to accept the evidence provided by experimental ablation as conclusive proof of the vitally essential nature of these minute bodies, and already the clinical aspects of the subject are receiving attention from both physician and surgeon. The question is not a *chose jugée*. I cannot find in the literature any evidence to warrant us in going further than to entertain the possibility—not the probability—of these small and varying glands possessing an importance unequalled, bulk for bulk, by any other organ in the body. In a series of three papers, of

which the present is the first, there will be put forward facts, gathered along different and less fallacious channels than those hitherto followed, which go to show that we should be wise to reject the claims for importance advanced by so many on behalf of the parathyroids. On the other hand, it will be equally impossible to share the camp of those who maintain the exclusively embryonic nature of the parathyroids, seeing in the organs no more than a mere "rest" of inactive thyroid tissue. While assuming a position more in accord with the latter view, it will be shown that, except in the earliest period of life, the parathyroids take an active part in the processes of the body, though their importance has not that ascribed to them.

The present essay will be confined to a consideration of the parathyroid glands as found in a series of fifty-eight human subjects, of all ages from birth to old age, and dead from a variety of diseases. It will be divided into the following five sections:

I. Naked-eye anatomy of the parathyroids.

II. Age incidence and relation of the parathyroids to accessory thyroids.

III. Histology of the parathyroids.

IV. Secretion of the parathyroids.

V. Conclusions.

I. Naked-eye Anatomy.

Historical.—A record of the important facts elicited by past investigation of these glands in man can be summarised in brief space. Sandström (5), after examining about fifty bodies, stated that the "glandulæ parathyroidæ" occurred to the number of two on each side of the neck, lying on the posterior surface of the thyroid lobe and separated from each other by the inferior thyroid artery and from the thyroid itself by interposed connective tissue. Kohn (2) and Müller (4) investigated the glands, and the latter, from a search in over twenty cases, was impressed with the difficulty of finding the structures, and hesitated to formulate any opinion on their frequency of occurrence. Welsh (7), in a careful and instructive paper, stated that as a general rule there were two parathyroids on each side, and

cases in which there were fewer he explained either by assuming that the examination had been imperfect or as the result of an intimate connexion between the two bodies whereby they appeared to the naked eye as one mass.

He found them to measure on an average 6–7 mm. by 3–4 mm. by 1·5–2 mm., to take the form of flat, ovoid plates or discs, and he notes that in childhood they appear to be comparatively larger than in later years. As regards their position, he finds that they are very constant relative to each other, one being almost invariably situated above and behind the other. He therefore distinguishes a "posterior-superior" and an "anterior-inferior" respectively. The former, which is the more easily found, lies "almost invariably" on the posterior wall of the œsophagus or pharynx at, or near, the junction of the two, and is quite separate from the thyroid tissue. He has noticed the occurrence of both parathyroids and accessory thyroids in this position. The other gland he finds not constant in position, though showing a certain rude symmetry with its fellow on the opposite side. It lies either closely applied to the lower edge of the thyroid lobe or immediately below the thyroid or some distance below it.

It will be observed that Welsh, who believes the parathyroids to be functionally distinct from the thyroid, does not so much as suggest the possibility of more than four parathyroids existing in any one subject, and though he appears in some cases to have failed to find more than one on each side he prefers to ascribe the result to an oversight rather than to a real absence of one gland.

Sandström (5) did not always succeed in discovering four parathyroids in each body. In five cases (10 per cent. of his total) he found but one on each side, and in two cases (4 per cent.) only one altogether.

Shattock (6) mentions a lens-shaped mass of parathyroid tissue pendent from the lower border of the thyroid isthmus of a young man, but he did not examine for other glandules.

Quite recently MacCallum (3) has investigated the subject, and states that four is the usual number present, two occurring in apposition to each thyroid lobe, though occasionally three, two, or even one gland only could be found. In only 56 per cent. of his cases did he find four; of the remainder, 16 per cent.

had three, 25 per cent. two, and 5 per cent. only one parathyroid. He states that not all his specimens were identified by microscopic examination, and as will be shown this at once opens up a source of error. He finds that great diversity exists with regard to the position of the glands, and believes that only the most general statements are warranted on this point. The commonest site, however, is along the posterior border of the thyroid lobe. He failed to discover any parathyroid embedded in the substance of the thyroid gland. There is nothing in MacCallum's paper suggesting that his dissections were carried to any distance from the thyroid gland.

Author's investigations.—Since the parathyroids admittedly show so extensive a variation in position, it is clear that no observer can afford to restrict his attention to the immediate neighbourhood of the thyroid gland, but must extend his search to wide limits, and the possibility of meeting with more parathyroids than has hitherto been recognised must be entertained. Sandström (5) believed that they always occurred in the immediate neighbourhood of the thyroid gland. Welsh (7) recognised a somewhat greater latitude of distribution, but appears not to have examined the connective tissue very far from the thyroid, and, as has been shown, a similar criticism applies to MacCallum's work.

Again, previous observers, while noting the variability in appearance of the glands, quite failed to recognise the possibility of parathyroid tissue occurring associated with lymphatic glands or thymic residues, and they therefore omitted to subject to microscopical examination such glands as raised no suspicion of their parathyroid nature. As will be pointed out this is a serious omission, for a parathyroid nodule is not infrequently associated with other tissues without the macroscopic appearance of the whole suggesting its twofold nature. To guard against these probable sources of error a method of search sufficiently extensive and detailed to obviate them was adopted, and the procedure was as follows:

The subjects, which were not specially selected, except in so far as to include a variety of diseases, were examined as soon after death as possible. A median incision was carried from the chin to the sternum, the sterno-hyoid, the sterno-thyroid, omo-hyoid, and, if necessary, the sterno-mastoid muscles were

reflected and the thyroid gland exposed. This, or one of its lobes with the corresponding isthmus, was freely removed, together with all connective-tissue, fat, etc., in the neighbourhood, and a careful search for glandular bodies made in the tissues remaining from the jaw to the sternum. The structures excised were at once dissected, and every gland without exception kept for future microscopic examination. The thyroid itself was carefully cleaned and all bodies found on its surface retained for sectioning. A drawing was made of the thyroid to record the position, size, appearance, etc., of the specimens which were then placed in one of various fixative fluids, precautions being observed to facilitate the identification of each at later stages. The thyroid itself was fixed entire for twenty-four hours and then cut into thin slices 2–3 mm. thick, and the cut surfaces of each slice examined with a magnifying lens. Every piece which showed at any place any departure from the usual vesicular appearance of the gland was retained for future microscopical examination.

This detailed examination ensured that, with the exception to be noted immediately, no parathyroid either imbedded in the thyroid, or on its surface, or in its neighbourhood could escape detection, while few, if any, lying between jaw and sternum would be overlooked.

The exception referred to is that of the parathyroid which Welsh terms the posterior-superior parathyroid. As has been stated, he has shown that this bears a very constant relation to the œsophagus and pharynx, lying almost invariably on the posterior wall at, or near, the junction between the two. Accepting this statement, attention was restricted to parathyroids other than this constant one.

The following was the histological technique adopted. As a fixative fluid either Zenker's solution, Mann's fluid, saturated aqueous solution of perchloride of mercury or formalin (10 per cent. commercial formol in normal saline) was used. Of these, Zenker's solution and formalin gave the best results, the latter especially producing well-fixed specimens and possessing the further advantage of fixing thyroid and accessory thyroid tissue better than any other reagent. The specimens, after dehydrating in successive strengths of alcohol and clearing in oil of cedar-wood, were imbedded in paraffin (M.P. 52° C.) and cut on a

Cambridge microtome, the sections varying from 2 μ upwards. In staining, Mayer's acid hæmalum and ·1 per cent. watery eosin gave the best results, but it was necessary to afford full opportunity to the acid stain to bring out the differences between the cells to be described below. v. Giesen's stain or Bismarck-brown was sometimes used as a counter-stain, the former and picro-nigrosin for the connective-tissue stroma, and Mann's methyl-blue-eosin mixture (long and short methods) for vascular elements. The long method for staining the contents of blood-capillaries seems not to be as widely known as it deserves. Though there is some little trouble in acquiring the method, its results are excellent, and for tracing capillaries far superior to any injection masses. In my experience, however, the brilliant results tend to fade.

Number of parathyroid glands.—In attempting to enumerate the parathyroid glands we are met at the outset by a difficulty. It is not uncommon, especially in infants, to find degrees of lobulation in a gland varying from a slight constriction to a complete separation into two bodies, and a line has to be drawn between a marked degree of lobulation of one body and an apposition of two separate glands. This distinction is sometimes difficult, and therefore the following criterion was adopted. When the macroscopic appearance suggested two contiguous glands and the microscopic examination disclosed a complete septum of connective tissue between the two, the specimen was reckoned as two. When, however, the dual nature to the naked eye was not confirmed on section, the organ was treated as single. This method gives the fairest results.

The number of parathyroids in man is very variable. The following numbers are exclusive of the posterior-superior parathyroid (Welsh), and it is therefore probably necessary to add one to the figures given, which in each instance refer to those found on one side of the neck.

In somewhat less than half the cases only one parathyroid was present. With the above-mentioned allowance this agrees with the results of previous observers, who state that two on each side is the customary number. The cases, however, were not few in which a larger number occurred. In more than a quarter of the cases two parathyroids were found. In five cases there were three parathyroids, and in two cases four. Even this

was not the limit, for in each of two infants five parathyroids were found, and in one infant six.

On the other hand, the same detailed examination was made in seven subjects with a negative result. It is interesting to note that in five of these seven the thyroid gland itself was without those peaks and processes which usually characterise its outline, and without which it appears as a shapeless lump. Reference will be made to this relation in a future paper, when the nature of the parathyroids is discussed.

Allowing for the posterior-superior parathyroid, the bodies were never absent in the above series. This gland, however, is not absolutely constant, and it is possible that in some of the seven above-mentioned subjects no parathyroid existed. Other observers have failed to find any gland attached to a thyroid lobe, and it is unsatisfactory to conclude that this failure necessarily implies imperfect search. Sandström, as has already been mentioned, found no more than one parathyroid on a side in five of his cases, and in two discovered but one altogether, and if we admit, as we must, that occasionally only one exists, we are not justified in concluding that where none is found there has been careless dissection.

The above results summarised in tabular form appear thus:

No. of parathyroids.	Percentage of cases.
0. (1)	11·7
1. (2)	45·0
2. (3)	27·0
3. (4)	8·3
4. (5)	3·3
5. (6)	3·3
6. (7)	1·6

(The figures in brackets are those after allowing for the posterior-superior parathyroid.)

Position.—The almost invariable occurrence of a parathyroid behind the œsophagus or pharynx has already been referred to more than once. Except for this one gland the other parathyroids are far from invariable, though they show a predilection for certain sites. If the thyroid is removed enclosed by its surrounding connective tissue freely dissected out of the neck, all the parathyroids will in most cases be in the mass excised. It is only uncommonly that the glands are set at any consider-

able distance from the parent organ, and then the direction taken is towards the thorax rather than upwards to the head. Parathyroids never occur superficial to the sterno-hyoid, sterno-thyroid, or omo-hyoid muscles, and they are invariably wrapped in the same compartment of the deep cervical fascia as is the thyroid gland.

An analysis of the sites of occurrence of the glands shows that the most frequently selected position is at, or near, the junction of the middle and inferior thirds of the thyroid lobe, lying near the posterior border of the organ. The two neighbourhoods next most popular are, firstly, the posterior border at, or near, the junction of the upper and middle thirds, and, next, around the inferior pole. In the last position they may lie some distance away from the thyroid. The relative numbers of parathyroids found at these three places were as 4 : 3 : 2.

Excluding the above areas, there is none at which parathyroids are common, though they may occur in many other localities. Of these less frequent sites first mention must be made of the interior of the thyroid gland, where it is usually the lower half that harbours them. Only once was a parathyroid entirely sunk in the anterior part. In this subject three large parathyroids were found, all deeply buried, one lying near the superior pole and two near the inferior. When buried in this way the glands form an obvious contrast on section to the surrounding tissue, being pale, firm, and encapsuled, and generally standing out elevated from the cut surface. These features, however, are not sufficient for identification, as portions of thymic tissue, similarly circumstanced and characterised, are found from time to time.

Around the prominence of the anterior pole of the thyroid the glands occasionally seek shelter. In two cases only did any parathyroid appear on the tracheal surface of the thyroid (*i. e.* between the thyroid and the trachea). In one of these (a child, aged 7 years) three parathyroids were clustered together near the lower end, while in the other there was the interesting association of a parathyroid, guarded on each side by an accessory thyroid—the only occasion on which an accessory thyroid lay on this surface.

The position mentioned by Shattock (6) was noted once.

No parathyroid was found at any distance superior to the thyroid, but sections were cut of a large number of glands dis-

EXPLANATION OF PLATE VI,

Illustrating the communication upon "The Parathyroid Glands in Man," by Dr. David Forsyth. (P. 154.)

FIG. 1.—Parathyroid gland, showing closely-massed cells and complete absence of interstitial fat.

FIG. 2.—Parathyroid gland with a considerable amount of interstitial adipose tissue.

FIG. 3.—Parathyroid gland, showing two large and other small groups of resting cells distended with oxyphil granules.

FIG. 4.—Parathyroid gland with droplets of colloid secretion among the gland cells.

FIG. 5.—Parathyroid gland with vesicles enclosing colloid.

FIG. 6.—Parathyroid gland in an advanced stage of vesicle formation.

FIG. 1.

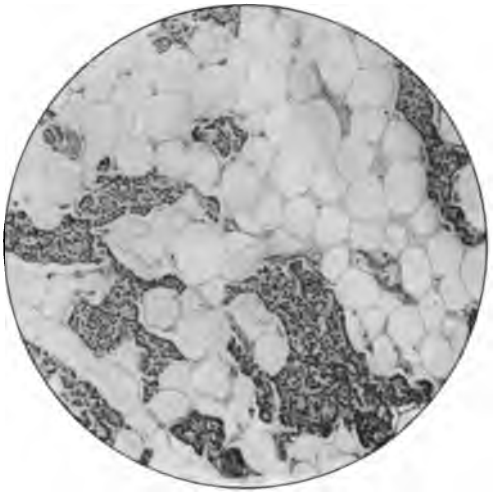

FIG. 2.

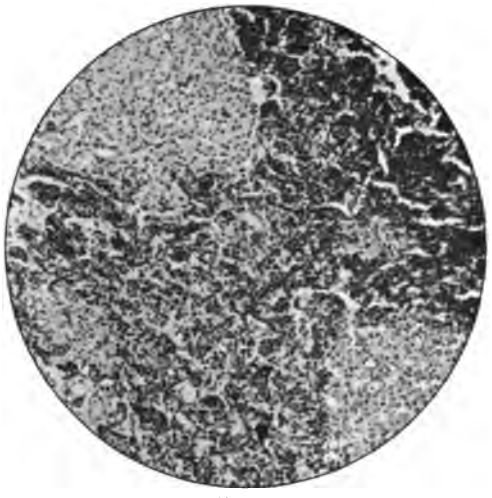

FIG. 3.

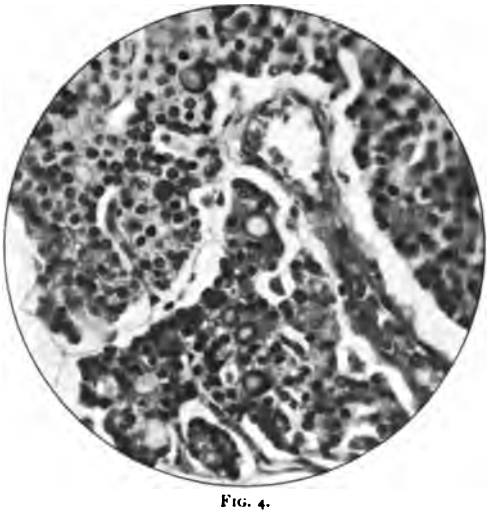

FIG. 4.

FIG. 5.

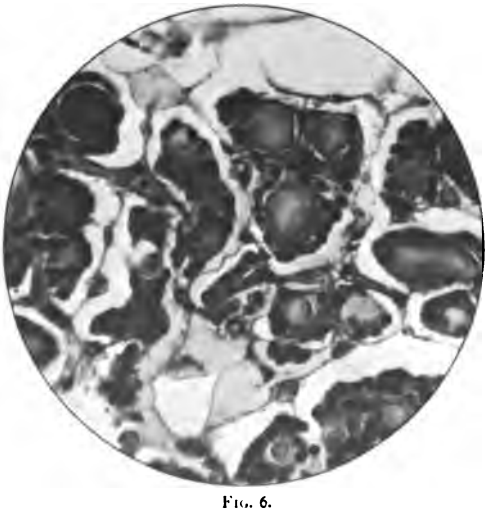

FIG. 6.

Bale, Sons and Danielsson, Ltd.

EXPLANATION OF PLATE VII,

Illustrating the communication upon "The Parathyroid Glands in Man," by Dr. David Forsyth. (P. 154.)

FIG. 1.—Parathyroid gland, showing stages in the arrangement of cells to form vesicles.

FIG. 2.—Parathyroid gland, showing a small lymphatic vessel containing colloid.

FIG. 3.—Portion of the same, more highly magnified, showing a lymphatic vessel lined by flat endothelium and containing colloid.

FIG. 4.—Parathyroid gland with many lymphatics distended with colloid secretion. On serial section the smaller vessels were seen to open into the large one in the centre of the field.

FIG. 5.—Parathyroid gland with infantile characters.

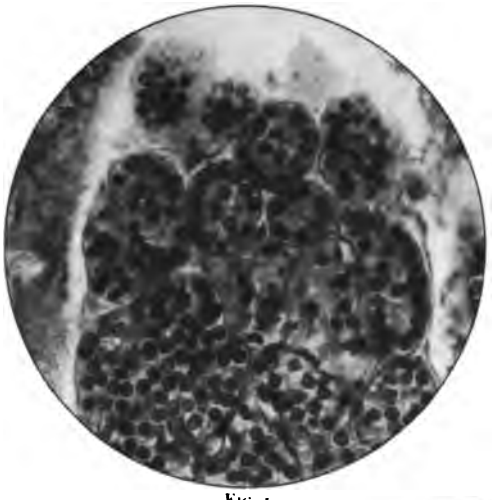

FIG. 1

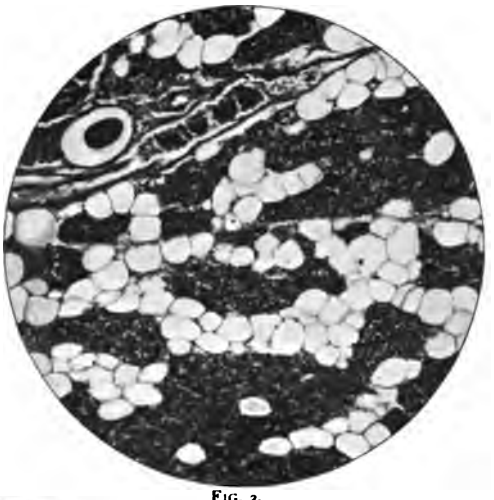

FIG. 2.

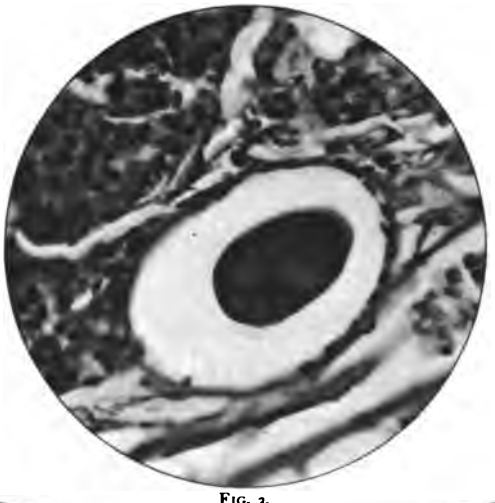

FIG. 3.

FIG. 4.



FIG. 5.

dale, Sons and Danielsson, Ltd.

sected out from behind the manubrium sterni, and one of these proved to be a parathyroid.

Appearance, etc.—The parathyroid cannot be identified with certainty, except by microscopical examination. The truth of this statement has impressed itself over and over again in the course of this research, and it goes far to explain why the results here recorded differ from those of previous observers. A perusal of many original papers on the subject leads to the belief that in previous research the glands whose features were those of a parathyroid were sectioned, while those which appeared not to be parathyroid were passed by. This necessarily led to error, for it is only by microscopical examination of every glandular body found that all the parathyroids can be enumerated. Many specimens in the present series of what seemed, on macroscopic examination, to be either lymphatic gland, accessory thyroid, or fat disclosed in the event parathyroid structure, and, *per contra*, glands whose features suggested a parathyroid nature proved to be lymphatic gland, thymic residue, or accessory thyroid. Not only is there this possibility of confusion, but parathyroid and accessory thyroid may be found in the same gland, and on two occasions parathyroid and thymic residue were similarly associated, while in one case parathyroid, thyroid, and thymic tissues were bound up together.

If a parathyroid present a fairly typical appearance, and is found at one of its commonest sites, it may be identified with a very high degree of probability. In other words, when a typical parathyroid is seen there is no reasonable doubt of its nature, but with many examples, especially of the smaller glands and those associated with other structures, nothing less than the microscope will reveal their nature.

In its most characteristic form the parathyroid appears as an elongated, ovoid, slightly flattened body of a pale pink hue, and with a smooth, glistening surface on which ramify a few branching vessels. One or both its tapering ends have the appearance of ordinary adipose tissue, and there is frequently a line of demarcation between the yellow and the pink. In two examples the gland was divided longitudinally into equal parts of parathyroid tissue and fat respectively. Those glands which have not been in contact with the thyroid are usually not flattened. In consistence the parathyroid is soft.

Sometimes the gland presents few features except those of a nodule of fat well vascularised, and this variation is specially liable to escape unrecognised. In others fat is entirely absent, and the appearance may be that of a lymphatic gland or thymic residue; these specimens are firmer in texture and have an uniformly pale, pinkish-white colour. In yet others the gland has a dark-brown hue, suggesting an accessory thyroid, while rarely it loses all its peculiarities, and appears as an absolutely black gland, as deeply coloured as many adult bronchial glands.

The aspect of those which are conjugated with thyroid, thymic, or lymphatic tissue varies with the amount of each structure present, but, as a rule, the parathyroid tissue is proportionately small in amount, and the features are those of the other organ.

The size varies from little more than a pin-point up to 2·5 cm. by ·5 mm. by ·4 mm. The length depends greatly on the amount of fat attached to the poles. In infancy they are generally small, but they are not necessarily larger in adults than in children. There is no constancy in the total volume of all the parathyroids present in different adults. Not infrequently, where one large parathyroid was found two or three others equally large were discovered, and one individual will have ten or twenty times as much parathyroid tissue as the next examined.

II. Age Incidence and the Relation of the Parathyroids to Accessory Parathyroids.

The literature contains no comment on the relation between the number of parathyroids present and the age of the subject, yet an investigation of this point is important in the highest degree to the settlement of the embryonic character of the glands. If they be embryonic thyroid tissue, and can, and do under suitable stimulus, become transmogrified to the adult structure, we should meet with the embryonic glands more often in the earlier years of life than later, and conversely accessory thyroids—it is to accessory thyroids that the parathyroids would become changed—should increase *pari passu* with the disappearance of the parathyroids.

A reference to the ages of the subjects examined shows decisively that parathyroids are in greatest number in the first year of life, and that from that period onward to old age they

are found with progressively decreasing frequency. Under one year they occur, generally in clusters, to the number of two, three, four, five, or even six, separated from each other by their respective connective-tissue envelopes. These clusters almost invariably lie in one of the two commonest sites mentioned above. The three instances when five, five and six parathyroids were found were all in infants under one year. Between the first year and the tenth the greatest numbers found were three and four. Above ten years two was the maximum. These numbers, of course, refer to one side of the neck only. No subject under twenty years of age was without a parathyroid; above twenty they might be absent.

In an infant, aged 7 months, five parathyroids were found on one side and six on the other—a total of eleven.

Relation to accessory thyroids.—An examination of the age incidence of the accessory thyroids was no less instructive. Here arises the same difficulty of enumeration that appeared in connection with the parathyroids. Every transition can be found between an eminence of thyroid tissue on the main gland and a completely separated accessory thyroid, and the same criterion must be adopted in doubtful cases. Berry (1) speaks of encapsuled masses of thyroid tissue which have been extruded from the gland, and draws a distinction between them and what he styles "true accessory thyroids of congenital origin." But this division is undesirable to make and impossible to apply. Nodules of true thyroid tissue occur at varied distance, near and far, from the thyroid, and all of them must be accepted as true accessory thyroids. There is no practical difference between the two kinds, and, as far as I know, there is no evidence of the active extrusion of a mass of thyroid tissue by the parent gland. The term "accessory thyroid" is applied here to all masses of thyroid tissue which are macroscopically and microscopically separate from the main gland.

Such accessory thyroids are admitted to be of common occurrence, and they have been described as lying within the wide limits of the base of the tongue and the thoracic cavity. In the present series these glands were found frequently, and showed a marked preference for certain sites. Most commonly they lay in the connective tissue about the posterior pole of the gland, but they were almost equally numerous at the junction of the

middle and inferior thirds, and at the junction of the upper and middle thirds on the posterior border. It is to be noted that these situations are also those most commonly selected by the parathyroids. Of the latter, 84 per cent. were found in these three places, while 89 per cent. of the accessory thyroids were found similarly located. Rarely accessory thyroids skirt the anterior border of the thyroid between the isthmus and the anterior pole. The case (a girl, aged 8 years) in which two accessory thyroids lay on the tracheal surface of the gland separated from each other by a parathyroid has already been mentioned.

The age incidence of accessory thyroids is well shown in the present series. In exactly 75 per cent. of the infants under one year no accessory thyroid at all was discovered. In children from 1 year to 10 years they were absent in 43 per cent. of the subjects. From 17 years to 60 years (there was none examined between 10 and 17 years) they were absent in 5 per cent. In other words, from infancy onwards there is a progressive increase in the number of accessory thyroids with every successive decade until old age is reached.

The decrease of parathyroids and increase of accessory thyroids is shown in the appended table, the last column of which contains the relative number of parathyroids to accessory thyroids at different ages. It will be seen that in the first few months of life parathyroids are more than seven times as common as accessory thyroids; from the sixth to the tenth years, one and a half times as common, while between the eleventh and twentieth years equality is established. From the last year onwards the preponderance goes to the accessory thyroids, and with every increase up to sixty years becomes more marked.

Age.	Parathyroids per thyroid lobe.	Accessory thyroids per thyroid lobe.	Parathyroid to accessory thyroid.
0— 1	4·0	0·62	7·2
1— 5	3·5	1·0	3·5
6—10	2·2	1·6	1·4
11—20	1·5	2·0	0·75
21—30	0·7	1·7	0·4
31—40	1·1	1·9	0·6
41—50	1·25	2·75	0·45
51—60	1·5	4·5	0·3
61—94	1·25	1·75	0·7

It is not suggested that the above figures are to be taken as expressing the exact incidence in all individuals. Based on no more than fifty-eight cases, they allow a margin of error too considerable for this statistical value, but making all necessary allowance for the limit of the series the numbers will be found to express the broad fact that there is a gradual decrease of parathyroids and increase of accessory thyroids with advancing age.

III. Histology of the Parathyroid Gland.

The histology of the parathyroid glands has already received attention from previous observers. In his original paper, Sandström (5) described it with detail and accuracy as far as he went. After pointing out how varied were the appearances presented by sections of the gland, he proceeded to recognise three main types. In the first the cells were arranged in a continuous mass; in the second the structure was more open, consisting of a reticulum of cells, the meshes of which were occupied by blood-vessels; while the last type showed an arrangement of cells to form small vesicles, in some of which were drops of a substance possessing the staining properties of colloid.

While confirming the Swedish anatomist's work, Welsh (7) carried the subject further. He described four types: (1) The cells form an uniform mass, their protoplasm taking little, if any, stain, and there existing but slight degree of vascularity. (2) The cell-masses show a tendency to break up into anastomosing columns, between which are capillaries borne in a fine connective-tissue stroma; the protoplasm stains somewhat more deeply than before. (3) The cells form branching columns separated by a fine or dense stroma, bearing blood-vessels. These cells are larger and faintly staining. (4) The cells are arranged in a single layer around a central lumen to form definite acini. These cells are large, with protoplasm staining variously, and the lumen is usually occupied by a small globular mass of colloidal substance. Welsh specially notes that commonly several types co-exist in one gland.

More important than this recognition of types is his description of what he terms "oxyphil cells." These he mentions as occurring in a very large proportion of cases, though not in all, and never attaining the same abundance as the ordinary above-

mentioned cells ("principal cells"). They have a relatively large amount of protoplasm, which is usually full of fine oxyphil granules, and he thought he recognised differences between the nuclei of the two varieties of cells, that of the oxyphil being smaller, more nearly circular, and its chromatin more densely arranged. According to their grouping he makes four types of these cells also. They occur as (1) uniform masses forming islets scattered irregularly through the gland; (2) anastomosing columns; (3) cells, either singly or in groups of twos and threes; (4) cells forming definite acini, the lumina of which are occupied by colloid material—a very exceptional type. He does not offer any explanation of these cells, or of their relation to the so-called principal cells.

It will be found that while the following account corroborates the work of both Sandström and Welsh, it brings forward certain hitherto undescribed points in the histology of the glands, more especially respecting the interpretation of the two varieties of cells and the nature of the secretion, and, therefore, of the function of the parathyroids.

Structure of the parathyroid.—The parathyroid is enclosed in a thin connective-tissue capsule, from the deep surface of which delicate trabeculæ pierce the interior of the gland, branching and uniting till the whole structure is cut up into numerous small compartments, polyhedral in section. This framework encloses in its mesh the cellular elements of the organ, and carries a rich vascular and lymphatic supply. In some specimens the connective tissue is increased in places, so that strong septa are seen dividing up the gland. In others the processes are so fine as scarcely to be discernible except under high magnifications.

The blood-vessels, which come from or drain into the adjacent branches of the carotid arteries and internal jugular vein respectively, form a lavish network of capillaries throughout the organ, accepting as they run the support of the trabeculæ. Not infrequently, however, these small vessels venture away from this shelter, and are seen lying among the cells, but for the most part there is no intra-cellular vascular plexus, and in many specimens large masses of cells are found unpenetrated by any blood vessel.

The lymphatic drainage of the gland is likewise free. In its finer ramifications it is traced with difficulty, but the system, as

will be shown below, begins as minute intercellular spaces, which drain into lymphatic capillaries. These, like the blood-capillaries, run in the connective-tissue framework, and as they pass along the trabeculæ gradually advance to the surface, and at the same time unite one with another to form larger channels, until finally they emerge from the gland as one (rarely as more than one) main lymphatic vessel. It is common for this latter to meander for some little distance over the capsule before finally quitting the gland.

The cellular structure of the parathyroid can be appreciated only after an examination of many sections of many glands. Points which are obscure or absent in one specimen show clearly in another, and often a riddle set by some peculiarity of structure in this section finds its ready solution in that. It is supererogatory and confusing to indulge in a classification into types. The parathyroid has but one structure, and its variations are but expressions either of altered connective-tissue contents or of changing activity.

It has already been noted how the framework may vary, and this alone is responsible for many differences. Most often wide divergences of appearance are introduced by the admixture of fat with the gland tissue. This fat may be entirely absent; it may occur as a few isolated fat-spaces; these spaces may be in clusters; or finally whole fields may show fatty tissue, with scarcely any of the proper cellular element. The extent to which this cause alone accounts for differences between specimens is readily understood by comparing slides illustrating the two extremes of fatty infiltration. In the one containing no fat the cells, from end to end of the section, are massed in a solid phalanx; in the other the large amount of fat confers a texture more open than the fattest of bone-marrows. Yet, with all this alteration in non-essentials, the parathyroid cells repeat their peculiarities of structure over and over again, and such variations as they undergo are always dependent on functional activity—usually on alternating rest and fatigue. The parathyroid cells, in the elaboration of their secretion, pass through the transformation to which, as Langley has shown, glandular cells are subject, and in the matter of the histological changes associated with their secretion the parathyroid falls into line with the other glands of the body.

The cells lie in the compartments made by the trabecular meshwork, and these spaces are filled by a varying number of cells arranged without order. According to the sectional outline of each mesh, so will the clump of contained cells be circular, oval or columnar, single or branching. The impression obtained of a section under low power depends on the prominence of this compartition, the fields consisting of an apparently continuous mass of cells when the trabeculæ are slight, of definitely isolated clumps when the septa are coarse. Naturally, so delicate a structure as the parathyroid occasionally suffers in process of preparation, and the soft, protoplasmic cells may shrink. This results in the appearance of a clear space round each cluster of cells between it and the limiting trabecula. The mosaic character thus imparted to the section—each group of cells set in a clear background—is probably wholly factitious, and is not seen in more successful preparations.

Returning now to the cellular elements proper, we find that they approximate to the so-called embryonic type. They are polyhedral in shape, each being modelled by its neighbours and presenting, at or near its centre, a nucleus surrounded by an amount of protoplasm depending on the condition of the cell. The nucleus, which stains readily, though with varying intensity, with basic dyes, shows a marked chromatin skein, in some cells more closely woven than in others. The protoplasm varies extensively with its functional activity. In a cell which has just ceased secreting it is comparatively small in amount, and stains faintly or not at all with acid dyes. Later it grows more eosinophil, and appears of a pale pink, with perhaps a dubiously granular texture. Further rest leads to progressive changes, until the fully-rested cells, ready to secrete again, show a considerable increase in the amount of protoplasm and a marked affinity for eosin, with which stain they colour so vividly as at once to arrest the eye in any field in which they occur. Even under a low power, but more clearly under a high, the protoplasm is seen to be crammed with oxyphil granules. In the last stage the granules are extruded into the surrounding lymph-space, and the cell assumes its fatigued characters again to perform its functional cycle.

It is not all the cells in a gland, nor even all the cells in any field, that show the same stage of activity. It may be that no

sign of activity can be found. Slightly more common is it for the whole field to consist of cells distended with oxyphil granules. Most frequently cells at every stage between rest and fatigue can be readily identified. Unlike such glands as the pancreas or the submaxillary, where the call for active functioning is intermittent and allows reciprocal periods of rest, there is from the ductless glands a constant demand for secretion. These organs must be unceasingly adding their quota to the blood-stream, and we should therefore expect to find cells pregnant with secretion side by side with others exhausted or in process of recovery. A study of but few specimens is needed to corroborate this presumption. The large eosinophilous cell occurs in varied connexions. Grouped with many others, it may form clusters, big or little. It may lie associated with three or four of its fellows. It may stand isolated. Cells of intermediate type can be found, though these, from their less bright hue, require more careful seeking out. With similar irregularity of distribution occur the pale-staining fatigued cells. The appearance, therefore, of a parathyroid gland changes from field to field, and when it is remembered how the stroma and fat vary it will be realised how apparently widely apart are the histological features of different glands. Yet the underlying explanation—that the gland-cells require a rhythm of activity and rest no less than do the cells elsewhere in the body — harmonises their varied features, and enables a clear conception of the parathyroid gland to be formed.

IV. The Secretion of the Parathyroids.

The presence of minute drops of a colloid-like material in the parathyroid has been noted by many, but none have fully interpreted their meaning, while on the secretion, as a whole, the literature is silent. Concerning the hypothetical action of the gland much has been written, but the accounts have been generally founded on the results of extirpation, and depend on no direct histological or chemical proof. This is a matter for surprise, for the human parathyroid so often contains secretion that one would have expected its recognition to have been made by some of the earlier investigators.

As regards the different macroscopic appearances of active and resting glands, it is not often possible to decide on the

vigour of secretion by naked-eye examination alone. It will sometimes be found that the more darkly coloured glands—those tinted with the brown of a normal thyroid—represent an active state, while the pale pink bodies contain but little secretion. The distinction, however, is not infallible. Microscopically, the examination of one section of any gland sometimes makes it possible to form an idea of the amount of secretion that will be found in subsequent sections. It may be noted, as a general rule, subject, however, to exceptions, that the presence of many large clumps of active cells gives promise of plentiful secretion.

The present series provided examples of every stage in the secreting process from the extrusion of the protoplasmic granules to the draining away of the secretion from the gland.

It has already been shown how the oxyphil cell, distended by its granules, extrudes them into the lymphatic space around. The secretion, as it leaves the cell and for some time afterwards, retains its granularity. The small amount that lies between the cells is not readily identified under low powers, but with a $\frac{1}{12}$th in. objective it is not difficult to discover. This secretion may now find its way into the neighbouring lymphatic capillaries, but frequently the products of adjoining cells aggregate to form minute drops of colloid lying in the midst of the cells. The colloid is often found thus scattered, but there is another position the drop may assume relative to the cells around. It is of common occurrence for the secretion to lie among cells grouped more or less regularly around.

Naturally a drop is more likely to appear in the centre of a cell clump than near its boundary, since the former situation is the nearest point to the greatest number of cells, and will, therefore, present most facilities for the aggregation of the colloid. Thus it comes that a drop of fair size is often seen in the middle of a compartment, having pushed open the cells so that they appear to be grouped in a layer, one or more than one deep around a central lumen. In this way a vesicle, comparable to a thyroid vesicle, comes into being.

In some specimens the colloid will collect to one side of the centre, in which case the lumen lies eccentrically and will be bounded by more cells on one side than on the other, but by far the commonest result, at any rate in compartments containing small masses of cells, is for the colloid to occupy a central space,

bounded on all sides by a single layer of cells, beyond which comes the limiting trabecula. With a sufficiently large series of specimens there is no difficulty whatever in recognising every variety of structure, from the continuous mass of cells to the fully formed vesicle lined by cells as regularly as any thyroid vesicle. Such cells, subjected to mutual lateral pressure, soon lose their polyhedral outline and become regular cubical epithelium. In the smallest of vesicles, where each cell occupies no inconsiderable segment of a circle, its shape is correspondingly modified, being broader at its base and tapering towards the lumen.

At the stage we have now reached the granules of the colloid have frequently merged their individuality and an homogeneous mass results. A $\frac{1}{12}$th in. objective, however, will often reveal granularity where a $\frac{1}{6}$th in. fails.

Whether the secretion lies as scattered granules among the cells, or as a drop in a vesicle, it passes into the lymphatics of the gland and trends to the surface, the smaller lymphatic vessels uniting to form larger. Finally, it can be found, as already mentioned, lying on or in the capsule contained in a large lymphatic, lined by the usual pavement endothelium. Along this channel it is led away from the gland.

It is of interest to note that the cortex of the gland sometimes stains more deeply than the medullary tissue, and that drops of colloid and regular vesicles are met with more frequently near the surface than elsewhere. The latter occurrence is probably due to the flow of colloid being towards the cortex. The secretion will be in greater abundance the nearer we approach the surface, and consequently the lymphatic vessels and spaces will be more liable to distension and fuller of secretion than those more deeply situated. Whether the more deeply-staining cortex bespeaks a more vigorous activity is not so certain, though this explanation is probable.[1]

It is desirable to emphasise the fact that neither by its appear-

[1] I have found the thyroid in not a few animals (two-spotted paradoxure, Beatrix antelope, suricate, fat-tailed desert mouse, etc.) to be as much or more parathyroid than thyroid in structure, and in these instances I have often found that thyroid characters predominate at the surface, gradually giving place to a parathyroid structure deeper down. Further, in a young four-horned antelope I found a parathyroid in which the whole of the cortex had already become definitely thyroidal and the change was clearly spreading more deeply.

ance nor by its micro-chemical properties is it possible to distinguish parathyroid colloid from thyroid colloid; the two appear identical. Both may be granular, both may be homogeneous. In a thyroid vesicle the central part of the colloid is often homogeneous, while the more recently elaborated secretion near the lining cells is granular. It has already been shown that the parathyroid colloid in its earlier stages is granular but later loses this quality.

Both thyroid colloid and parathyroid colloid behave similarly to stains. Though both are usually oxyphil, thyroid colloid will occasionally stain as readily with basic as with acid stains—treated with hæmatoxylin and eosin a deep purple results. Parathyroid colloid is sometimes found to possess this peculiarity.

In the paraffin process thyroid colloid is apt to become hard and to tear before the razor into characteristic strips, the edges of which tend to crinkle. The larger collections of parathyroid colloid behave identically.

There remains to notice a difference between the parathyroid as described above and the gland at, or shortly after, birth.

Sections of the glands at this age present an immature appearance in contrast to that attained at a slightly later period. The parathyroid in an infant shows a connective-tissue stroma similar in arrangement to that of an adult, but the trabeculæ, although delicate, are less marked by the cells and therefore more distinct. These latter wholly fill the compartments and present a uniform aspect of inactivity, the protoplasm being comparatively large in amount but staining scarcely at all with acid dyes. As a result the cell-walls are particularly well marked. Cells in an active stage are wholly or almost wholly absent, and no deposit of fat within the gland can be seen.

Such are the characteristics of the infantile parathyroid, but they may persist till as late as the third or fourth year, and in one girl of seven all the parathyroids were infantile. In these later examples, however, it is usual to see signs of awakening activity as marked by a greater affinity of the protoplasm of certain cells for eosin. On the other hand, active parathyroids were found in a baby of three months. In this specimen the

sections had none of the above specified peculiarities except an unwonted prominence of the connective tissue, and it showed the cells broken up into clumps and columns as in the adult. Once in an infant of six days the presence of many moderately active cells was noted, while in a baby of seven months and in another of eleven months a drop of colloid was found, but this is exceptional.

Note.—The above investigations were undertaken on the supposition, now abandoned, that the parathyroids were glands *sui generis*, not possessing the same function as the thyroid, and being essential, in a high degree, to life. With that idea, frequent examination was made of the pituitary gland in man and in many animals, to observe what connection existed between it and the parathyroid.

The result of these investigations was to show that the histology of the pituitary gland is in so many points similar to that of the parathyroid, that the latter serves to explain many features in the former. This is particularly the case in the matter of the clear and granule cells, which have been described in the pituitary. It appears that these two varieties stand in the same relation to each other as do the so-called oxyphil and principal cells in the parathyroid—that is to say, they represent the same cell at the two extremes of fatigue and rest. Intermediate forms can be found without difficulty, and here and there between the cells lie small amounts of granular secretion. At rarer intervals drops of colloid occur, and around them the cells are often regularly arranged to form vesicles.

V. Conclusions.

(1) The parathyroid glands in man are not limited to two on each side of the neck. Though this is the most frequent number, three or four may be found on one side, and, in infants, five or six. In one infant a total of eleven parathyroids was discovered. On the other hand, less than two may occur, and it is probable that they may be absent altogether.

(2) Their position is as inconstant as their number: 84 per cent. lay in the neighbourhood of the junctions of the upper and middle thirds, of the middle and lower thirds of the posterior border of the thyroid lobe, and around its posterior pole. Of

the remainder, some were found buried deeply in the thyroid, especially in its posterior portion. Less frequently they occurred around the anterior pole of the main gland or on its median surface, hidden between it and the trachea. A parathyroid was found as far away as behind the manubrium sterni.

(3) It is not possible to recognise all parathyroids by the naked eye. Typical examples are sufficiently characteristic, but the gland presents gradations of colour, assuming now the yellow of a nodule of fat, now the pinkish-white of a lymphatic gland or thymic residue, now the brown of an accessory thyroid. It may even be black in tint.

(4) Parathyroids are not infrequently associated with accessory thyroids, thymic residues, or lymphatic glands. Under these conditions they present no feature to attract attention, and can be recognised only on microscopical section.

(5) Parathyroids vary in size between wide limits, and the total volume of the tissue in different individuals is inconstant.

(6) The parathyroids occur to greatest number in infancy and progressively diminish with increasing age. They were always present in subjects under twenty years of age.

(7) Accessory thyroids bear a notable relation to parathyroids: 89 per cent. of the accessory thyroids found occupied the same three situations as 84 per cent. of the parathyroids found. In only one case was any accessory thyroid found between the thyroid gland and the trachea, and on that occasion two accessory thyroids were revealed and were separated by a parathyroid —one of the only two cases in which a parathyroid filled this position.

(8) Accessory thyroids are usually absent in infants under one year, but thereafter are found more frequently with lapse of years.

(9) The parathyroid gland, like other glands, presents the histological variations of activity and rest, the so-called oxyphil cells being cells distended with granular secretion, and the so-called principal cells the exhausted stage. Intermediate forms are common.

(10) The secretion of the cells is extruded into the circumjacent lymphatic space, and often the product of many cells runs together to form a drop, around which the cells appear to be grouped. Thence the secretion passes into the smaller lymphatic

vessels running in the trabeculæ, and gradually flows along larger vessels to reach the surface. On, or in, the capsule a main lymphatic channel can often be found draining the secretion away from the gland.

(11) The secretion of the parathyroid, both in its physical characters and in its micro-chemical reactions, is indistinguishable from the colloid of the thyroid.

(12) During the first few months of life the parathyroids show few, if any, signs of activity. By the end of the seventh month colloid secretion may be seen.

(13) In the pituitary gland the occurrence of two kinds of cells is to be explained on the same basis as in the case of the parathyroid, the large granular cells being filled with secretion, the paler cells being fatigued.

REFERENCES.

1. *Berry, James.*—'Diseases of the Thyroid Gland,' 1901, p. 13.
2. *Kohn.*—'Archiv für Mikr. Anat.,' Bd. xliv, 1895.
3. *MacCallum.*—'Brit. Med. Journ.,' November 10th, 1906, p. 1282.
4. *Müller.*—'Beiträge zur Path. Anat.,' Bd. xix, 1896.
5. *Sandström.*—'Läkareförenings Förhandlingar,' Upsala, 1880. (Abstract in Schmidt's 'Jahrbüch,' 1880.)
6. *Shattock.*—'Path. Soc. Trans.,' vol. xlix, 1898, "Report on a Case of Acromegaly."
7. *Welsh.*—'Journ. Anat. and Physiol.,' 1898.

[The expenses of this investigation were defrayed in part by a grant from the Royal Society to Dr. Pembrey, Lecturer on Physiology at Guy's Hospital, in part by a grant to the author from the British Medical Association.]

15. *A case of sulph-hæmoglobinæmia with cyanosis.*

By A. E. RUSSELL.

The patient is an unmarried woman, aged 31 years. She is one of a family of sixteen children, ten of whom died in infancy or early childhood. Of these ten, five died in one week of measles and whooping cough, one died of smallpox, one of

and she was admitted into the West London Hospital under my care in June, 1906. She was operated on by my colleague, Mr. Aslett Baldwin. The medullary cavity of the shaft of the right tibia was found to be obliterated. The shaft was greatly thickened, and the whole bone extremely hard and dense. Its appearance suggested a congenital syphilitic origin. A channel was chiselled out throughout the whole length of the shaft, and the patient thereafter experienced almost complete relief from the pain. The pain had been so severe that she expressed herself quite willing to have the limb amputated. The left tibia was also thickened and showed the scar of an old incision.

She presented a most singular appearance; her lips were extremely cyanosed, and a bluish tint pervaded her cheeks. The colour, however, was not quite that of ordinary cyanosis, but presented a rather leaden tint. The rest of her face was markedly pale, but despite the apparent anæmia the red cell count showed 4,990,000 cells per c.mm.; leucocytes 5310, hæmoglobin just over 100 per cent. The urine contained no albumen, no sugar, and gave no indican reaction with the hydrochloric acid and chloride of lime test. Save for an occasional rise to 99° F., the temperature was normal. Her bowels were constipated and required purgatives, but the stools presented nothing abnormal to the naked eye. She suffered greatly from headache, looked very ill, and was very weak.

On reading the paper entitled "Microbic Cyanosis," by Dr. G. A. Gibson and Dr. C. C. Douglas,[1] I examined her blood with the spectroscope and observed the band of what I took to be methæmoglobin.

She remained in hospital for four months, and when discharged was very much improved as regards the condition of the leg, and with slight improvement in the cyanosis. No attack of dyspnœa occurred. The chief points in the treatment, other than the operation on the leg, were the administration of iron and purgatives.

She was again admitted into the West London Hospital in December, 1906, on account of renewed trouble in the right leg, which was again operated on. Several attacks of dyspnœa occurred similar to those above described, but in one there was an accompanying attack of laryngitis and bronchitis. During

[1] 'Lancet,' July 14th, 1906.

the attacks she again complained of epigastric and thoracic pain, and the cyanosis deepened. The severest attack was markedly relieved by venesection, ten ounces of blood being withdrawn. Examination of the heart was negative, with the exception that examination with the fluorescent screen showed perhaps a little enlargement of the right side of the heart.

On re-examination of the blood in the light of the paper by Dr. S. West and Dr. T. Wood Clarke[1] I found that the spectrum conformed to that of sulph-hæmoglobin. A somewhat concentrated solution of the blood had to be used so that it was very difficult to see the bands of oxy-hæmoglobin at the same time. The band did not disappear on the addition of ammonium sulphide.

Examination of the blood.—Red cells 4,710,000, leucocytes 7000 per c.mm., hæmoglobin 90 per cent.

Urine.—No albumen, no sugar, negative indican reaction.

The degree of cyanosis was about the same as on her previous admission, but with free purgation the cyanosis almost disappeared, and the patient improved very considerably; her headache disappeared, and she regained strength.

Remarks.

The above condition is undoubtedly one of great rarity, this case making only the sixth on record. It is possible, however, that examination of the blood by means of the spectroscope in cases of obscure cyanosis may show that the disease is more common than is suspected. For instance, some of the cases of cyanosis without murmurs attributed to congenital heart disease may belong to this category. In this particular case congenital heart disease had been supposed to be present. There are numerous points of interest in the case:

(1) *Prolonged anæmia.*—This was very severe and of chlorotic type, regularly improving under hospital treatment.

(2) *Bone disease.*—Ethmoidal bone disease in 1892 and periostitis of tibiæ from 1899 onwards. The appearance of the bone suggested congenital syphilis and the mother had had two miscarriages. The patient's facial appearance in no way confirmed

[1] 'Lancet,' February 2nd, 1907. This paper contains an abstract of the literature.

this, and repeated anti-syphilitic measures produced no improvement. It is impossible to say whether the bone disease had any causal relation to the blood condition; the periostitis of the tibiæ became apparent shortly after the onset of the cyanosis, and has been a constant source of trouble ever since. Surgical treatment did not cause the cyanosis to disappear, though it did diminish to a certain extent, but the patient was also under the beneficial conditions of hospital life. It is noticeable that in von der Bergh's case cure resulted after operation on a rectal stricture with urethro-rectal fistula.

(3) *Recurrent bruising and ecchymosis* of the right arm in 1903; when the arm was incised only serum was evacuated.

(4) *Habitual constipation.*

(5) *Cyanosis and sulph-hæmoglobinæmia.*—It is reasonable to suppose that the cyanosis depends upon the presence of sulph-hæmoglobin. It appears from Wood Clarke's researches that a very small amount of sulphuretted hydrogen is capable of giving rise to the compound responsible for the absorption band described, but whether this small quantity binds a considerable proportion of the hæmoglobin and renders it inefficient as a carrier of oxygen cannot be said. If this be so the cyanosis would be explicable. The high blood count and high hæmoglobin percentage suggest a compensatory increase of the red cells and of hæmoglobin.

It is noticeable that in four out of the five cases quoted from the literature by West and Wood Clarke constipation was marked, and that the cyanosis cleared up when the bowels were kept well open. The same applied to their own case. In the present case constipation was also a marked feature and the cyanosis also improved to a remarkable degree when the bowels acted more freely.

It would seem probable, therefore, that the origin of the disease is to be sought in the intestinal tract, but inasmuch as sulphuretted hydrogen is normally present in that canal, and inasmuch as there is no evidence of increased intestinal putrefaction in these cases, it is at present unwise to speculate as to the exact fault underlying the condition. It is possible that careful examination of the urine may reveal evidence of an abnormal sulphur transformation. Dr. J. B. Leathes is at present examining the urine in this connection.

(6) *Paroxysmal attacks of dyspnœa.*—These were of a most remarkable character. In the absence of the cyanosis they would certainly be regarded as functional; indeed, they were considered to be of that nature, and it is difficult to conceive of any other explanation. If the attacks represented efforts at better aeration of the blood they were singularly unsuccessful, as at the termination of each attack the cyanosis was extreme.

March 5th, 1907.

---

16. *A specimen of calcareous change in the myocardium.*

By W. O. Meek.

The specimen shown is an example of a very rare lesion in the myocardium, diffuse areas of calcification occurring in the midst of apparently healthy cardiac muscle.

Clinical account.—The case in which this condition was present was that of a married woman, aged 34 years, who was admitted to St. Thomas's Hospital under Dr. Turney, on November 29th, 1906.

History.—The family history was unimportant. There was a two years' history of debility with loss of flesh and dry cough, and two months' history of swelling of the abdomen and legs.

Physical state.—On examination the patient was found to be a thin, anæmic subject. Both lungs showed extensive signs of chronic pulmonary tuberculosis. The abdomen was enlarged and contained free fluid. The legs were slightly œdematous. The area of cardiac dulness was increased a little to the left. Cardiac pulsation was regular and forcible. No signs of valvular disease were found. The second sound at the pulmonary area was much accentuated. The pulse was of poor volume and tension, its rate 112 per minute. The urine contained a large amount of albumen.

Progress of case.—During her stay in hospital she grew progressively weaker. There was slight irregular pyrexia, and the pulse remained rapid and feeble. Dyspnœa was a marked symptom. She died on December 19th.

Report of post-mortem examination.—A *post-mortem* examination was made by Dr. Box on December 20th. The following account is abstracted from his report.

External appearances.—The body was thin. The shins pitted slightly on pressure.

Lungs and pleuræ.—The right pleura contained 21 oz. of serum, and was not inflamed. The left pleural sac was almost obliterated by dense adhesions. The lungs were the seat of chronic tuberculosis, consisting in the upper lobes of fibrosis and peribronchial thickening, with a few caseous areas. The lower lobes were almost solid, with a recent broncho-pneumonia. A wedge-shaped infarct was found at the extreme right base.

Heart and vessels.—The pericardium was healthy; its cavity contained a little serum. The heart was much enlarged, weighing 15¼ oz. There was decided hypertrophy of both ventricles, especially the right, without much dilatation. All the valves were competent and healthy. The myocardium was rather soft, and deep in the muscular walls of the left ventricle were several irregular-shaped, yellowish patches. These were not larger than small shot, but their outlines were prolonged into narrow striæ. The coronary arteries were quite pervious. The medium-sized arteries throughout the body were a little thickened. No atheroma was found.

Abdomen.—The peritoneum was not inflamed, and contained 112 oz. of serum. The liver showed slight perihepatitis. There was no obvious cirrhosis. The organ was fatty, and the hepatic arteries a little thickened. The kidneys were large, weighing 11½ oz. The pyramids appeared congested, while the cortices were dull, yellow, and slightly atrophic. The capsules were non-adherent. The left Fallopian tube was converted in its distal half into a blood cyst, the size of a walnut. The contents were watery and blood-stained. The remaining organs of the body appeared healthy.

Histological examination.—A portion of the myocardium containing one of the yellowish patches and a piece of lung tissue were reserved for examination. Sections were cut in paraffin and stained with hæmalum and eosin, and with hæmalum and van Gieson's stain.

Microscopical appearances. — Sections of the myocardium showed diffuse areas of calcification varying much in intensity.

In some places the muscle fibres had been replaced by a structureless homogeneous substance, in others the muscle fibres were more or less filled with fine granules, staining a deep, purple colour with hæmalum. In the immediate vicinity of the larger calcified areas there was a slight increase of fibrous tissue, and one or two of the vessels in these areas showed slight thickening of their walls. These changes were quite localised. No giant cells were seen. The surrounding heart muscle stained

FIG. 27.

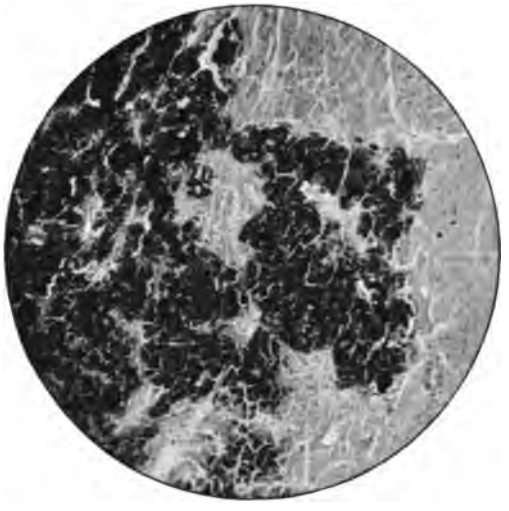

A microscopic section showing areas of calcified muscle fibres, in which the calcareous material has been deeply stained with hæmalum.

well, and under the higher powers its finer structure appeared normal. The blood-vessels showed no changes.

The section of lung tissue showed a condition of red infarction; here, again, the blood-vessels were unaltered.

Unstained sections of the heart were irrigated with strong acids under $\frac{1}{12}$th in. objective. The calcareous matter was seen to partially disappear without the evolution of gas-bubbles. Other unstained sections were soaked in a 10 per cent. solution of acetic acid for twenty-four, forty-eight, and seventy-two hours. They were subsequently washed and stained with hæmalum and eosin.

On examination it was found that the calcareous material had

partially disappeared, and little difference was seen between the sections soaked for the various lengths of time.

The extent to which the acid had affected the calcified muscle fibres varied very markedly. In places entire fibres were seen to have disappeared, in others the acid had had, apparently, little or no effect, while scattered through the changed areas were healthy-looking muscle fibres, from which the calcareous material had quite gone, or was reduced to a few fine granules.

Etiology.—There is considerable difficulty in satisfactorily accounting for the change in the present instance. Calcification of the cardiac muscle is usually ascribed to primary changes in the coronary arteries or their branches. Here, beyond slight general arterial thickening, no gross changes were found; and in the sections examined the vessel walls appear healthy, except for slight thickening in the immediate vicinity of the larger calcareous areas.

In the scattered nature of the change, its granular character, and in the restitution of some of the muscle fibres after treatment with acids, the condition bears a close resemblance to fatty change, where, after dissolving out the fat-droplets with ether, the affected cell may be restored to normal contour and appearance.

Oskar Klotz, writing in the 'American Journal of Experimental Medicine,' 1905, on "Calcareous Degeneration," and also on "Experimental Arterio-sclerosis in Animals," states that calcareous degeneration of a blood-vessel is a sequel of fatty change in the muscle fibres, and traces the process from fat through the formation of a fatty acid to a soap, combination of the soap with calcium, and finally replacement of the fatty acid radicle by an organic acid.

Of the chemical composition of the deposit in the present case it is impossible to say more than that the substance is apparently not a carbonate. Various other salts of calcium and magnesium have been found in calcareous deposits. Von Kossa has stated that the lime salts in these conditions are probably deposited, in part, at least, as an albuminate, which might account for the insolubility of a portion of the substance in the present case.

It is to be regretted that sufficient material has not been retained to permit of chemical analysis.

Literature.—Of similar cases in the literature, I have been able to find only two with a reference to a third.

Professor Coats, in his "Manual of Pathology," mentions a case with scattered areas of calcification in the cardiac muscle. Here the foreign matter was soluble in acids with evolution of gas, and the muscle fibres were restored as to outline, but their cross striation was lost. This change occurred in a case of pyæmia, and was thought to be due to arterial obstruction with necrosis of muscle fibres, and subsequent impregnation with calcium carbonate.

In Professor Coats' second case a portion of the left ventricle was found pale in colour, suggesting fatty degeneration. The muscle fibres were clouded with fine granules, which were soluble in acid without gas formation. The etiology of this case was obscure. Köster, mentioned by Professor Coats, met with a similar case to this, in which he believed the salt to be calcium sulphate.

In conclusion, I must thank Dr. Turney for permission to make use of the clinical report of the case.

May 7th, 1907.

---

17. *The activity of the supra-renal glands in relation to blood-pressures.*

By P. R. Parkinson.

Introduction.—The supra-renal gland is described as being composed of two parts, the cortex and medulla, which are quite distinct from one another developmentally and histologically. Concerning the functions of these two parts but little was known until recently, when much attention has been directed to the medulla from which the active principle of the gland—adrenalin—was extracted. To the cortex no function can be ascribed at present, though certain theories have been held and will be discussed later.

The discovery of adrenalin in the medulla of this gland has led to many experiments being performed on animals, with the object of ascertaining the result of removing this powerful

extract from the circulation, and it has been found that the animals died soon after the operation, death being preceded by a low blood-pressure. It has also been found that in some diseases accompanied by low blood-pressure, there was an absence of adrenalin from the gland; from these experiments it was believed that the low blood-pressure was a result of this absence of adrenalin.

Recent researches on the supra-renal gland of healthy animals have shown that, if the gland be stained with chromic acid, the medulla takes on a yellow stain, due to chromaffin substance, the intensity of which corresponds with the amount of adrenalin that can be extracted from the gland; it was also found that the yellow stain varied in intensity with the states of functional activity of the gland.

In some cases of great exhaustion of the animals the yellow stain could not be obtained; in these cases it seems probable that the adrenalin has been used up in the effort to maintain the blood-pressure at a healthy standard.

The work in this paper was carried out with the object of ascertaining: (1) If the above condition in animals occurred also in man; (2) if the amount of adrenalin present in the gland changed in conditions of high blood-pressures; it seemed possible that, as in low blood-pressures the adrenalin is diminished, in high blood-pressure cases the gland would be stored with adrenalin.

History.—Henle and Stilling (2) first pointed out the presence of the chromaffin substance in the medulla. Kohn (3) discovered the substance also in the sympathetic ganglia of the abdominal plexus; its presence here is of considerable interest and importance in view of the fact that in certain cases where the supra-renal glands are destroyed by growths there may be no occurrence of Addison's disease; the presence of the chromaffin in the ganglia seems to indicate that these ganglia may be able to supply the body with the secretion, the lack of which causes Addison's disease. The presence of supra-renal rests, in some cases, may also account for the absence of this disease under those conditions.

Oliver and Schäfer (4) found that in cases of Addison's disease the glands did not possess the active principle.

The latest work on the supra-renal gland and its changes in

disease has been done by Elliott and Tuckett (1), who found that in guinea-pigs the loss of the yellow stain only occurs in grave exhaustion of the gland; if one gland is removed and the guinea-pig dies in twenty-four hours the stain is still present, but if the exhausted animal survives for three to four days the stain is completely absent. In guinea-pigs poisoned by diphtheria the stain disappears after an illness of thirty-six hours; it appears, then, that acute exhaustion for twenty-four hours causes a moderate but not a great demand for the adrenalin, while in very severe exhaustion the adrenalin is all called upon in thirty-six hours.

In man the study of the chromaffin stain is not quite so satisfactory, as the higher the animal in the scale of vertebrates the less is its stock of chromaffin.

Method.—The method employed for the work in this paper was as follows:

The gland was removed from the body within twenty-four hours after death, and placed in Kohn's mixture for twenty-four hours; this mixture consists of 90 parts of a 3·5 per cent. solution of potassium bichromate, and 10 parts of a 40 per cent. solution of formalin. Portions of the gland were then taken, washed for a few hours in water to free them from formalin, frozen in gum, and sections cut about 28 μ in thickness; the sections were stained in either Sharlach Red or Sudan III, to show the amount of fat present, and mounted in glycerine.

The sections showed the fat of the cortex stained red, and in the medulla the yellow chromaffin substance if present.

As it is unfortunately impossible to obtain human supra-renals immediately after death, it was obviously necessary to ascertain if *post-mortem* changes occur in the various parts of the gland under observation, and to what extent, if any; the experiments for this purpose were carried out in animals, cat, rabbit, and guinea-pig being used.

Two animals of each kind were taken; a healthy one was killed, and a supra-renal gland removed at once to the preserving fluid; the animal was then placed in the *post-mortem* room until twenty-four hours had elapsed, when the other supra-renal was removed, treated in the same manner, and the sections of these two glands compared; from the other animal, which died from some exhausting disease, the supra-renals were removed as

above, one immediately after death and the other after twenty-four hours. In no case could any *post-mortem* change be detected, and with the exception of increased congestion sometimes present in the gland removed twenty-four hours after death, the essential constituents of the gland remained unaltered.

A few glands were obtained from human bodies which had been placed in a freezing chamber one hour after death; these had the same relation to disease as the supra-renals from unfrozen bodies, and are included in the list given below.

It is probable, then, that no marked *post-mortem* change takes place in human glands within twenty-four hours after death, and all the glands examined in this work were removed within that time.

Fifty supra-renal glands were taken, and in examining the sections three substances were observed:

(1) Fatty substance of the cortex.

(2) Pigmented brown granules of the cortex.

(3) The chromaffin substance of the medulla.

Though the last is of primary importance, the others are subject to great variation in disease and will be considered first.

Fatty substance of cortex.—The supra-renal cortex contained some globules of fat in all cases examined, though it varies considerably in amount.

It is stated (6) that the supra-renals of normal children contain little or no fat, but in toxic conditions and marasmus fatty degeneration occurs in the cortex. In half the cases I examined in children who had died from exhausting diseases this statement was upheld, but in the other half of the cases very little fat was present.

These latter cases form a contrast to the guinea-pig, in whose gland the fat spreads throughout the cortex in conditions of exhaustion, taking the place of the granules; there is no relation between the spread of the fat and the disappearance of the brown granules in man.

In a case of pernicious anæmia in man the amount of fat present was diminished in quantity—a rather unexpected condition in view of the increase in other organs; this may point to the fact that the cortex, whatever its function may be, displays its full working capacity in this disease.

Where much chromaffin was present in the medulla it was found that in the majority of cases the cortex contains a diminished quantity of fat. In cases of activity of the medulla, when a severe drain has been put upon it in toxæmic cases, the quantity of fat varied, sometimes being increased, sometimes diminished in quantity; from these results it follows that the activity of the cortex and medulla bear no relation to each other.

Much attention has lately been directed to the cortex, and some observers have attempted to prove that it has a very important function in renal diseases and toxic conditions.

Aubertin and Ambert (7) have found changes in the cortex in cases of renal disease associated with high blood-pressure; they examined eight cases; three showed adenomata of the cortex, and in five cases the gland was larger and heavier than normal; they state that the cortex is increased and the medulla somewhat atrophied, from which they infer that there is a relation between the high blood-pressure and the increase of the cortex, and assume that the cortex produces an antagonistic body as a protection against the effects produced by the toxic products of renal disease.

In no case of renal disease and high blood-pressure which I examined was any adenoma present, nor was there any increase in the relative size of the cortex; adenomata in other glands are functionless and their occurrence in them is not a sign of increased activity of the glands, so there is no reason for assuming that they are so in the supra-renal gland; moreover, if this view of the action of the cortex were correct we should expect to find that in cases of high blood-pressure, the cortical activity being increased, there would be a consequent diminution in the quantity of fat in the cortex, but in all the cases of renal disease with high blood-pressure that I examined there was an actual increase in the amount of fat.

The fact that in the guinea-pig the fat disappears if half of one gland is removed, owing to the extra demand upon the remaining tissue, shows that cortical activity is followed by a diminution in the amount of fat.

Cybulski (8) also states that the cortex removes toxins from the blood, and he says that death following the removal of the glands is due to auto-intoxication.

Against this theory is the fact that when one gland is removed from an animal and the other gland is examined some time after it is found to have hypertrophied, but the hypertrophy is of the medulla and not of the cortex (1).

Elliot and Tuckett made observations on the subcutaneous grafts of the supra-renal gland in guinea-pigs, and found that they produced œdema, hæmorrhagic solution, and death; this might seem to be due to the toxin present in the cortex of the grafted gland, but their further experiments showed that the irritant substance occurs chiefly in the medulla; moreover, this irritant is absent from the supra-renal of carnivora.

Thus there are many objections to the view that the supra-renal cortex produces an antitoxic substance in cases of renal disease or high blood-pressure.

Brown granules.—These occurred at the inner margin of the cortex and varied considerably in amount in different cases, sometimes being absent. They were never so well marked in the human as in the guinea-pig's gland; this animal is the only one of the lower animals possessing these granules, and as they do not occur in all animals it is probable that their function is not an important one.

In the guinea-pig they disappear in exhaustion of the gland—*e.g.* in diphtheria.

It was formerly believed (9) that these granules in the human supra-renal gland occurred in cells which were in the transition stage between cortex and medulla. They occur in the cells of the zona reticularis, are insoluble in alcohol, and rarely are dense enough to obscure the nuclei of the cells. The cells contained more pigment in adults than in children (10).

Examination of the granules in the human supra-renal gland is unsatisfactory; they are seen, when present, at the junction of the medulla and cortex, where also the blood-vessels are most marked, and this adds to the difficulty, as they are not easy to distinguish from the congested vessels. They bear no relation to the blood-pressure, but seem to be rather more often present in cases of high blood-pressure and arterial diseases than in cases of exhausting disease.

In children who have suffered from exhausting disease they

sometimes occur in fair quantity, however, and with the congested vessels fill up the greater part of the centre of the gland, very little medulla being present. In no cases were the brown granules seen in the medulla.

It is possible that these granules, from their proximity to the congested vessels and from their colour, may be derived from, or be dependent upon, the blood-vessels.

Medulla.—In children there is usually a relatively small medulla, which in exhausting diseases is congested, though this congestion, from observations given above, is probably a *post-mortem* change. In many cases where there has been a continuous high-blood-pressure the medulla is relatively large; in no condition where chromaffin was present was it relatively smaller some observers have stated (7) that in conditions of high blood-pressure the medulla atrophies.

The medulla is never increased in exhausting diseases, and in some cases is relatively smaller.

Chromaffin substance of the medulla.—The object of this work was chiefly to observe the change in the amount of the yellow staining substance present in the medulla under varying conditions of blood-pressure; this substance has already been examined in the lower animals by Elliott and Tuckett, and their results stated above: they were able to study conditions of low blood-pressure only, as diseases accompanied by high blood-pressure and arterial diseases cannot be studied in the lower animals, but in man these conditions are of the utmost importance and interest, being of very common occurrence.

Unfortunately, in man the adrenalin present is less stable than in lower animals, and a slighter shock to the more susceptible nervous system rapidly drains it away.

Over fifty cases were examined, and those cases in which chromaffin was absent are placed in one list, those in which it was present in another list. In all cases there is also a record of the relative amounts of the cortical fat and the medulla. The amounts are all relative, as there is no fixed quantity by which they may be compared, since even in cases of apparently sudden death in healthy persons the quantity varies.

It has been mentioned that in the lower animals the exhausting diseases are associated with loss of the adrenalin from the gland;

the same result would be expected to occur in the human gland under like conditions, and such is the case, the only difference being that the human gland gives up its adrenalin in less time than that of the lower animal; diphtheria, one of the most exhausting of diseases, causes the loss of the yellow stain in thirty-six hours in guinea-pigs, whilst in man an acute exhausting condition like hydrochloric acid poisoning causes its loss in less than twelve hours.

In less acute conditions it might be expected that the cells of the medulla would be able to supply sufficient adrenalin without it completely draining away, and that in chronic cases the activity of these cells would so far increase as to be able to more than meet the extra demand put upon them, and the gland in these cases would still show the presence of adrenalin; several glands from cases of this description were examined—*e.g.* in chronic tuberculosis, and adrenalin was present in the gland.

TABLE I.

Diseases accompanied by low blood-pressures.

Disease and cause of death.	Chromaffin.	Fat in cortex.	Relative amount of medulla.
1. Acute peritonitis: gastric ulcer	Absent	Moderate	Moderate.
2. Lobar pneumonia	"	Increased	Diminished.
3. Infective endocarditis	"	Diminished	"
4. Cystitis: pneumonia	"	"	"
5. Suppurative peritonitis	"	Increased	Moderate.
6. Appendicitis: peritonitis	"	Moderate	"
7. Acute phthisis	"	Increased	"
8. Tuberculous pneumonia	"	Diminished	Diminished.
9. Fractured skull	"	Moderate	Moderate.
10. Emphysema	"	"	"
11. Lobar pneumonia	"	Diminished	"
12. Rheumatism, acute	"	Increased	Diminished.
13. Hydrochloric acid poisoning	"	"	"
14. Cæsarian section: death from shock	"	Moderate	Moderate.
15. Phthisis: hæmoptysis	"	"	"
16. Septicæmia	"	Diminished	Diminished.
17. Broncho-pneumonia	"	Moderate	"
18. Phthisis: tuberculous meningitis	"	Diminished	"
19. Broncho-pneumonia	"	Increased	"
20. Suppurative peritonitis: appendicitis	"	Moderate	"
21. Broncho-pneumonia	"	Increased	Moderate.
22. Hæmorrhagic pancreatitis	"	Diminished	"

Table I.—The cases examined in this table showed that adrenalin was absent from all of them; they are all conditions involving a continuous fall of blood-pressure and a consequent drain upon the adrenalin would be expected; as the fall in pressure continues until death, no storing of the adrenalin would take place, and as the table shows it was entirely absent.

Table II.—In this table a number of cases are given in which a contradictory result was found to that expected from an examination of Table I.

In dealing with these cases it must be remembered that the presence of adrenalin in the gland may depend on two factors:

(1) In the first place, if the disease were a chronic one, the supra-renal gland, owing to its reserve power, might be able to adapt itself to the new conditions and manufacture a sufficient supply of adrenalin to keep pace with the demand, and yet store a little in the cells for further emergency; if in this condition the patient died some adrenalin would be found in the gland; this theory would account for the presence of adrenalin in Cases 2, 4, 7, 8, all of which were chronic conditions not requiring a rapid call upon the adrenalin.

(2) The other factor is that the patient may die before there has elapsed sufficient time for all the adrenalin to be drained away from the gland; in this case death must occur very rapidly, as we know that adrenalin quickly disappears from the human gland.

Case 1 is explained from this theory as the child died within nine hours of the onset of the disease.

In Case 5 the lowering of the blood-pressure, if it occurred at all, would be very slight, and any high pressure would be injurious to the damaged part, so that the retention of adrenalin here would be expected.

To Case 6, of hæmorrhage into a pancreatic cyst, neither of these explanations can be applied, and it is an exception to the general rule.

Case 3 of infective endocarditis is difficult also to explain, but here two opposing forces are at work: on the one hand is the attempt to keep up the blood-pressure by using the adrenalin, and on the other the pressure must be kept as low as possible to rest the heart.

From the results stated above it may be concluded that in

diseases which are accompanied by low blood-pressures the adrenalin disappears from the gland; occasionally in more chronic cases some adrenalin is present, perhaps due to the gland adapting itself to the new conditions.

TABLE II.

Diseases accompanied by low blood-pressure, showing chromaffin.

Disease and cause of death.	Chromaffin.	Fat in cortex.	Relative amount of medulla.
1. Laryngeal diphtheria in a child .	Present	Increased	Moderate.
2. Tuberculous peritonitis . .	"	Diminished	"
3. Infective endocarditis . . .	Trace	Increased	Diminished.
4. Pericarditis: empyema . .	Present	"	"
5. Congenital syphilis: gangrene of foot	"	"	Moderate.
6. Hæmorrhage into pancreatic cyst	Trace	Diminished	Diminished.
7. Chronic phthisis, hæmorrhage, rapid death	"	"	Moderate.
8. Chronic tuberculosis, child . .	Present	Increased	"

In Table III are given all the sections examined in cases of cardio-vascular disease and diseases accompanied by high blood-pressures. It is unfortunately impossible to compare the supra-renals in these conditions with a series of glands in what may be considered a normal condition. In Table IV are three cases of sudden death which may be considered normal, though all of them are open to some doubt; in these three cases adrenalin was present, but the yellow stains were of slightly different intensities, though not so deep as in the majority of cases in Table III.

The excessive stain in Table III is easy to understand as these are conditions in which the blood-pressure must not be increased, since any further rise or any extra obstruction to the emptying of the ventricles would be followed by serious results.

In some cases in this table it is seen that only a trace of chromaffin was present, instead of the deep stain expected; the termination of these cases explains the deficiency; one patient (6) had died of hæmorrhage a few hours after operation, another had an attack of acute endocarditis on an old lesion; in the case of pernicious anæmia the presence of chromaffin was

expected, as any rise of pressure in this disease would prove too great an obstruction for the degenerated heart to overcome, whilst some adrenalin would be used up to prevent any further fall in the already low pressure.

TABLE III.

Cardio-vascular diseases and diseases with high blood-pressure.

Disease and cause of death.	Chromaffin.	Fat in cortex.	Relative amount of medulla.
1. Chronic renal disease, hypertrophied heart	Present	Increased	Increased
2. Aneurysm of aorta	"	"	"
3. Aortic regurgitation . . .	"	Moderate	"
4. Fatty heart: atheroma . .	"	Increased	"
5. " " " . .	"	"	Diminished.
6. Granular kidney: hæmorrhage after operation	Trace	"	Moderate.
7. Mitral stenosis and regurgitation	"	"	"
8. Mitral stenosis	Present	"	"
9. Pernicious anæmia . . .	Trace	Diminished	"
10. Chronic nephritis . . .	Present	Increased	"
11. Granular kidney: mitral stenosis, infective endocarditis . .	Trace	Moderate	"
12. Aortic regurgitation . . .	Present	Increased	"
13. Aortic and mitral disease . .	"	Moderate	Increased.
14. Aortic disease: atheroma, angina pectoris	"	Increased	"

TABLE IV.

Conditions which may be considered normal, i. e., sudden death.

Disease and cause of death.	Chromaffin.	Fat in cortex.	Relative amount of medulla.
1. Morphia poisoning	Present	Moderate	Moderate.
2. Heart failure due to distended stomach	"	"	Increased.
3. Cerebral abscess, suddenly ruptured into meninges . . .	"	"	"

In Table V are given three cases of arterial disease in which no chromaffin was present; it is seen that in all these cases the patient underwent an operation and died in a few hours as a direct result of shock from the operation; to combat this post-

operative shock the adrenalin would be quickly called upon, and its absence therefore is not unexpected.

TABLE V.

Conditions as in Table III, with absence of chromaffin.

Disease and cause of death.	Chromaffin.	Fat in cortex.	Relative amount of medulla.
1. Atheroma: malignant disease, operation	Absent	Increased	Diminished.
2. Atheroma: senile gangrene, operation	"	Diminished	Moderate.
3. Arterio-sclerosis: amputation .	"	Moderate	"

It is seen from the above tables that although there are occasional discrepancies, yet in the great majority of cases the general rule is followed that low blood-pressures use up the adrenalin substance, while in high blood-pressures and cardio-vascular disease this substance is stored up; the storing up is due to the fact that although the cells of the medulla are active and producing adrenalin, little or none of it is required by the vascular system, and therefore it accumulates in the gland.

If, in these cases of cardio-vascular disease, the adrenalin were continually passed into the system, the rise of blood-pressure resulting would aggravate the condition present, and the result would in advanced cases of the disease be fatal; under the extra pressure produced an aueurysm might rupture, an atheromatous patch give way and produce an aneurysm, a heart, diseased but compensated, become dilated and uncompensated, or a dilated, uncompensated heart cease to act. It is quite conceivable that when the gland is stored with adrenalin some of it may escape and any of these results follow. This may be especially liable to occur in a young man who has a diseased aorta, and in whom the maintenance of a high pressure will cause an aneurysm at the part diseased. A young man in that condition is liable to take a considerable amount of exercise, and it is now believed that exercise does not increase the blood-pressure, so that exercise alone would not of necessity cause a weakened artery to give way, but the stimulation of the supra-

renal gland by the rapid flow of arterial blood through it, would lead to an increased formation and an increased elimination of the active substance, from which would follow a dangerous rise of blood-pressure.

It seems possible also that excessive exercise in a man whose arteries, though not diseased, have lost their elasticity, may act injuriously in a similar manner, and through the excessive elimination of adrenalin following the exercise, cause an atheromatous degeneration of the arterial wall.

REFERENCES.

1. *Elliott and Tuckett.*—'Journal of Physiology,' vol. xxxiv, Nos. 4 and 5.
2. *Peule and Stilling.*—Quoted in 'Ergebnisseder Pathologie, 1903.
3. *Kohn.*—Ibid.
4. *Oliver and Schäfer.*—'Journal of Physiology,' vol. xviii, 1896.
5. *Ehrmann.*—'Archiv für Exper. Path. u. Pharmah.,' 1906.
6. 'Encyclop. Med. and Surg.,' 1906.
7. *Aurbertin and Ambert.*—'Tribune Medicale,' 1904, p. 119.
8. *Cybulski.*—Quoted in 'Ergebnisseder Pathologie,' 1903.
9. *Gottshau.*—'Archiv für Anat. Leipsig,' 1883.
10. *Flint.*—'Johns Hopkins Hosp. Reports,' vol ix, p. 213.
11. *Pearce.*—'Journal of Exper. Medicine,' 1906.

May 7th, 1907.

18. *An example of primary carcinoma of the male urethra.*

By S. G. SHATTOCK.

De carcinomatis primarii exemplo urethræ masculinæ.

SUMMARIUM.

AEGER ætatis 54; extremitas urethræ anterior aliquantulum coartata; neque glans nec meatus affectus.

Apparebat nonnunquam hæmorrhagia exigua.

Haud ægrotaverat homo e gonorrhœâ aut e syphile.

Penis extremitas amputata est.

Urethrâ divisâ neoplasma, superficies cujus papillaris erat, apparuit, canale in longitudinem centimetris tribus affectâ.

Sectio microscopica neoplasma probat carcinoma cum cellulis squamosis esse, corpore spongioso invaso.

Kaufmann[1] exempla modo quattuor urethræ masculinæ carcinomatis primarii colligere potuit. In his omnibus pars urethræ affecta bulbosa erat; multa sunt exempla similia abhinc observata.

The rarity of primary carcinoma of the anterior portion of the male urethra may justify the record of the present case, although beyond its rarity it has little interest of a strictly pathological kind.

The patient was a man, aged 54 years, under the care of Mr. P. A. Lloyd, of Haverfordwest, who has kindly allowed me to publish the case, of which he has furnished the following history.

About a year previously the patient had passed some blood with his urine, and had experienced some smarting during micturition; the blood would stain his linen between the acts. These symptoms lasted for a few days and disappeared without treatment. Until May, 1905, he observed nothing except that the urine was passed, he fancied, more forcibly than had usually been the case. He then noticed some discharge on his shirt, and on consulting Dr. Atkinson, of Hampton Hill, he was found to have some narrowing of the urethra. This was treated by the passage of sounds, commencing with No. 6, which was gradually increased to No. 10. The sound was passed at intervals of a week, and some hardness, which was perceptible just behind the glans, was thought to be diminishing.

Early in November, 1905, he saw Mr. C. Stonham, and afterwards Mr. H. T. Butlin, who both advised that the urethra should be slit up, the growth examined, and, if found malignant, that the penis and inguinal glands should be removed.

On November 6th the anterior portion of the penis was removed by Mr. Lloyd, to whom the condition then seemed undoubtedly epitheliomatous.

There was no history either of gonorrhœa or syphilis. The patient had for very many years (certainly for thirty) suffered

[1] 'Verletzungen und Krankheiten der Männlichen Harnröhre und des Penis,' 1886.

from attacks of psoriasis of the nails of the fingers and toes, for which he had taken arsenic in considerable doses. The use of the remedy had led to irritation of the eyes.

Whether the drug induced an initial change in the urethral epithelium after the manner of a cutaneous keratosis, to be succeeded, as happens in certain cases of arsenic keratosis, by carcinoma, is a possibility worth indicating.

I have thus described the specimen (No. 4422A) in the

FIG. 28.

The amputated end of the penis, the urethra being divided to show the papillary carcinoma growing from the mucosa. (Nat. size.)

EXPLICATIO FIGURÆ.

Penis extremitas amputata. Dividitur urethra ut monstretur carcinoma papillare e membranâ mucosâ ortum. (Magnitudinis naturalis.)

Museum Catalogue of the Royal College of Surgeons: "The anterior portion of a penis removed during life for the disease of the urethra shown. For the whole distance, 3 cm. (1¼ inches), though not for the entire circumference of the canal, the mucous membrane is thickened and has a somewhat coarsely papillary surface. The lesion, which, as seen in the section, is of an opaque white colour, and has a vertical 'grain,' ceases abruptly at the meatus, in the vicinity of which there is no macroscopic invasion of the deeper tissues. Towards its posterior end the

growth has commenced to infiltrate the substance of the corpus spongiosum, and here it attains a thickness, in the section, of ·5 cm. or $\frac{3}{16}$ths of an inch. The new formation is nowhere ulcerated or necrosed. The surface of the glans and the preputial mucosa are quite unaffected. A second portion of the corpus spongiosum, 1 cm. in length, was afterwards removed at the operation to clear the disease."

Histology.—The epithelium over the whole of the glans is quite free of any pathological change. For its entire extent it

FIG. 29.

A longitudinal microscopic section of the upper part of the glans penis, showing the extent of the papillary growth from the urethral mucosa and its deep extension into the corpus spongiosum, on the distal, left-hand, extremity. The surface of the glans is unaffected, the lesion ceasing abruptly at the meatus. × 4.

EXPLICATIO FIGURÆ.

Sectio microscopica penis glandis, neoplasma papillare monstrans ex membranâ urethræ mucosâ ortum; in parte sinistrâ invaditur corpus spongiosum. Glandis superficies integra. × 4.

presents a stratum granulosum and underlying prickle-cells as in the proper epidermis, and this up to the very meatus within which the new growth commences.

The growth itself has a well pronounced papillary construction of comparatively simple processes, thickly clad with epithelium of the squamous-celled kind; the squamous cells of the surface

are many-layered, and in places with nuclei only faintly stained or invisible.

In the clefts between the bases of the papillary processes the accumulation of horn-like cells, where not exposed to the urinary stream, is especially marked.

Beneath the epithelium there is a varying amount of small-celled infiltration of the corium, and of the bases of the connective-tissue cores of the papillæ.

For a length of 1·5 cm. there is no deep invasion of the

FIG. 30.

Showing the character of the portion of the growth invading the corpus spongiosum as seen in the preceding figure. (2 in. objective.) The specimen has been reversed in the photograph.

EXPLICATIO FIGURÆ.

Neoplasmatis monstratur pars illa quae corpus spongiosum invadebat.

corium, and although the deep terminations of the interpapillary processes are in places subdivided and narrow, they do not transgress the general, straight, or curvilinear limit, which the epithelium as a whole presents.

More posteriorly a carcinomatous invasion is obvious, irregular columns of epithelium pressing into the tissue of the corium, and far beyond it into the muscular stroma of the corpus spongiosum.

These deep extensions present the horny centres and all the other characters of a keratinising squamous-celled carcinoma, the cells about the horny centres holding flakes and granules of eleidin as in an epidermal growth.

The tissue in the immediate vicinity of the invading epithelium is infiltrated with lymphocytes and plasma cells (Unna).

In the last edition of 'Holmes's System of Surgery' (vol. iii, 1883, p. 225), Sir Henry Thompson concludes his brief notice of tumours of the male urethra with the statement that cancer is always secondary to primary disease elsewhere—a statement founded upon that of Rokitansky,[1] who speaks of carcinoma of the male urethra being met with as an extension, *ex contiguo*, from the penis in epithelial cancer of the glans, or as an extension from disease of the bladder, or as sometimes occurring in the form of independent nodules, varying in size from a hempseed to a pea or bean, in connection with neighbouring carcinoma of the urinary and sexual organs.

In regard to the growths found at the anterior part of the canal, Sir Henry Thompson observes that they appear almost confined to the fossa navicularis, are usually soft, of a red, rose colour, bleed very readily, and are, indeed, an intra-urethral form of wart. This excellent description applies in part to the case with which the present communication deals, for it holds true of the more anterior and chief portion of the growth, which does not exhibit the invasive character of the rest.

That the rarity of primary carcinoma of the male urethra is high will appear from the fact that Kaufmann in his monograph[2] did not succeed in collecting more than four cases in which the diagnosis was microscopically authenticated.

In the female sex the disease is less uncommon. I have myself had the opportunity of examining two such cases; in both complete excision of the urethra was carried out, in one by Mr. W. H. Battle (No. 4425 B, Museum Royal Coll. Surg.: papilliferous columnar-celled carcinoma); and the other by Mrs. Boyd (4425 C, Museum Coll. Surg.: papilliferous columnar-celled carcinoma).

And not a few other examples have been recorded. Indeed, a

[1] 'Lehrbuch der Pathologischen Anatomie,' Wien, edit. 3, 1855–61, p. 380.

[2] 'Verletzungen und Krankheiten der Männlichen Harnröhre und des Penis,' 1886, Deutsche Chirurgie.

second case came under the care of Mrs. Boyd not long after the first, and is fully recounted with it, in the 'Journal of Obstetrics and Gynæcology of the British Empire' (vol. ix, 1906, p. 40). But setting aside carcinoma of the female urethra as not pertaining to the statistics of the present subject, the four cases collected by Kaufmann (*loc cit.*) all concerned the bulbous portion of the canal.

These cases have been so fully transcribed by Marcus Beck in an article published in the 'International Clinics,' second series, vol. ii, 1893, that it would be superfluous to again cite them *in extenso*. In order of publication they stand thus:

1865, Thiersch.[1]—The patient had for many years suffered from difficulty of micturition, followed by incontinence. Catheterisation caused intense pain in the prostatic region. A swelling in the perineum followed, and upon this breaking, pus and urine were discharged from a fistula in the region of the right ischial tuberosity.

On sounding, what was thought to be a prostatic calculus was felt. After perineal section a characteristic friable tissue was encountered, the supposed calculus proving to be the bare lower border of the symphysis encrusted with urinary salts. Examination of the growth proved it to be epithelial carcinoma. Death took place from pyæmia three weeks later.

1881, Schuster.[2]—The patient, aged 72 years, had suffered for fourteen days with anuria, and for five days with swelling of the scrotum and penis. When examined there was found, in addition to the swelling of the genitalia, a tumour in the perineum as large as a goose's egg. This was opened, and a communication with the bulbous part of the urethra discovered. The perineal wound healed, except for a small fistula, through which pus and urine escaped. After death the growth was found to be an epithelial carcinoma.

1883, Guiard.[3]—An officer, aged 52 years, who had suffered from gonorrhœa twenty years previously. For six weeks there had been difficulty in micturition; there was a stricture in the perineal part of the urethra. Internal urethrotomy was per-

[1] 'Der Epithelialkrebs, namentlich der Haut,' Leipzig, 1865, Fall 92, pp. 283, 289.

[2] 'Wien. Medic. Wochenschr.,' 1881, p. 120.

[3] Guiard, 'Annal. des Mal. d'Org. Genito-urin.,' August 7th, 1883.

formed. In course of time a swelling of the scrotum and perineum appeared, and in the latter a tumour as large as a goose's egg. In spite of a wider incision no cessation of the fever occurred.

After four weeks local improvement took place, but a further contraction of the urethra. On dilatation, numerous abscesses formed, which gave rise to perineal fistulæ with hard edges. Later on, a medial incision was carried out, with removal of the granulation tissue. The latter showed on microscopic examination flat and pavement epithelium with large nuclei—epithelioma. At the meatus externus there was a tumour, the size of a pea. In the course of the following week a hard infiltration appeared in the neighbourhood of the root of the penis, scrotum, and perineum. The tumour of the glans ulcerated; enlargement of the inguinal glands and prostate followed; diarrhœa; death. After death there was found a deep carcinomatous induration of the urethra, which penetrated the corpus spongiosum; there were secondary nodules in the lungs.

1884, Trzebicky.[1]—The patient was aged 63 years. Ten years previously he fell on the perineum; since then there was difficulty in micturition. Stricture ensued, and then phlegmonous inflammation of the perineum and scrotum, with the formation of a urinary fistula in the scrotum. When admitted to hospital, the penis was much swollen and œdematous; in the peno-scrotal fold there was a fistula with swollen edges, covered with rose-red, bleeding granulations. The urine contained fairly numerous, flat, epithelial cells. Amputation of the penis was carried out. Four months later recurrence in the inguinal glands was noticed. On examination, the new formation was found to be a carcinoma.

The other cases referred to by Kaufmann, but in which microscopic confirmation is wanting, are those of Thiaudière,[2] Billroth,[3] Poncet,[4] and Albert.[5]

In regard to the last mentioned, however, a microscopic examination appears to have been made later in the history of the case.

[1] 'Wien. Medic. Wochenschr.,' 1884, pp. 606 and 645 (Nr. 20, 21).
[2] Thiaudière, 'Schmidt's Jahrb.,' Bd. vii, p. 83, 1835.
[3] Billroth, 'Chir. Klinik.,' Zurich, 1860–67; Berlin, 1869, p. 344.
[4] Poncet, 'Gaz. Hebdom.,' 1881, 6 Mei, p. 282.
[5] Albert, 'Lehrbuch der Chirurgie,' 3 Aufl., Bd. iv, p. 230.

In the fourth edition of Albert's 'Lehrbuch der Chirurgie,' vol. iv, p. 230, published in 1891—that is, after the appearance of Kaufmann's monograph—I find added in brackets: (Exstirpation Diagnose Vestätigt). Whether the diagnosis rests upon a macroscopic or a microscopic examination is not stated. This case of Albert's again appears in an article by Hottinger,[1] who, in a brief extract, definitely says that a microscopic diagnosis was made. Hottinger does not give a direct reference to the publication from which his information is obtained, but it is apparently from the thesis published by Wassermann in 1895 ('Thèse de Paris,' 1895).

This being so, I have added Albert's case to the series authenticated by microscopic examination, although I have been unable to refer to a copy of the thesis mentioned.

1891, Albert.[2]—The patient, aged 55 years, was suffering from stricture, infiltration of the perineal region, and fistulæ. The suspicious appearance of the tissue led to the diagnosis of carcinoma, which was confirmed microscopically. Resection of the urethra was carried out. Death occurred three days later from general sepsis.

If we take Kaufmann's contribution as a first landmark in connection with the subject it will be found, nevertheless, that three cases are omitted from it, although these antedate its publication, two of them by a considerable interval.

Others have been recorded since; indeed, so many, that the disease has almost lost the interest of rarity which it once possessed.

The three cases overlooked by Kaufmann are as follows: 1861, Hutchinson; 1876, Mears; 1885, Paul.

1861, Jonathan Hutchinson.[3]—The patient, aged 22 years, presented himself with a greatly swollen penis, the prepuce being phymosed from œdema, and there being a dusky, brown-like induration in the under part of the organ, just behind the glans. This induration had already ulcerated in its centre, and the patient alleged that urine escaped through the opening. The prepuce was slit up, but no chancre was found present. The induration below the urethra was then freely incised, and in so

[1] 'Correspondenz-blatt für Schweizen Aerzte,' vol. xxvii, 1897, p. 513.

[2] 'Lehrbuch der Chirurgie,' 4 Aufl., Bd. 4, p. 233.

[3] 'Path. Soc. Trans.,' vol. xiii, p. 167.

doing a considerable thickness of white, curdy material was divided. The swelling had been noticed about three weeks previously; there had been not the slightest difficulty in micturition for more than a month.

After about two months the ulcer under his penis had increased to about the size of a halfpenny, and was covered with warty, fungating granulations. All the urine was passed through this ulcer, the microscopic examination of which showed the usual elements of epithelioma.

Amputation of the penis was carried out, as low as possible; nevertheless the urethra at the point of section was found distended by soft, warty granulations, and the corpus spongiosum was dissected out for another inch in order to get to a healthy part. It having been necessary to remove the urethra so far down into the scrotum, an opening was made into the perineum to provide for freedom of micturition, a catheter being passed through this and retained in the bladder. About three months after the operation a small mass of fungating granulations appeared in the scar close to the urethral orifice; in the course of a week these had increased to the size of a large nut; they were destroyed by repeated applications of chloride of zinc.

The patient was in good health eight months after the operation. On laying open the urethra of the amputated part, it was found occupied throughout by soft, warty growths. "The microscopic structures of epithelial cancer were everywhere abundant and definite." The author remarks that the patient's skin seemed remarkably prone to the production of ordinary warts, of which there were great numbers on the hands, scrotum, and thighs.

1876, Mears.[1]—The record in this case is confined to the simple statement that the tumour was removed from the meatus of a man aged 40 years.

The nature of the growth is reported by a Committee to have been carcinomatous; the papillæ were covered with dense layers of flat epithelium, and contained concentrically laminated pearls.

1885, Paul.[2]—The case was one of stricture followed by perineal abscess. When the patient was first seen the skin was unbroken; when seen two months later there was no sign of

[1] "Epithelioma from Male Urethra," 'Trans. Path. Soc. Phil.' (1874–75), 1876, v. 178.

[2] 'Lancet,' 1885.

new growth, but at the end of another five months the perineum was the seat of an extensive and deep epithelioma.

Since the publication of Kauffmann's monograph (1886) not a few further excellent examples of urethral carcinoma in the male have been recorded, the history and general characters of most being remarkably alike.

1889, Griffiths.[1]—The patient, aged 70 years, was admitted into Addenbrooke's Hospital, Cambridge, March 31st, 1887, under the care of Sir George Murray Humphry.

There was no history of gonorrhœa or syphilis, or of any injury to the perineum, nor had he suffered from any urethral trouble until eight or nine weeks before admission.

Soon after being in the hospital a swelling with rounded, ill-defined margins was found in the position of the bulb and corpus spongiosum, a short distance along the penis; the corpora cavernosa were found implicated in a similar swelling to about an equal extent. Urine was seen to escape from certain perineal openings which were present at the time of admission.

On May 10th another hard, symmetrical swelling was found at the junction of the scrotum and perineum; it became very prominent, and the skin over it hardened. On May 20th perineal section was performed to relieve the urinary troubles. Death occurred about a fortnight afterwards.

A median section of the bladder and penis showed that the posterior two thirds of the corpus spongiosum and the posterior half of the corpora cavernosa were replaced by a firm, dense, and whitish new growth.

The corpus spongiosum in the region of the bulb was nearly half an inch in thickness; beyond the middle of the penis the amount of new growth gradually diminished, and ceased about an inch from the corona glandis. In front of and below the posterior half of the penis the skin and subcutaneous tissues were much thickened and hard, this being in great part due to the formation of old fibrous tissue. There were no evidences whatever pointing to the conclusion that the growth originated in this situation and attacked the parts of the penis subsequently. The prostate was unaffected. There were no secondary growths nor any enlarged glands. The tumour proved to be, on microscopical investigation, an "ordinary squamous-celled epithelioma."

[1] 'Path. Soc. Trans.,' vol. xl, 1889.

1891, O. Witzenhausen.[1]—Two cases are described by this author from the records of the Heidelberg Surgical Clinic of Professor Czerny.

The first was that of a man, aged 48 years, admitted to the Surgical Clinic in March, 1877. When ten years of age he received a kick on the glans by which the prepuce was torn, from which time there was some hindrance to the flow of urine in the neighbourhood of the glans. He had never contracted gonorrhœa. About ten weeks before coming to the Clinic the difficulty of micturition increased, and a swelling formed, which broke, and from which pus and urine escaped.

The fistula healed after about four weeks, and then broke open again; at the same time a second swelling formed at a spot somewhat in front, and this also broke.

When admitted, the prepuce was so tight that only a small part of the glans could be uncovered; there were two fistulæ in the perineum, from which pus and urine escaped during micturition. The external meatus was narrow. The diagnosis of stricture was made, and the fistulæ of the perineum and scrotum were slit up. On digital exploration a wide cavity was reached with ragged walls, and in it a round body as thick as the finger, which was taken to be the bulb. When this was cut, in order to find the urethra, the substance appeared granular and was hard, like a carcinoma. A microscopic examination made on the spot proved the disease to be epitheliomatous.

The hinder end of the urethra was found in the carcinomatous tissue and into it a catheter was passed. The carcinoma was free of the rectum, but adherent to the ascending ramus of the right ischium, the corpus cavernosum being partly destroyed at this spot. The patient left on May 9th, and died half a year later.

The second case was that of a man, aged 55 years, admitted to the Clinic in January, 1889. He had suffered since early youth from difficulty of micturition, which followed a painful, purulent discharge. Ten years before admission he contracted gonorrhœa; stricture ensued, the urine being drawn off at length only by means of a fine catheter. Three or four months before the patient was seen, severe pain and perineal swelling occurred whilst he was riding; the swelling broke in different

[1] 'Beiträge zur klin. Chir.,' Paul Bruns, 1891, vol. vii, p. 571.

places, and fistulæ formed in the perineum and scrotum, from which pus and urine escaped. A diagnosis of stricture with multiple fistulæ was made; the prostate was not enlarged.

On operation from the perineum the knife penetrated a firm, and, to the naked eye, carcinomatous tissue; immediate microscopic examination confirmed the diagnosis of epithelioma ("cancroid"). As much of the growth was removed as possible, and an elastic catheter passed in. Extensive suppuration followed. Death took place on June 8th.

1893, Marcus Beck.[1]—A man, aged 62 years, admitted into University College Hospital with perineal induration, occupying the situation of the whole of the bulbous urethra. The patient had contracted gonorrhœa when eighteen; stricture followed. The skin over the swelling was freely movable.

As no instrument could be passed a median perineal incision was made into the solid mass, when a cavity containing blood-stained, purulent fluid mixed with urine was opened; on the incision being extended, the tissue surrounding this cavity was found to resemble exactly that presented by a carcinoma of the lip or tongue. A piece of the tissue removed for histological examination showed the structure typical of squamous-celled carcinoma, with an abundance of cell-nests.

The patient, at his own wish, left the hospital three months later. No examination was obtainable after his death.

In this article Beck gives a list of, and cites, those previously recorded cases which he was able to discover.

Like his predecessor, Kaufmann, Beck fails to be exhaustive; he has given some of the cases, but not all, of those overlooked by Kaufmann, and he himself omits the two published by Witsenhausen in 1891, after the appearance of Kaufmann's work.

Ten years after the publication of Beck's article Hall professed to furnish a full list of all the cases till then recorded, of carcinoma of the male urethra ('Annals of Surgery,' 1903). Under each case this author gives the date, reporter, reference, the age of the patient, treatment, the microscopical report, and result. By a strange oversight no statement is furnished as to the portion of the urethra affected. Hall, however, fares no better than his predecessors. From his list are omitted at least

[1] 'International Clinics,' second series, vol. ii, 1893.

four cases published before 1903; and there are at least three published during the same year, viz. 1903.

The four cases omitted are as follows, and I have filled in the details in correspondence with Hall's scheme.

Date.	Reporter.	Reference.	Age of patient.	Treatment.	Microscopical report.	Result.
1897	Hottinger	'Correspondenzblatt für Schweizer Aerzte,' vol. xxvii, 1897, pp. 513, 552	55	Amputation	Squamous-celled carcinoma	Well five months afterwards.
1897	Van Hook	'The Chicago Medical Recorder,' vol. xiii, November, 1897, p. 306	53	,,	Carcinoma confirmed by the examination	Recovery.
1898	Binaud	'Ass. franc. d'urol. Proc. Verb.,' 1897, Paris, 1898, ii, p. 410; and in translation in 'Journal of Cutaneous and Genito-Urinary Diseases,' New York, vol. xvi, p. 191	44	External urethrotomy	Encephaloid cancer	Death.
1898	Parascandolo	'Arch. Internaz. di Med. e Chir.,' Napoli, 1898, xiv	—	—	—	—

With Hall's article I may close. From the omissions in each of the lists cited, although the latter aim at completeness, the extreme difficulty of furnishing an exhaustive bibliography by individual effort will be apparent.

It is only by means of an organised system of cataloguing the literature of the world that this is rendered practicable, and at the present time, indeed, possible. Whether the instruction gained by the examination of such cumuli is worth the time and labour entailed is a question which admits of grave doubt. That the multiplication of cases serves a statistical purpose may be granted; yet there is for the most part no real addition made to knowledge, however high the tower of facts is raised.

The aphorism of Morgagni concerning observations will remain true: *Non numerandæ sed perpendendæ sunt.*

As Sir John Tweedy has so well said in his Hunterian Oration[1] of Bacon's method, it was "purely mechanical." "He

[1] Royal College of Surgeons of England, 1905.

imagined that he had discovered a method by which scientific truth might be determined with absolute certainty, and by a mechanical mode of procedure such that all men were capable of employing it."

"Perhaps the Baconian claim," he says, "has never been more convincingly refuted than by Augustus de Morgan, at once one of the profoundest and subtlest thinkers of the nineteenth century."

"Modern discoveries," writes de Morgan, "have not been made by large collections of facts, with subsequent discussion, separation, and resulting deduction of a truth thus rendered perceptible. A few facts have suggested an hypothesis, which means a supposition proper to explain them. The necessary results of this supposition are worked out, and then, and not till then, other facts are examined to see if these ulterior results are found in nature."

Amongst the cases published before 1903 there is one which breaks the general monotony, and to which I may refer, more especially since its pathological diagnosis cannot, I submit, be allowed.

1895.—Oberländer and Johne[1] record under the title of rodent ulcer the case of a man, aged 50 years, in whom a small itching pustule at the external meatus was taken by a quack to be a chancre, and was treated by the application of "Lapis infernalis."

The anterior end of the urethra became the seat of an ulcerating induration, for which the end of the penis was ultimately amputated by Oberländer.

Microscopic examination by Johne showed no evidence of tuberculosis either histologically or bacteriologically. In no spot were there found in the connective tissue isolated epithelial cells or nests suggestive of a carcinomatous formation; rather, were the cells lying thickly in the upper layers of the tissue, but always diffusely, in the main points, young granulation- *i. e.* connective-tissue cells, between which only isolated leucocytes occurred.

The disease had resisted the administration of mercury, so that syphilis was held to be excluded.

[1] 'Centralblatt f. d. Krank. d. Harn. und Sexual-Organe,' Leipzig, 1895, vol. vi, p. 245.

The authors exclude, in short, carcinoma, tuberculosis, and syphilitic lesion, phagedenic or other, the diagnosis of rodent ulcer being thus reached solely by way of exclusion. But what is rodent ulcer? In the specific sense in which the term is used in this country the preceding diagnosis cannot be admitted, seeing that no epithelial structures were met with in the lesion.

The disease appears to have been classed as a rodent ulcer merely in the meaning that it was an intractable, ulcerating lesion without any specific histolological characters.

By British observers not only is the histology of rodent ulcer held to be distinctive, but it is universally differentiated from ordinary cutaneous carcinoma as being a form of malignant disease, which is never followed by glandular or visceral metastasis howsoever long it may last.

An accurate histological summary of the lesion will be found in the last edition, the tenth, of 'Erichsen's Surgery,' vol. ii, p. 12: "The epithelial cells show generally no tendency to become squamous or to form globes. The cells are mostly small and rounded or regular in shape, except the outermost cells of a cell-mass, which are often somewhat elongated. That it does not spring from the superficial epithelium is almost certain, as the cells show little or no tendency to assume the squamous form." Two typical figures accompany this description.

No example of a rodent ulcer as thus understood, has ever been observed in connection with a mucous membrane; it is a lesion peculiar to the skin, the only matter in dispute amongst British authors being in what precise epidermal appendages the disease itself originates.

In Oberländer's case the so-called "Ulcus rodens" arose from the urethral mucosa.

The particular form of carcinoma found in all the recorded cases is noteworthy; in every one it has been of the squamous-celled variety. This would, of course, have been anticipated in carcinoma of the anterior, terminal part of the canal, where the epithelium for a distance of from 5 to 8 mm. is of the stratified kind set over papillæ as on the surface of the glans. In the rest of the penile portion the epithelium has a different character.

The seat of primary urethral carcinoma is in the vast majority of cases the bulb. Of those recorded before the appearance of Beck's article, only one concerned the anterior end of the canal, viz. that reported by Mr. Jonathan Hutchinson.[1]

The epithelium of the bulbous portion is commonly described as columnar. It differs, however, somewhat from such an epithelium as that of the intestine, in that the series of columnar or subcolumnar elements (for their length varies) bounding the canal is succeeded by a many-layered zone of polymorphous or polyhedral cells; the deepest of these has no vertical or palisade disposition as in a stratified, squamous-celled epithelium.

The method of transition between such an epithelium as that of the bulb and that in the immediate neighbourhood of the meatus may be traced in longitudinal sections of the glans.

Behind the glans the epithelium of the penile, the membranous, and the prostatic portions is of the columnar kind as just described.

In such sections, made from the normal adult, it will be found that the papillæ which occur over the glans are represented within, and for a short distance beyond, the meatus.

The epithelium on the papilliferous portion of the urethral mucosa is like that on the glans itself, and consists of a deep vertical or palisade series of cells, upon which lie polymorphous elements, succeeded by a many-layered investment of squamous cells. As the mucosa is traced backwards the papillæ are the first to disappear; the epithelium, however, retains the same characters, yet further inwards. Still more inwardly, the flat-celled surface-layer becomes thinner and thinner, the squamous cells themselves becoming shorter and thicker, until at length they are reduced to a single layer overlying the polymorphous series. The single surface-layer then becomes cubical, subcolumnar, and columnar, the polymorphous elements beneath persisting; the deep palisade series now ceases.

It is easy to see how, by a converse process, epithelium of this columnar-celled kind may become squamous.

Why such a transformation or metaplasia should so regularly occur in the case of carcinoma of the bulbous urethra is not easy to see. The antecedent history in so many of the cases, of

[1] That reported by Mears, and already referred to, is called secondary, but no statement is forthcoming as to the seat of the primary growth.

gonorrhœa succeeded by stricture, is significant in this connection, for such a metaplasia has probably preceded the actual growth of the carcinoma, the interior being altered after the manner of a leukoplakia or keratosis; or, as Thiersch has suggested, the new growth may arise in the scar following the ulceration which has preceded the formation of such a stricture.

The longitudinal extent of the papilloma in the case recorded in the present communication is worth notice. For the lesion possibly comes in the group of those which are known in the skin as linear papilloma, linear nævus, nævus métamerique, papilloma neuroticum, and by other names, some of which, like the last two, are devised according to the theory of pathogenesis adopted by particular dermatologists.

Such linear papillomata are not necessarily appreciable or obvious at the time of birth; nor are they always as narrow as their name would imply.

Amongst the different theories proposed by way of their explanation, the most probable is that which views the congenital or early appearance of the lesion and its linear disposition as indicating a source in the lines of closure of embryonic clefts, including the metameres or segments of the body.

In the museum of St. Thomas's Hospital there is an example of such a one, which was recorded by Mr. H. H. Clutton as a "Papilloma in the Line of Branchial Fissure" ('Path. Soc. Trans.,' vol. xxxv). The growth was congenital, and was excised from the neck of a man, aged 26 years. It had not increased in area. The chief portion lay over the anterior triangle, and overhung the surrounding skin, but had not induced any similar growth in the parts with which it had come in contact. The papilloma extended from the right auditory meatus to the middle of the neck.

Seeing that the penile portion of the urethra is completed in the mid-line by the coalescence of the lateral processes which bound what at first is a simple groove, the papilloma may have had such a congenital basis; it may have been "linear" in kind. Indeed, the perineal raphé itself suggests such a possibility, for it is a redundant elevation of semi-pathological character. Microscopic sections of this linear eminence in the adult show a complete absence of hair and glands, although these are abundant on either of its sides. In transverse section it presents

itself as a well-differentiated semicircular ridge. Although the corium is furnished with simple papillæ the eminence is not itself divided at the free surface; it has not, in such views, an external papillary form, the irregularities of the corium being levelled by the investing epidermis.

In longitudinal sections, however, the eminence is subdivided into low processes, like much extended and flattened compound papillæ. The elevation, in short, is a miniature papilloma linearly disposed.

The absence of hair and glands suggests that the elevation in question is not so much a portion of the true skin as of mucosa ill-enclosed during the fusion of the lips of the urethral groove.

FIG. 31.

A longitudinal section of the perineal raphé of an adult male, showing a complete absence of hairs and glands. The elevation is subdivided into low compound papillary processes, the whole affecting the disposition of a linear papilloma. (Low power.)

EXPLICATIO FIGURÆ.

Perinæi raphe in longitudinem scissa. Pili atque glandulæ absunt. Dividitur eminentia in processubus ut in papillomate lineari.

Whether certain of the papillomata of the uvula met with in children may not arise at the site of some error of median fusion between the halves of this structure is a possibility worth, perhaps, bearing in mind.

The development of carcinoma in the external parts of perineal fistulæ has, of course, to be distinguished from that which occurs in connection with the urethral epithelium. Such cases have been observed by Paget[1] and others. And quite recently

[1] 'Lectures on Surgical Pathology,' 3rd edition, 1870, p. 737.

one has been recorded by Mr. Maynard Smith.[1] The patient, a man, æt. 56, had had for many years a urinary fistula, which had followed peri-urethral suppuration due to stricture. About six months before coming under observation he noticed a fungating growth which showed itself around the orifice of the fistula. When seen, there was a cauliflower-like excrescence about the size of a walnut, surrounding the fistulous opening; masses of enlarged glands were present in each groin. The penis was amputated and the glands removed.

Microscopic examination showed the growth about the fistula (which occupied a site just in front of the scrotum), and that in the lymphatic glands to be of the ordinary squamous-celled variety.

And to finish with a still wider departure from the immediate subject of the present communication:

In a case recently in St. Thomas's Hospital the carcinoma arose in the sinus resulting from a partially-closed ectopic bladder.

The diagnosis of carcinoma was made clinically, none of the tissue being submitted to microscopic examination.

Mr. J. E. Adams has been good enough to supply me with the following account from the Registrar's notes:

C. K—, male, aged 39 years, labourer, was treated in the early seventies by Mr. Sydney Jones, for ectopia vesicæ. Plastic operations were performed and the deficiency in the anterior walls of the bladder and abdomen was reduced to a small sinus on either side of the middle line, the condition of complete epispadias having been untreated. Urine, therefore, was discharged through both of these lateral sinuses and at the neck of the bladder; an appliance was provided, and the patient for many years resumed his work.

In August, 1905, he was re-admitted under the care of Mr. Pitts, on account of his having had discomfort at the site of the left lateral urinary fistula for some years, culminating in severe pain for twelve months, and accompanied with thickening and ulceration of the skin.

On examination the scars of the former operations were to be recognised, and in the centre of the scars on either side of the median line there was a small sinus through which urine escaped. On the left side this was surrounded by a large, prominent,

[1] 'Transactions of the Medical Society,' 1905–6.

funnel-shaped growth, with an ulcerating surface and hard everted edges, the latter being raised three quarters of an inch above the surrounding skin; its base was hard and infiltrated, the growth presenting all the clinical characters of epithelioma. The new growth apparently extended down to the imperfect bladder, as it could be seen again through the urethral opening. There was no ulceration or any marked thickening around the fistula of the right side. Enlarged and hardened glands could be felt in the iliac fossa.

February 20th, 1906.

---

19. *Osteo-lipoma of the brain arising from the infundibulum.*

By F. Parkes Weber and Paul Daser.

The tumour in question was discovered at the base of the brain of a woman who died recently of cardiac failure and chronic interstitial nephritis. In shape and size it resembled a small bean, measuring 15 by 10 by 10 mm. It lay behind the optic chiasma and between the optic tracts, arising from the back of the infundibulum cerebri close to the attachment of the pituitary body (hypophysis cerebri). It had a smooth surface, and on rough examination (Fig. 32 shows the position of the tumour) it appeared to be composed of pale yellow fat, enclosed in a fibrous capsule, which included, on one side of it, a darker and harder nodule, about the size of a small pea, which later examination showed to consist of cancellous bone. The pituitary body was carefully removed, and as it appeared quite normal it was not examined microscopically. Nothing noteworthy was found in the rest of the brain with the exception of a small softening infarct in the cerebellum.

The tumour had produced no symptoms during life and there was certainly no optic neuritis, the eyes having been ophthalmoscopically examined shortly before death. The patient was a woman, aged 29 years, whose first pregnancy (terminated artificially) six years ago, was complicated by kidney disease

and followed by puerperal mania. Some albuminuria and cardiac enlargement persisted till she again became pregnant in 1906. This second pregnancy was, like the first one, artificially terminated at about the eighth month, but she suffered from cardiac weakness, œdema, thrombosis in one lower extremity, and pulmonary embolism, and a deep bed-sore formed in the sacral region. She died shortly after her admission to the German Hospital. The necropsy showed the presence of chronic interstitial nephritis (kidneys of the "mixed" type of nephritis), an adherent thrombus in the proximal portion of the left

Fig. 32.

Showing the situation of the tumour described. (Nat. size). A small area of cancellous bone appears in the centre of the surface of the growth.

internal saphenous vein, and many pulmonary and splenic embolic infarctions; but nothing was found which could in any way be connected with the small tumour at the base of the brain.

Further microscopical examination of the tumour shows it to consist of fatty tisue (ordinary vesicular fat-cells) enclosed in a fibrous capsule which also includes the nodule of spongy bone. Microscopic sections (see Fig. 33[1]) of the latter have been prepared after decalcification by Ebner's method.[2] It is found to

[1] We are much indebted to Mr. S. G. Shattock for his kindness in supervising the drawing of this illustration.

[2] Ebner's mixture for the decalcification of bone consists of four volumes of concentrated hydrochloric acid with 100 volumes of a saturated aqueous solution of sodium chloride and 100 volumes of distilled water.

be composed of trabeculæ of true bone enclosing large spaces filled with red bone-marrow containing hardly any fat. The osseous trabeculæ show the typical arrangement of lacunæ and canaliculi, with here and there an Haversian canal. At one part

FIG. 33.

A microscopic section of the osteo-lipoma, showing adipose tissue on the right side, and proper bone-marrow on the left enclosed in cancellous spaces. Zeiss A. Oc. 4.

active bone-formation is in progress, the surface of a trabecula being covered with osteoblasts; at another part osteoclasts are attached to the bone. Sections have likewise been specially stained with Leishman's and Jenner's stains in order to further examine the bone-marrow in the tumour, and though the coloration by these methods has not been quite successful, we have been able to make out that erythrocytes, erythroblasts and myelocytes constitute the bulk of the cells; scattered here and there amongst

the other cells are large giant-cells and a few fat vesicles. The bony nodule may therefore be said to consist of open cancellous tissue, containing much more bone-marrow than bone. The relative absence of fat-cells in the bone-marrow of the tumour may perhaps be accounted for by the patient's debilitating illness, that is to say, if we suppose that bone-marrow in cancellous osteomata reacts in cases of general illness just like the ordinary bone-marrow of the body does, which latter was unfortunately not examined in the present case.

Remarks on the Literature of the Subject.

Osteomata and lipomata of the brain belong to the great rarities in the way of tumour-formation, but from time to time examples have been recorded, and we shall first of all refer to J. S. Bristowe's case,[1] which seems to be the one most nearly resembling our own. It is the only case recorded in the 'Pathological Society's Transactions,' and it seems to have escaped the attention of subsequent writers on the subject. The patient was a man, aged 44 years, who died of pulmonary tuberculosis, without having shown any signs of the presence of a cerebral tumour. At the necropsy a tumour about as large as a horse-bean was discovered at the base of the brain, having apparently arisen in the infundibulum and corpora albicantia. The tumour consisted of a central mass of true bone (showing lacunæ and canaliculi, with here and there an Haversian canal) covered by a connective tissue containing a "considerable quantity of oil." The case was therefore, both in regard to the nature of the tumour and its position, remarkably similar to the present one.

Thomson Walker,[2] at the Society for the Study of Disease in Children, described the case of a little girl, aged 9½ years, with signs of intra-cranial disease. At the necropsy a cherry-sized tumour was discovered at the anterior part of the interpeduncular space. "Behind it was a cyst, the size of a walnut,

[1] J. S. Bristowe, "Tumour connected with the Brain consisting of True Bone," 'Trans. Path. Soc. Lond.,' 1855, vol. vi, p. 25.

[2] J. W. Thomson Walker, "Case of Primary Osteoma of the Brain," 'Reports of the Society for the Study of Disease in Children,' London, 1902, vol. ii, p. 173. See also Thomson Walker, "Osteomata of the Brain," 'Journal of Pathology and Bacteriology,' Edinburgh, November, 1904, p. 81. Thomson Walker refers to the previously published cases or to nearly all of them.

the walls of which showed calcareous and bony plates, and this communicated with a second smaller cyst, in the floor of the third ventricle, by a narrow opening. The tumour was not connected with the bones of the skull or the membranes. It was embedded in the brain substance except at its under surface, where spicules of bone projected here and there on the surface. The outline of the tumour was irregular, small processes of the bone projecting into the brain substance. It was not surrounded by a capsule of fibrous tissue or fat, as has been described in some cases. The successive stages of bone-formation could be traced as clearly as in a developing bone. . . . There were no secondary deposits in any part of the body."

The position of the tumour in the above-described cases (including our own) is almost identical, and is, as Thomson Walker points out, strongly suggestive of the origin of the tumour, according to Cohnheim's theory, from an aberrant nodule of embryonic tissue, the infundibulum being a spot in which such developmental errors might be expected to occur.

In connection with Thomson Walker's case, and in regard to his remarks on the subject, two cases described by F. Langer[1] should be referred to. They were examples of cystic tumour-formation at the base of the brain, and careful macroscopic and microscopic examination convinced Langer that in both cases the cystic development proceeded from the posterior part of the infundibulum cerebri.

The next case to be mentioned is one described long ago by L. Benjamin.[2] The patient was an epileptic and imbecile man, aged 32 years, and the growth occupied the posterior part of the corpus callosum, extending into both cerebral hemispheres, chiefly into the right. Though the site of the tumour was different from that in the preceding cases, it seems to have been formed of an inner portion of cancellous bone surrounded by fat and a connective-tissue capsule, much as in our own case. Benjamin regarded the tumour as an ossified lipoma.[3] Surely,

[1] F. Langer, "Ueber cystische Tumoren im Bereiche des Infundibulum Cerebri," 'Zeitschrift fur Heilkunde,' Berlin, 1892, vol. xiii, p. 57. Langer also referred to some possibly similar cases in the literature, which, however, had not been so thoroughly examined as his own two.

[2] L. Benjamin, "Beschreibung einer Knochengeschwulst im Gehirn," 'Virchow's Archiv,' 1858, vol. xiv, p. 552.

[3] In regard to mere calcification of lipomata, Benjamin points out that the process is rare in human, but not in animal pathology.

however, ordinary fibrous, bony and fatty tissues are so intimately connected with each other that there would be nothing surprising in all three of these occurring in a tumour (a kind of "mesoblastic teratoma") growing from an aberrant fragment or remnant of embryonic mesoblast,[1] and as a matter of fact, whenever true bone or fatty tissue occurs in tumours, the bone or the fat seems to be preceded by, and directly formed from fibrous (or embryonic "fibro-blastic") tissue, excepting in tumours which contain both bone and cartilage and in which the growth of the former proceeds from the latter. The occurrence of cysts in connection with osteomata of the brain would be intelligible on the "mesoblastic teratoma" theory.

The osteomata in various parts of the brain described by A. Bidder,[2] W. Ebstein,[3] F. Meschede,[4] Ranvier,[5] Robert Hooper,[6] L. Witkowski,[7] and Virchow,[8] concern us less. In Bidder's case the tumour was situated in the corpus striatum of a man, aged 59 years. The large osteoma described by Ebstein was found embedded in the left half of the cerebellum of a woman, aged 44 years, and measured 4·5 by 2·9 by 3·2 centimetres. It contained spaces filled with bone-marrow and was separated from the brain-substance by a connective-tissue capsule. In Meschede's case the patient was an epileptic and imbecile man, aged 30 years, and the osteoma, embedded in the left frontal lobe, was as large as a walnut; on its upper surface was some gelatinous myxomatous tissue. In Ranvier's case the bony tumour was embedded in the cerebellum; it was nearly spherical in shape and about two centimetres in diameter. Robert Hooper knew of two cases of apparently true bony tumour of the brain. One

[1] See Thomson Walker, *loc. cit.*, and A. Bidder, "Ein Osteom des Corpus striatum bei Hemiplegia infantilis," 'Virchow's Archiv,' 1882, vol. lxxxviii, p. 91.

[2] A. Bidder, *loc. cit.*

[3] W. Ebstein, "Grosses osteom der linken Kleinhirnhemisphäre," 'Virchow's Archiv,' 1870, vol. xlix, p. 145.

[4] F. Meschede, "Osteom der grossen Gehirns und Ventrikelbildung in Ammonshorn, beobachtet bei einem Epileptischen," 'Virchow's Archiv,' 1866, vol. xxxv, p. 472.

[5] L. A. Ranvier, "Tumeur osseuse dans le cervelet," 'Bulletins de la Société Anatomique de Paris,' 1862, vol. vii, p. 219.

[6] Robert Hooper, 'Morbid Anatomy of the Human Brain,' London, 1826, p. 29, and Plate XII, fig. 7.

[7] L. Witkowski, "Ueber Knocken-und Concrementbildung im Gehirn," 'Archiv für Psychiatrie,' Berlin, 1883, vol. xiv, p. 415.

[8] R. Virchow, 'Die krankhaften Geschwülste,' Berlin, 1864, vol. ii, pp. 97, 98.

of these osteomata was found in the frontal lobe of a blind girl, aged 10 years; the other was discovered in the left cerebellar hemisphere of an adult woman, and was about the size and form of the eatable part of a small walnut. Witkowski described a tumour of cancellous bone (that is, containing bone-marrow), which was bigger than a walnut, and was embedded in the left cerebellar hemisphere of a man, aged 79 years. Virchow mentioned three cases which he had himself observed, namely (1) a cherry-sized osteoma surrounded by a fibrous capsule in the left cerebral hemisphere of a woman, aged 27 years; (2) a small, irregular nodule of bone in the left optic thalamus of a woman, aged 40 years; (3) an ivory-hard osseous tumour of the size of a cherry-stone from the cerebellum of an old woman. It may be noted by the way that in most of these cases the patients were females.

We have not come across many records of cerebral lipomata. Taubner[1] has described the case of a man, aged 22 years, in whom a pure lipoma, of the size of a hazel-nut, was found at the necropsy in the region of the corpora quadrigemina. Other cases of lipoma of the brain have been recorded by Virchow,[2] etc. In Leichtenstern's case, brought before the Aerztlicher Verein in Köln[3] the lipoma, arising from the pia mater over the corpus callosum, was not known to have produced any symptoms during life. *June 4th,* 1907.

[1] Taubner, "Zur casuistik und Entwickelung der Hirnlipome," 'Virchow's Archiv,' 1887, vol. cx, p. 95.

[2] R. Virchow, 'Die Krankhaften Geschwülste,' 1863, vol. i, pp. 386–388.

[3] Leichtenstern, "Lipom des Balkens," 'Deutsch. med. Wochenschrift,' 1887 No. 52, p. 1128.

1. *Fatty degeneration of the blood.*

By S. G. Shattock and L. S. Dudgeon.

(With Plate VIII.)[1]

De sanguinis degeneratione adiposâ.

(Cum tabulâ VIII.)

Summarium.

Quum in memoriam revocemus causas degenerationis adiposæ præcipuas toxæmiam atque anæmiam esse, quærere impellimur; nonne hæ conditiones morbidæ sanguinem ipsum, ut alias telas, afficiunt, et degenerationem leucocytorum adiposam forsitan causant?

Operandi modus: Super vitrum linitur sanguis, et statim vapori formalini subjicitur, deinde horas viginti quattuor in liquore Scharlach (75 per centum alcohol) immergitur, lavatur, liquore hæmaluminis tingitur, et denique in liquore Farrant conditur.

Observationes nostras nuntiavimus Junio 2, 1906 ('British Medical Journal').

Morborum diversorum casus septuaginta octo indagavimus, quorum exemplis in quibusdam puncta invenimus adiposa in leucocytorum cytoplasmate polymorphonucleatorum.

Sequitur horum cataloga: Chlorosis graviditatis, toxæmia, Brightii morbus, pneumonia, purpura, myelæmia, influenza, lymphadenoma, carcinoma pylori,

[1] These observations, with the exception of the details of the cases referred to, are published also in the 'Proceedings of the Royal Society,' London, 1907.

diabetes cum lipæmiâ, meningitis cerebrospinalis acuta, pleuritis cum pericarditide.

Casubus in quibusdam aliis (diphtheria, anæmia perniciosa) apparuerunt in leucocytis puncta sive granula insigniter tincta, magis fusca autem quam rubra ac sine pelluciditate punctorum adiposorum propriâ.

Hæc, tamen, degenerationem indicare, opinamur, haud illi dissimilem quæ adiposa habetur, quod sanguine prius in alcohol absoluto quam in liquore Scharlach immerso, puncta non discerni possunt.

Erroneous as histological research has proved Hunter's view of the organisation of effused blood to be, yet Hunter was the first to discern the biological truth that the blood is alive—alive in as strict a sense as is any other component part of the living body.

To view the blood as a tissue is a natural extension of the same conception, a tissue, that is, of mobile elements, and one in which the plasma represents a fluid in place of a solid intercellular material.

Yet even in regard to this quality we may discover gradations between the opposite extremes like those presented by blood and cartilage, in such intermediate forms as mucous tissue where the intercellular substance may be equally well called semi-fluid or semi-solid.

If there is a parodox in such an application of words, it is not so much that the incongruity marks an error of conception as that terms used in one stage of science become inadequate to compass biological truth, which, as it grows under observation, defies the artificial limitations which language would impose upon it.

In a similar manner has the common conception of a crystal been dissipated by the sheer force of observation.

For the researches of Lehmann and of Schenck[1] have made it clear that certain fluids may retain the characteristic crystalline feature of containing doubly refractive bodies.

[1] 'Flussige Kristalle,' Leipzig, 1905, cited by J. C. Adami, F.R.S., and L. Aschoff, 'Proc. Roy. Soc.,' B, vol. lxxviii, 1906.

The conception of a fluid crystal is not less paradoxical than that of a fluid tissue.

One peculiarity in the constitution of the blood whereby it differs from other tissues is, of course, the fact that although its cells, as in the more stable forms, undergo division, both mitotic and amitotic, and have, in this sense, a life of their own, yet the primary sources of its elements are the blood-forming organs—the bone-marrow, the hæmolymph and lymphatic glands, or other lymphatic tissue, and the spleen.

And in considering diseases of the blood, therefore, there is a double question involved; there are, firstly, the changes in the blood arising from disease of the blood-forming organs; and secondly, the abnormal changes of the formed blood, arising from lesions proper to the blood itself.

Conceiving of the blood, then, as a complex tissue, and subject like any other to parasitic and bacterial infection, or partaking in the morbid changes of many other specific diseases, it might be imagined that it would likewise be subject to degenerations, and more particularly to the chief and most widespread of all of these, viz. fatty.

The blood degeneration, which has been as yet most studied (other than the so-called polychromatophilic of the red-cells), is that which is usually regarded as glycogenic, and consists in the abnormal, *i. e.* excessive, appearance of glycogen, chiefly in the finely granular polymorphonuclear leucocytes, although the granules occur also in the eosinophil or coarsely granular polymorphonuclear cells, and to a lesser degree in the lymphocytes.

To this form of degeneration (which is known also as iodinophilic or iodophilic, since the grains and granules take a brown colour after treatment with iodine solution) we will refer again in connection with certain ambiguous appearances met with by ourselves in blood-films treated with Scharlach solution.

If we except pathological effusions such as those of pleurisy and peritonitis, and purulent exudations, the process of fatty degeneration has hitherto been looked for and studied only in the solid tissues.

Yet it will be apparent on theoretical grounds that in cases where fatty degeneration of the last-named tissues is due to a deficient oxygen-carrying power of the blood or to a toxic condi-

tion of it, the state of the blood might react upon itself so as to induce similar changes in its own cells.

The chief causes of fatty degeneration in general, excluding those of a local character which produce only a local change and have no interest in connection with the present subject, are profound anæmias and certain forms of toxæmia, whether bacterial or of inorganic causation, as especially illustrated in phosphorus poisoning.

In the first the fatty degeneration of the various organs results from the reduction in the oxygen-carrying power of the blood. In the second, it results directly from the injurious action of the toxin upon the cells of the tissue.

Our inquiry, therefore, is: Does the blood itself suffer similarly in these two groups of morbid conditions?

(1) Do the leucocytes (leaving the red cells out of consideration) suffer from a defective oxygen-carrying power of the blood itself?

(2) Do the leucocytes suffer from the direct action of toxins circulating in the blood in profound toxæmia?

In the blood, as in other tissues, the distinction must be drawn between fatty infiltration and fatty degeneration.

Without entering into the chemical question as to the source of the fat in fatty degeneration, how far, *i. e.* it is due to a transformation of the proteid of the cell (as once held), and how far to the accumulation of fat reaching the cell from without and appearing in it because not utilised, the cardinal difference between the two processes remains, even though the source of the fat should be the same in both.

In the one case the fat accumulates or is stored in a cell, of which the cytoplasm is uninjured; in the other it appears for the reason that the latter is damaged and rendered incapable of utilising the fat which reaches it.

With the fat that is not free, but combined in the cell, neither term deals; the presence of this is not recognisable either by its micro-physical or micro-chemical properties.

Technique.

At the outset it is obviously essential to exclude the use of fat solvents like absolute alcohol and ether as fixing reagents, and essential also that the blood should not be dried.

One preliminary method we tried was the use of blood clot, but it proved less satisfactory than that of making films.

Microscopic sections are readily cut from cylinders of blood that has been received into, and allowed to clot in, narrow tubes, the clot being afterwards fixed in salt-formol followed by 80 per cent. alcohol. Such sections can be stained for fat like those of other tissues. The method, again, of using washed corpuscles (*i. e.* corpuscles washed in salt solution after having been separated by the centrifuge from blood in which clotting has been prevented by the addition of citrate of sodium solution) offers no special advantages, and after making a trial of it we

FIG. 34.



A diagram showing the glass formol chamber and zinc grating used to fix the blood films. The glass lid is not represented. Below the perforated zinc the space is filled with cotton wool soaked in formol solution, 40 per cent. (Slightly reduced.)

EXPLICATIO FIGURÆ.

Monstratur camera in quâ sanguis præparatur. Infra cancellos camera cum gossipio (liquore formol madefacto) impletur. Cameræ operculum omittitur.

did not adopt it. The method finally chosen was that of making films on slides and cover glasses. The film from first to last must be kept moist, and treated, in short, throughout as a section of any tissue which is to be studied for the presence of fat. The reason for this will be obvious, for any fat in the leucocytes would in the dried film tend to transude and become lost by diffusion in the surrounding area.

The film having been made on the slide in the usual manner

by drawing a second slide in front of the blood, the slide is immediately placed, with the film downwards, in a specially devised chamber of formol vapour.

The chamber we use is a deep, oblong glass with a ground edge, and is itself hardly larger in sectional area than an ordinary microscopic slide. This is packed nearly to the top with cotton wool thoroughly soaked with formol (40 per cent.), and on the top of the wet wool is laid a grating of perforated zinc, near either end of which is soldered a cross strip of zinc wire; the latter prevents the film from touching the grating, through which the vapour freely passes to fix the film. The chamber is covered with a piece of overlapping plate glass, after vaseline has been painted over the edge.

Before the slide is prepared, the cover-glass films can be made in the usual manner and placed with the blood upwards upon the perforated zinc. The glass lid being immediately replaced, the slide-film is prepared and introduced with the film downwards, over the cover glasses, from off which it is kept by means of the cross pieces of zinc wire on which it rests.

After not less than fifteen minutes, though the films may be left in the vapour for twenty-four hours or longer, if convenient, the slide is removed and at once placed in the vertical position in a glass of Scharlach for twenty-four or forty-eight hours.

The cover-glasses are placed separately in hollowed glass blocks of the dye, accurately covered to prevent evaporation.

After a certain amount of experience we adopted, as a check, the practice of treating one of the cover-glasses after removal from the formol, and before its transference to the Scharlach, with absolute alcohol, followed by ether, and again by absolute alcohol; the object of this was to remove any fat or fat-like bodies from the cells of the film. At first, in making the cover-glass films, we adopted the plan of adding salt solution to the blood on the cover, in order to prevent any possibility of the film drying; the film itself was made on each cover-glass separately by means of a platinum loop. This precaution was found to be unnecessary, and we therefore discarded it.

The use of alcoholic solution of Scharlach as a fat stain requires much care, for the dye readily precipitates. The solution we employed was made by saturating 75 per cent. absolute alcohol in the cold, and subsequent filtration through paper first wetted

with alcohol. In the case of a slide, the latter was placed straight from the formol chamber into the Scharlach solution, and after twenty-four or forty-eight hours withdrawn, washed for a few seconds in 75 per cent. alcohol, then in distilled water, and after this stained in a bath of hæmalum for three minutes. This was followed by washing in distilled water, and then in tap water, the film being finally protected with a long cover-glass after the application of Farrant's medium. The cover-glasses were prepared in a similar manner.

Our observations were commenced in April, 1906, and on May 29th, 1906, at the meeting of the Pathological Society of London, held on that date,[1] we made a preliminary statement to the effect that we had discovered the existence of fatty degeneration in the blood in certain morbid conditions. We are not aware that any similar observation has been published before this announcement. The only work of a similar kind of which we know, indeed, is that carried out by Professor Antonio Cesaris-Demel, at the Institute of Pathological Anatomy of the University of Pisa. Of this a preliminary note was published very shortly after our own, viz. in June 1906, having been communicated to the Royal Academy of Medicine of Turin at its sitting of June 8th, 1906.[2] The title of the note is, "On Degenerative Changes of the Leucocytes of the Blood, Studied by the Method of Coloration in the Fresh State." The author gives no detailed account and no figures, although he states that the stain used by him was Sudan III, one closely allied to that used by ourselves.

Our examination of blood-films extends altogether to seventy-eight cases, and comprises various morbid conditions. Nevertheless it is in comparatively few only that we have satisfied ourselves of the presence of fat in the leucocytes, *i. e.* of points or droplets presenting the same physical characters and coloration with Scharlach, as those seen in the typical form of fatty degeneration of the cardiac muscle or renal epithelium.

List of diseases in which the blood was examined for fatty degeneration.—Pernicious anæmia, toxæmia of pregnancy, subphrenic abscess, chlorosis, diphtheria, appendicitis, lymphadenoma, acute meningitis, post-nephric abscess, anæmia of undeterminal origin, myelæmia, influenza, exophthalmic goitre,

[1] 'Brit. Med. Journ.,' June 2nd, 1906.

[2] 'Giornale della R. Accademia di Medicina di Torino,' Giuno-Luglio, 1906.

acute pneumonia, chronic Bright's disease, purpura, pericarditis (rheumatic), anæmia (secondary), septic nephritis, myxœdema, pleurisy with pericarditis, septic broncho-pneumonia, carcinoma of pylorus, subacute rheumatism (probably gonorrhœal), diabetes with lipæmia, hepatic suppuration, ulcerative endocarditis, rickets, acute cerebro-spinal meningitis. In the case of some of these diseases more than one example was studied.

List of diseases in which fat was found in the leucocytes.—Chlorosis, toxæmia of pregnancy, chronic Bright's disease with anæmia of chlorotic type, acute pneumonia, purpura, carcinoma of pylorus with anæmia of chlorotic type, diabetes with lipæmia, myelæmia, influenza, lymphadenoma, pleurisy with pericarditis, acute cerebro-spinal meningitis.

The following is a more detailed account of the particular cases from which the preceding list is compiled. The numbers affixed to the cases are those given to them as they appeared in the full list of the whole seventy-seven.

Case 2.—Myelæmia.

History.—Male, aged about 45 years. Patient was quite well until Christmas, 1905. From that time he suffered from continual sore throats, sweating at night, and pyrexia, varying from 100° to 103° F. until early in April, 1906. The spleen, which was only just palpable at first, very rapidly increased in size and extended down to the level of the umbilicus. There was no bleeding from the gums or elsewhere.

The patient was at first treated with arsenic, but from April 23rd onwards X-ray treatment was adopted in addition.

The first blood examination was made on April 12th, 1906. There was slight anæmia, chiefly from loss of hæmoglobin (colour index 0·7), and a leucocytosis of 42,000 per c.mm. Nucleated red cells were very numerous, especially megaloblasts, and there was marked polychromatophilia and basophilic granulation of the red cells. Mast-cells amounted to 5·2 per cent., neutrophilic myelocytes 13·6 per cent., and eosinophilic myelocytes 2·6 per cent.

One month later, May 14th, after a course of X-ray treatment the blood was re-examined. There was now severe anæmia, the ed cells numbering just over 2,000,000 per c.mm. and the hæmo-

globin 30 per cent., while the leucocytes had diminished to 1040 per c.mm. The nucleated red cells were now extremely scarce. The result of the differential count of the white cells was extraordinary. The mast-cells had greatly diminished in number, both absolutely and relatively, there were no eosinophilic cells, and the only myelocytes present were neutrophilic, and these were scarce.

The third blood examination was made on May 28th.

The patient was now extremely ill and appeared to be in a dying condition; he was, however, removed to his house in the country.

The anæmia was now intense. The colour index was only 0·5, and the red cells numbered just over 1,000,000 per c.mm. Agglutination of the erythrocytes was very well shown in the fresh film of the blood. No nucleated red cells were seen, and there was absence of any basophilic granularity of the red cells. The leucocytes numbered 1760 per c.mm. There were no mast-cells, only 0·4 per cent. of myelocytes of all varieties, while the so-called non-granular mononuclear cells amounted to 69 per cent.

Scharlach reaction.—*Examination on May 14th,* 1906. *Finely granular polymorphonuclear leucocytes.*—Most of these cells show deeply-stained red points in considerable numbers; in some, certain of the points are considerably larger than the normal cell granules.

Eosinophil leucocytes.—A few contain a certain number of red points, the proper eosinophil granules staining of a pale Bismarck brown.

Large mononuclear cells.—Some show distinct deep red points. (It is not possible in films so treated to distinguish between the large mononuclear leucocytes and finely granular myelocytes.)

Lymphocytes.—These show no red points.

One of the two cover-glass films prepared was treated, after fixing in formol vapour, with absolute alcohol (once changed) for three quarters of an hour before being placed in the 75 per cent. alcoholic Scharlach solution.

The cells in this showed no red points.

Case 3.—Toxæmia of Pregnancy.

History.—L. E—, aged 24 years. This was the patient's first confinement. Vomiting had lasted for six weeks before admission

to the hospital. On admission there was clinical evidence of jaundice. The liver was enlarged. There was no œdema of the skin.

The urine contained a faint trace of albumen and globulin. There was a large amount of nucleo-proteid present, but no albumose. Bile pigments were present, but no bile acids and no reducing substance. No leucin or tyrosin were found. There was no blood, *but fat was present in the urine.* There was a fair deposit of pus; and hyaline, granular, epithelial, leucocytal, *fatty,* and colloid casts were seen. Amyloid reaction was not obtained in any of the casts.

The leucocytes numbered 4600 per c.mm. The specific gravity of the blood was 1·052. The blood serum contained bile pigment, but there was no evidence of hæmolysis. The patient's serum had no agglutinative action on normal red cells. Very light pyrexia was noted. Labour was induced, and the patient made a complete recovery.

Scharlach reaction.—*Finely granular polymorphonuclear leucocytes.*—All contain considerable numbers of deep red, sharply-defined points.

Some of the points are of a copper or chocolate colour, and more opaque than the others. The other forms of cell hold none. In the plasma of the film there are numerous minute points which take the red stain.

Case 5.—Eosinophilic Pleurisy, Influenzal.

History.—Female, aged 23 years. The patient was taken suddenly ill on March 31st, 1906, with an acute illness from which she eventually died on August 25th, 1906.

The chief complications which arose during the acute illness were acute pleuritis with effusion, and acute pericarditis, and an acute inflammation of the tissues around the right knee-joint which rapidly cleared up. There was a marked degree of remittent fever during the first two months of her illness.

A cytological examination of the pleural exudate gave the following result in 500 cells:

Coarsely granular eosinophils .	173 : 34·6	per cent.
Polymorphonuclear neutrophils .	50 : 10	„
Small lymphocytes . . .	115 : 23·0	„
Endothelial cells . . .	162 : 32·4	„

Well-marked fatty changes were seen in the polymorphonuclear neutrophils, and fine fat droplets, in a few of the coarsely granular eosinophils. No micro-organisms were discovered.

There was a slight degree of anæmia at first accompanied by a leucopenia, and an absolute and relative eosinophilia. The typhoid serum reaction was negative.

A cytological examination of the sputum showed entirely micro- and macrophages; the *Staphylococcus aureus* and *albus* were grown on culture.

Another blood examination was made after the acute period of the illness had subsided; this showed rather more anæmia, normal numbers of leucocytes, and absence of eosinophils.

At the *post-mortem* examination there was found chronic pleuritis associated with pericarditis. There was well-marked fatty change in the muscle-cells of the heart, and the remains of a hæmorrhagic infarct.

Scharlach reaction.—*Finely granular polymorphonuclear leucocytes.*—Examination made May 12th, 1906. Deep red points occur in considerable numbers in these cells. None in the other forms.

One of two cover-glass films was treated, after fixing in formol vapour, with absolute alcohol, once changed, for three quarters of an hour, before being placed in Scharlach.

The finely granular cells in this preparation showed no red points.

Case 6.—Myelæmia.

Scharlach reaction.—*Finely granular polymorphonuclear leucocytes.*—In some there occur fine red points in varying numbers.

Case 9.—Chlorosis.

History.—Out-patient; none obtained.

Scharlach reaction.—*Finely granular polymorphonuclear leucocytes.*—All hold, in varying numbers, fine red points. Fine fat droplets are present in the plasma of the film.

Case 20.—Chronic Nephritis associated with a certain degree of Chlorotic Anæmia.

History.—Female, aged 13 years. The illness, as far as it was possible to ascertain, was of about twelve months' duration.

The patient was anæmic and had ascites accompanied with general anasarca.

The urine contained a large amount of albumen and numerous casts, including fatty; no blood was present and no albumose.

There was never any pyrexia.

The heart was enlarged and the pulse tension was high.

In the treatment of the disease sodium chloride was omitted as far as possible.

A complete blood examination was made with the result that a certain degree of chlorotic anæmia was detected.

Scharlach reaction.—*Finely granular polymorphonuclear leucocytes.*—Many hold red points and larger droplets of a faint pink colour.

One of two cover-glass films, after fixing in formol vapour, was submitted to absolute alcohol, once changed, for three quarters of an hour before being placed in Scharlach.

None of the leucocytes in this preparation showed any coloured points.

Case 24.—Acute Pneumonia.

History.—The blood was examined on the sixth day, two hours after the crisis. The patient was afterwards discharged well.

Scharlach reaction.—*Finely granular polymorphonuclear leucocytes.*—No inconsiderable number hold red points and larger droplets of fat.

There are some fine pale red points in the plasma of the film.

Case 27.—Lymphadenoma.

History.—Male, aged 20 years. There was general glandular enlargement, especially of the cervical glands, which were tender on palpation. The spleen and liver were not found to be enlarged.

Intermittent pyrexia lasted during his entire stay of seventeen days in hospital.

A complete blood examination was made, but only a very slight degree of anæmia was present, and this was due to diminution in the percentage of hæmoglobin.

Scharlach reaction.—*Finely granular polymorphonuclear leuco-*

cytes.—In a certain number there are a few transparent red droplets of varying size.

Case 35.—Broncho-pneumonia.

History.—A child, aged 1 year and 11 months. Blood examined on the third day. Discharged afterwards, well.

Scharlach reaction.—*Finely granular polymorphonuclear leucocytes.*—Some hold fine pale red points in moderate numbers.

Case 47.—Pleurisy with Effusion, and Pericarditis.

History.—Female, aged 21 years. The patient was in the hospital with dry pleurisy followed by pleuritic effusion on the left side, and accompanied with acute pericarditis.

During a period of forty-six days she had severe remittent pyrexia, with occasional intervals of intermittent fever. The pulse and respiration were very rapid. The urine is said to have been normal.

There was considerable cyanosis and dyspnœa at periods during the height of the illness.

A blood culture was made, but with a negative result.

There was a considerable degree of anæmia at first, accompanied by a slight leucocytosis up to 14,200 per c.mm., and 83·6 per cent. of polymorphonuclear neutrophils. There was marked polychromatophilia, and one megaloblast was present.

A second blood examination, three weeks later, showed a considerable improvement. The leucocytes had then returned to the normal.

Film preparations of the pleuritic exudate showed 80 per cent. of microphages and 13 per cent. of macrophages. Ingestion of the micro- by the macrophages was well instanced.

The patient was treated with Metschnikoff's serum and with nuclein (May 28th, 1906), and various drugs were also given.

Scharlach reaction.—*Finely granular polymorphonuclear leucocytes.*—In a certain number there are fine red points, in others transparent rose-pink droplets of varying sizes.

Case 55.—Carcinoma of Pylorus.

History.—Male, aged 67 years. Patient was very emaciated and had suffered from vomiting for nine months before admission to the hospital. There was marked dilatation of the stomach, and a large growth was felt in the pyloric region.

There was no pyrexia while the patient was in the hospital.

The urine was normal.

The blood showed a marked degree of chlorotic anæmia.

Acute bronchitis and œdema of the lungs were found at the autopsy, and a large carcinomatous growth of the pylorus.

Scharlach reaction.—*Finely granular polymorphonuclear leucocytes.*—In a certain number there occur a few red droplets of conspicuous size.

Case 60.—Myelæmia.

History.—Male, aged 39 years. The patient furnished a typical example of chronic myelæmia.

The spleen was enormously enlarged and occupied most of the abdomen. The liver was also enlarged.

There was well-marked pyrexia during the patient's stay in the hospital.

The urine contained a distinct trace of albumen.

A complete blood examination was made on three occasions. There was a certain degree of anæmia, chiefly loss of hæmoglobin, and a marked leucocytosis. On the first occasion on which a blood examination was made the leucocytes numbered 329,000 per c.mm. Numerous nucleated red cells were seen. The granularity of the blood was well shown. All varieties of myelocytes varied in numbers from 25 to 16 per cent. Mast-cells were numerous.

Patient was treated entirely with arsenic.

Scharlach reaction.—*Finely granular polymorphonuclear leucocytes.*—Not a few contain fine, somewhat dark red points, and paler droplets of fat.

Large mononuclear cells.—A few of these show similar appearances.

CASE 61.—PURPURA.

History.—Male, aged 7 years. The patient had purpuric spots all over his body, off and on, during a period of two months. There was absence of pain, swelling of joints, or any gastro-intestinal disturbance. Purpuric eruption was present in the mouth, especially on the hard palate. A soft, systolic murmur was heard at the heart apex and conducted into the axilla.

The urine contained a faint trace of albumen.

There was very slight pyrexia.

Blood examination showed some degree of anæmia and a slight relative and absolute increase of the lymphocytes and large hyaline cells.

Scharlach reaction.—*Finely granular polymorphonuclear leucocytes.*—A few show slight fatty change.

CASE 70.—ACUTE PNEUMONIA.

History.—Blood examined before the crisis, on the fifth or sixth day.

Scharlach reaction.—*Finely granular polymorphonulear leucocytes.*—A few hold transparent droplets of fat in small numbers, and these contain also, like most of the others, fine points of a chocolate-brown colour.

One of two cover-glass films after fixing in formol vapour was submitted to absolute alcohol, followed by ether, and again absolute alcohol, before its transference to the Scharlach.

The cells in this film showed no red points.

CASE 75.—DIABETES WITH LIPÆMIA FOLLOWED BY TYPHOID.

History.—Male, aged 26 years. The patient's history pointed to diabetes of severe character and of short duration—about six weeks. He passed enormous quantities of urine, as much as 313 oz. in the twenty-four hours. Glucose was present to the extent of from 30 to 40 grains to the ounce. Large absolute quantities of urea, acetone, and diacetic acids were always present in the urine. The temperature was normal for the first few days, but rapidly rose to 103° F., and remained so for five days, when the patient suddenly died.

A blood examination was made, and free fat was found in the serum. A creamy layer separated out from the blood, which

was collected in glass pipettes, soon after withdrawal from the finger. There was a large amount of granular material, which was found not to be one of the higher fatty acids, by the various tests which were employed. The leucocytes were enumerated, but the result was practically normal.

Cammidge's pancreatic test was negative. Free fat was found in the urine.

The patient's serum gave a good agglutinative reaction with typhoid bacilli, but not sufficiently good to justify the reaction being described as "positive."

At the *autopsy* the intestines showed necrosis of Peyer's patches; and there was suppuration of the mesenteric glands. Turbid fluid was found in the peritoneal cavity and in the gall-bladder, the turbidity being due to the presence of innumerable fat droplets.

The kidneys were large and pale.

A pure culture of the typhoid bacillus was obtained from the spleen and mesenteric glands.

Very slight fatty change was present in the cardiac muscle and diaphragm, and also in the liver, and convoluted tubules and glomeruli of the kidneys.

Smears of the bone-marrow from the rib (stained with Scharlach and hæmalum after fixing with formol vapour) showed 7 per cent. of coarsely vacuolated endothelial cells, the contents of which proved to be fat. The percentage of endothelial cells amounted to 53·5 per cent. in a count of 1000.

This marked proliferation of endothelial cells is possibly the result of typhoid infection of the bone-marrow.

The numeration of the other cells of the marrow is as follows:

Finely granular polymorphonuclear leucocytes absent.

	Per 1000.	Per cent.
Small lymphocytes	393	39·3
Large lymphocytes	10	1
Large hyalines	18	1·8
Coarsely granular Eosinophil leucocytes	2	0·2
Neutrophilic myelocytes	35	3·5
Eosinophilic myelocytes	6	0·6
Transitional leucocytes	1	0·1
Endothelial cells	535	53·5
Nucleated red-cells, Normoblasts	6	6·6

Plasma cells, of which a few only occurred, are included under the endothelial count.

Scharlach reaction.—*Finely granular polymorphonuclear leucocytes.*—A certain number hold fat droplets of varying size.

There is an abundance of fat droplets in the plasma.

The peritoneal fluid, removed after death, was full of fat droplets.

The contents of the gall-bladder contained many shed columnar cells, the bases of which were loaded with droplets of fat.

Case 76.—Acute Pneumonia.

History.—Boy. Blood examined five hours after the crisis. Recovery.

Scharlach reaction.—*Finely granular polymorphonuclear leucocytes.*—Some contained droplets of fat. There are also fine, pink, transparent droplets of fat in the plasma of the film.

One of two cover-glass films was treated after fixing in formol vapour with absolute alcohol, ether, and again absolute alcohol, before its transference to the Scharlach.

In this preparation no red points or droplets appeared.

Case 79.—Acute Cerebro-spinal Meningitis.

History.—A boy, aged 14 years. The blood was examined on the second day of the disease, at 2.30 p.m. The temperature was between 102° and 103° F., and the patient was then comatose, though he had been conscious in the morning, and recovered consciousness in the evening. There was a purpuric eruption over the body.

The meningococcus was cultivated from the cerebro-spinal exudate. There was marked leucocytosis.

Complete recovery ultimately ensued.

Scharlach reaction.—A small number of the finely granular polymorphonuclear leucocytes hold fine red points. No free fat was present in the plasma.

If these cases are analysed it will be found that most of them come in the category of toxic diseases, some of an acute kind, others of a chronic. Of the three cases of myelæmia in which

fatty degeneration of the finely granular leucocytes was found, one was acute, two were chronic.

The degree of fever present in these toxæmic diseases varied according as the condition was one of intoxication or infection.

In one of the most pronounced examples of fatty change, viz. the toxæmia of pregnancy, the pyrexia was very light.

In the toxic series may be placed: Toxæmia of pregnancy, acute pneumonia, myelæmia, purpura, acute cerebro-spinal meningitis, influenza, pleurisy with pericarditis, lymphadenoma, chronic Bright's disease (associated with some degree of chlorotic anæmia).

In regard to this group of cases, we believe that the fatty change present in the finely granular polymorphonuclear leucocytes results from the direct action of the toxic substances present in the blood itself; that is to say, that the change is one of proper fatty degeneration, as distinguished from the ingestion or storage of fat by a healthy cell.

The fineness of the fatty points, their varying number in different cells in the same film, and the fact that they occur in abundance in cases where the condition of the patient excludes the possibility of so large an amount of fat being merely ingested from the blood by the circulating leucocytes, all point to this conclusion. Thus in the three cases of acute pneumonia the blood was taken, in one, on the sixth day, two hours after the crisis; in another on the fifth or sixth day, before the crisis; and in the third, five hours after the crisis. Furthermore, the fact that in such an acute disease fatty degeneration actually does occur in the renal epithelium and cardiac muscle proves the ability of the toxins to effect such damage also upon the circulating leucocytes.

That the degeneration of the leucocytes has occurred in the blood and not in the bone-marrow may be held as almost certain, since had so marked a change taken place whilst the cells were still in the marrow it is unlikely that they would have entered the vessels; they would have remained *in situ.* Upon the actual condition of the bone-marrow we have, with one exception, no observations.

When, as in myelæmia, the fat occurs in myelocytes in the blood, we should think, also, that the change occurred in the cells after they had reached the blood-stream.

The leucocytes most degenerated probably die, and might by their disintegration furnish a certain amount of free fat in the plasma.

Not that this is the sole source of the free fat in the blood which was present in some of the cases, for its amount is too great for such an explanation. Most of the free fat must be regarded as derived from the intestine, or as transferred from the common connective tissue to the blood plasma for the use of the more important organs. The fat in some of the leucocytes under these circumstances is doubtless ingested, but the fact that in some of the cases where the fat in the leucocytes was well pronounced no free fat was present in the plasma shows that this cannot be advanced as the sole explanation. The presence of fat in some of the myelocytes of the blood film in myelæmia, again, cannot be due to ingestion, since these cells possess no phagocytic powers. It might have been thought, *à priori*, that the presence of fat in the finely granular polymorphonuclear leucocytes would be a sign of grave significance, as indicating not only a high degree of toxæmia but an interference with the function of cells, the phagocytic integrity of which is of such importance in the cure of a disease like pneumonia. For the leucocytes so altered must have lost, for the time, their physiological capacities. They would be much in the same condition as the pus cells in an acute abscess rendered fatty by the toxic action of pyogenic micro-organisms. Indeed, a study of cover-glass films made from the pus of an acute abscess and treated precisely as those of blood, reveals the presence of scarlet points and droplets within a large number of the finely granular polymorphunclear leucocytes, which are exactly matched by those in the leucocytes of certain of the blood-films described. In some of the pus cells (as in the blood) the red points are quite minute (as they are in Case 5, influenzal pleurisy); in others larger (as in Case 24, acute pneumonia); or still more so, as they are in Case 55 (pyloric carcinoma associated with chlorotic anæmia).

It is noteworthy, too, that in the pus-cells so affected the nuclei may exhibit no fragmentation. Nor have we ever seen nuclear fragmentation in the fatty leucocytes in blood-films.

This prognostic conjecture, nevertheless, is not borne out by observation. Thus, in the three cases of acute pneumonia in which a certain number of the polymorphonuclear leucocytes

contained fat, recovery ensued. In one case the blood was examined on the sixth day, two hours after the crisis; in another on the fifth or sixth day, before the crisis; and in another, five hours after the crisis.

The actual number of leucocytes showing the fatty change in these three cases, however, was not excessive, and although the phagocytic power of such cells would doubtless be diminished or destroyed, the great excess of leucocytes present would compensate for such a loss. Within two or three days after the crisis the leucocytosis has disappeared; the leucocyte count is practically normal. This rapid disappearance of the leucocytic excess from the blood is largely due to the vast immigration of leucocytes into the infected organs, the lung more especially; the surplus yet remaining would disappear as having no further purpose to serve. For all observation goes to show that the rapid amelioration following the crisis is due to the activity of the finely granular leucocytes brought about by an increased opsonification. MacDonald[1] has shown that the "opsonic" index attains its maximum at the crisis. And Rosenow[2] concludes from his work, that pneumonic serum has no pneumococcidal effect: that the "opsonin," during and shortly after crisis (in cases that recover), seems to rise above the normal, and that the pneumococcidal action of pneumonic blood is the result of the combined action of serum and leucocytes—phagocytosis and intra-phagocytic digestion. It must not be forgotten, moreover, as a general consideration, that the degenerating cells in the blood may recover, like those, *e.g.* of the kidney in toxic diseases, in which the damage done to the renal epithelium is shown by the temporary presence of albumen and casts in the urine.

In all the cases we have examined, the fatty changes were confined to the finely granular polymorphonuclear leucocytes; that is, to the cells which take the active part in phagocytosis; the most active cells, as being the more highly differentiated, are those most affected by the toxin.

We have never seen any such change in the lymphocytes—a class of cell almost devoid of phagocytic power.

The inactivity of the lymphocytes is a striking comment upon

[1] 'Trans. Path. Soc. Lond.,' vol. lvii, p. 45, 1906.
Journal of Infectious Diseases,' vol. iii, Chicago, June 30th 1906.

the fanciful views once held, that the lymphatic tissue, whether of the tonsils, lymphatic glands, or intestinal track, constituted a highly important line of defence against microbial invasion. As a matter of observation, it is in the solitary and Peyerian glands of the intestine that tubercular infection takes place; and once a tubercular process has started in a member of a lymphatic chain it spreads from gland to gland until the whole are involved.

Anæmia.

In this group of diseases the following of the cases in which fat was found in the leucocytes may be placed:

(1) Chlorosis.

(2) Carcinoma of the pylorus, associated with anæmia of the chlorotic type.

In chlorosis the fatty changes occurring in the finely granular polymorphonuclear leucocytes are attributable to the deficient oxygen-carrying power of the blood. No direct observations upon the state of the organs appear to have been made in this disease, although it is commonly assumed that they are affected with fatty degeneration, the dilatation of the heart, observed clinically, being especially so explained. Observations upon the blood-forming organs are equally wanting.

In chlorosis the most marked change in the blood is the excess of water—hydræmic plethora.

The number of red cells in a given instance is diminished; the absolute number is increased. And similarly, whilst the percentange of hæmoglobin may be reduced to forty or even to thirty, the total hæmoglobin content remains normal and the oxygen *capacity* undiminished.

As the reduction in the oxygen-*carrying* power affects the tissues supplied by the blood, so may it affect the nutrition of the leucocytes in the blood itself.

In the particular case of chlorosis in which fat occurred in the leucocytes, the blood was taken at 2 o'clock p.m., the patient having had no food since breakfast.

The plasma, as studied in the blood-films, contained free fat, the presence of the latter, under the circumstances mentioned, being possibly due to its less ready manipulation in consequence of the excessive bulk of water in the blood.

The amount of fat in the finely granular leucocytes in this case is very striking; every cell holds a certain number of fine scarlet points or droplets, and many are loaded.

How much of the fat in the leucocytes is to be ascribed to ingestion, and how much to degeneration, it is impossible to say.

As in the case where œdema follows venous obstruction, the transudation occurs only after the stasis has led to damage of the endothelium, so in a somewhat similar way in the case of anæmia we should regard the deficient oxygenation as involving injury to the leucocytes; the intra-cellular fat appears in consequence.

In the case of pyloric carcinoma, there was an associated chlorotic anæmia arising from the ill-nourished condition of the body in general, including the blood-forming organs.

The fat droplets in the leucocytes, of which only a certain number were affected, were of conspicuous size, the change being a far advanced one. No free fat was present in the plasma.

And finally, in the case of diabetes with lipæmia, in which typhoid infection terminated life, the amount of free fat in the plasma makes it clear that much of the fat in the leucocytes must be abscribed to phagocytic ingestion, but how much to this and how much to the toxic condition of the blood cannot be stated.

The peritoneal fluid removed after death was full of droplets of fat.

The bone-marrow showed a highly abnormal number of large endothelial cells, holding an abundance of multiple fat droplets.

The gall-bladder contained no bile, and its contents were so white that they were at first thought to be purulent. Microscopic examination of the fluid revealed the presence of free fat and shed columnar cells.

In is interesting to note, in passing, that the bases of these cells were loaded with fat, which had evidently been ingested by them whilst *in situ*, as it is by those of the intestine. The absorptive capacity of the epithelium of the gall-bladder has been shown also by Aschoff.

The Presence of Granules in the Leucocytes which Stain of a Deep Brown Colour, Scharlach Granulation.

From the foregoing list of diseases in which fat was found in the finely granular polymorphonuclear leucocytes, some, in which a fatty degeneration might have been particularly anticipated, are conspicuous by their absence. Two such would certainly be diphtheria and pernicious anæmia.

In both these diseases, however, we have found the leucocytes laden with fine granules, which, though deeply stained, do not exhibit the transparency and proper red colour of ordinary fat. We may first give a list of the cases in which these deep brown granules occurred. The phenomenon itself we may call for convenience, *Scharlach granulation.*

Subphrenic abscess.
Exophthalmic goitre.
Pneumonia with empyema.
Pernicious anæmia.
Diphtheria (6 cases).
Appendicitis.
Pericarditis, rheumatic.
Acute meningitis.

The following is a more detailed list of the particular cases from which the preceding list is compiled.

The numbers affixed to the cases are those given to them as they appeared in the full list of the whole seventy-seven.

Case 7.—Subphrenic Abscess.

All the finely granular polymorphonuclear leucocytes hold larger numbers of deeply stained points.

Case 8.—Exophthalmic Goitre.

All the finely granular leucocytes contain numerous granules of the dark kind.

Case 10.—Pneumonia and Empyema.

Some of the finely granular leucocytes hold dark granules in fair numbers.

Case 11.—Pernicious Anæmia.

All the finely granular leucocytes are laden with dark reddish granules.

CASE 13.—DIPHTHERIA.

Child; fifth day of the disease.

Many of the finely granular leucocytes hold deep red, coppery granules.

CASE 14.—DIPHTHERIA.

Child; seventh day of the disease.

Some of the finely granular leucocytes hold deep red, coppery granules.

In a very few, sparse, transparent, larger, red-stained droplets of fat occur in addition to the other granules.

CASE 15.—DIPHTHERIA.

Child; seventh day of the disease.

All the finely granular cells hold points of deep reddish colour; in some they are only few.

CASE 16.—DIPHTHERIA.

Child; sixth day of the disease.

The finely granular leucocytes hold deep brownish-red points.

CASE 17.—DIPHTHERIA.

Child; thirty-second day of the disease.

Most of the finely granular leucocytes hold dark reddish granules; in some, these are very few.

CASE 18.—DIPHTHERIA.

Child; sixty-fourth day of the disease.

Most of the finely granular leucocytes hold fine, deep copper-coloured points.

CASE 21.—APPENDICITIS (NOT ACUTE).

Some of the finely granular leucocytes contain a certain number of fine, dark reddish granules.

CASE 36.—PERICARDITIS (RHEUMATIC).

Many of the finely granular leucocytes hold deep reddish points.

CASE 37.—ACUTE MENINGITIS.

The finely granular leucocytes hold many deep reddish points.

CASE 71.—PNEUMONIA.

Most of the finely granular leucocytes hold coppery points.

In discussing the nature of these granules various possibilities require consideration.

That the granulation is not a mere precipitate of Scharlach within the cytoplasm of cells that have been imperfectly fixed, is shown by the fact that the diphtheria blood-films (in which, amongst others, it occurred) were fixed in formol vapour for over twenty-four hours.

It is noteworthy that the normal granules of the eosinophil leucocytes exhibit a somewhat similar coloration, though of a less intense degree.

Against the identity of the granulation with the substance composing the eosinophil grains, however, must be placed the circumstance that the latter are equally well coloured in both pathological and normal blood-films after the films have been treated with absolute alcohol; the fine granules under discussion, on the contrary, are not demonstrated by means of Scharlach if the films are first treated with absolute alcohol.[1]

The degree of Scharlach granulation, moveover, present in some cases (every finely granular leucocyte being laden) excludes, we think, the explanation that the granules in question are eosinophilic which have been discharged from coarsely granular cells, disintegrated, and subsequently ingested by the finely granular leucocytes.

In this connection it may be further mentioned that no eosinophilia has been present in any of the cases as a possible source of such an excessive amount of Scharlach-staining substance.

The Scharlach granulation is not due to the coloration of the proper granules of the cell, for in some of the leucocytes comparatively few granules occur, and in these cells the proper granules are recognisable though unstained.

The granulation is not unlike the glycogenic, as displayed in the leucocytes after treatment of blood-films with iodine solution.

[1] Like the acid-fast waxy substance of the tubercle bacillus, the granules of the eosinophil leucocytes retain a bright red colour in blood-films treated with hot dilute carbol fuchsin for five minutes followed by 5 per cent. hydric nitrate. When the tubercle bacillus, however, is submitted to the action of 75 per cent. alcoholic solution of Scharlach for twenty-four hours in the cold, it remains uncoloured and so differs from the eosinophil granules, which are dyed of a russet brown by this solution.

In most cases the iodine reaction presents itself as a diffuse, brown coloration of the cytoplasm of the finely granular polymorphonuclear leucocytes, but it may take the form of a fine stippling. A still further likeness is to be found in the occasional presence of similar iodophilic granules in the plasma, for fine extra-cellular granules may occur also in the Scharlach preparations.

Although the iodophilic reaction may be seen in normal blood, in pronounced degree it occurs only under pathological conditions, and most observers are agreed in viewing it as evidence of cell degeneration, brought about in most cases by a toxic cause.

We exclude this explanation, however, for the reason that the Scharlach granulation is not to be observed in control cover-glass films if treated with absolute alcohol before they are transferred to the dye. The glycogenic reaction, on the contrary, is as readily obtained after this treatment as without it.[1]

We have, moreover, found that glycogen is uncoloured by Scharlach. If fat-free glycogen (from the rabbit's liver) is dissolved in distilled water and precipitated by alcohol, the wet sediment, when treated with Scharlach for forty-eight hours and examined microscopically, is seen to consist of fine spherical granules which are quite untouched by the dye. The same sediment stains of a mahogany brown when submitted (after drying on an albuminised cover-glass) to the action of iodine vapour for twenty minutes, and afterwards mounted in Ehrlich's iodine medium.

The absence of the Scharlach granulation when the blood-films have first been treated with absolute alcohol excludes the possibility of the granules being blood-pigment which has been ingested by the leucocytes.

We have found the Scharlach granulation in some of the finely granular polymorphonuclear leucocytes in cover-glass films made from the splenic pulp in a case of acute peritonitis, the films having been fixed in formol and treated precisely like those of the blood. In this observation, also, the exclusion of blood-pigment is brought out by the fact that the deep brown

[1] J. Barnicott, "The Iodine Reaction in the Leucocytes," 'Journal of Pathology,' vol. xi, 1906, p. 304.

granules are not to be seen in the films stained by Leishman's method.

Does the Scharlach granulation represent a substance in which fat is not free but combined? Is it allied to lecithin or myelin, both of which are known to occur in many kinds of cell?

Lecithin obtained from egg-yolk is not coloured with Scharlach.[1]

In sections of an enlarged prostate which we have examined, although the presence of fat was demonstrated by means of Scharlach in some of the epithelial cells, the free granules in the acini (generally held to be lecithin) were quite uncoloured.

By the same want of colourability, after treatment with formol, myelin may be excluded. In medullated nerve fixed in formol and afterwards teased and immersed in Scharlach solution for twenty-four hours, the myelin of the individual fibres exhibits practically no coloration; it is equally unaffected by osmic acid if the nerve is first fixed in formol.

As regards the coloration of human fats, that is, of their fatty acids, which are the proper colourable substances, pure oleic acid is stained of the typical red colour with 75 per cent. alcoholic solution of Scharlach. From human liver Leathes has extracted another fatty acid, the colourability of which we have been able to test upon cover-glass smears.

The smear, after being treated with formol vapour, stained with Scharlach, and finally washed in distilled water and mounted in Farrant's medium, is transparent, and of an orange or orange-brown colour; it presents nothing suggestive of the Scharlach granulation.

From human heart-muscle Leathes has also extracted a fatty acid other than oleic, and not identical with that from the liver. The fact, however, that in fatty degeneration of this muscle, as studied in diphtheria, the fat that appears free in the fibre is, from its first appearance, stained of a brilliant red by Scharlach, shows that whatever fat besides olein may be present, it is not the substance constituting the Scharlach granulation.

There is, to conclude, the possibility that the granulation is due to a soap, the colloidal nature of which prevents its diffusion into the substance of the cell.

Various fermentative capabilities have been ascribed to the

T. R. Elliott and I. Tuckett, 'Journ. of Physiol.,' vol. xxxiv, p. 350.

leucocytes. They are certainly proteolytic, and both amylolytic and lipolytic powers have been attributed to them.

It is conceivable that the fat droplets on their first appearance in the leucocytes might be split, with the resulting formation of an intra-cellular soap arising from the combination of fatty acid with calcium, sodium, or potassium.

Using pure oleate of calcium (the only soap of the three not soluble in water) we find that cover-glass smears, after being treated as the blood-films, fail to exhibit the dark-brown colour and opacity of the Scharlach granulation; the particles take a pale brown or orange tint. This soap, moreover, is insoluble in alcohol.

The pigment granules of nerve-cells are held to contain lecithin or an allied fat-like substance.

We do not find, however, that the pigment of the cells in the locus niger of the human brain takes any colour when treated with Scharlach; the granules remain of a rich chestnut-brown, and, moreover, display none of the opacity of the Scharlach granulation.[1]

The observations of Lorrain Smith,[2] which show that neutral fats (like olein) may, by the action of acids, be hydrolysed and converted into fatty acids and glycerine, and upon this, stain with basic dyes which fail to colour the neutral body, have no bearing on the present question; Scharlach stains the neutral fat and the fatty acid indifferently.

For the present, therefore, we are forced to leave the nature of the Scharlach granulation undetermined. Nevertheless, its appearance in diseases in which a fatty degeneration of the leucocytes might have been expected, and the fact that in some cases of acute pneumonia the proper Scharlach fat-reaction of the points in the cells is obtained, whilst in others it is the brown, opaque Scharlach granulation which appears, make us conclude that the granulation is indicative of a degeneration, and seeing that it is not obtainable after the treatment of the blood-films with absolute alcohol, we conclude that it is allied to that known as fatty.

[1] In sections of the locus niger stained by Busch's modification of the Marchi method, these pigment granules acquire a blackish-brown colour, but not the full black which fat droplets exhibit in degenerated cells when stained by the same method.

[2] 'Medical Chronicle,' 1906, p. 277.

EXPLANATION OF PLATE VIII,

Illustrating the paper on "Fatty Degeneration of the Blood," by S. G. Shattock and L. S. Dudgeon. (P. 227.)

FIG. 1.—Two finely granular polymorphonuclear leucocytes from the blood-film of a patient suffering from toxæmia of pregnancy. The patient made a complete recovery after the induction of labour.

The cells contain many red points of fat. Free fat is shown, also, in the plasma.

All the preparations were made by fixing the blood-films in formol vapour in a closed vessel, so as to prevent drying; and afterwards staining in 75 per cent. alcoholic solution of Scharlach. The nuclear stain afterwards used was hæmalum. In all cases the red points in the cytoplasm represent fat.

FIG. 2.—Two polymorphonuclear leucocytes from the blood-film of a patient suffering from eosinophilic pleurisy, possibly influenzal.

FIG. 3.—A polymorphonuclear leucocyte in a blood-film from a case of myelæmia. There was severe anæmia. Death ensued shortly after the preparation was made.

FIG. 4.—Two polymorphonuclear leucocytes in a blood-film from a case of acute pneumonia. The patient recovered.

FIG. 5.—A polymorphonuclear leucocyte in a blood-film from a patient suffering from diabetes and lipæmia. The plasma contains numerous points of fat.

FIG. 6.—Two polymorphonuclear leucocytes in the blood-film from a patient suffering from marked chlorosis.

FIG. 7.—A polymorphonuclear leucocyte in a blood-film from a patient suffering from carcinoma of the pylorus, and who was very emaciated and anæmic, the anæmia being of the chlorotic type. The fat droplets are of conspicuous size.

FIG. 8.—Two polymorphonuclear leucocytes in a blood-film from a patient suffering from pernicious anæmia.

In this case the cells are loaded with fine points, which differ in their microphysical characters from fat in that they are wanting in transparency, and are of a deep chocolate-brown colour. Similar appearances, named for convenience "Scharlach granulation," were found in a series of cases of diphtheria. The circumstance that in control preparations, treated with absolute alcohol before being placed in Scharlach, these points do not appear, indicates that they are akin to fat.

FIG. 9.—Two leucocytes in a blood-film from a patient suffering from acute pneumonia.

In the finely granular cell the points present the opacity and deep-brown colouration referred to under Fig. 8. The other cell is a coarsely granular or eosinophile leucocyte. The normal eosinophile granules are stained of a pale chocolate-brown; this is the usual colouration taken after treatment with Scharlach, and it is unaffected by previous treatment of the film with absolute alcohol: this colouration obtains equally in normal and pathological blood.

All the figures are drawn under Zeiss $\frac{1}{12}$, Oc. 8.

TABULA VIII,

Ad dissertationem "De Sanguinis Degeneratione Adiposâ," illustrandam.

S. G. Shattock, L. S. Dudgeon. (P. 227.)

FIGURA 1.—Duo leucocyti polymorphonucleati in mulieris sanguine ex toxæmiâ graviditatis ægrotæ. Plurima puncta continent quæ cum liquore Scharlach (75 per cent. alc.) tincta sunt. Convaluit æger.

FIGURA 2.—Duo leucocyti polymorphonucleati in mulieris sanguine ex pleuritide ægrotæ; multa puncta adiposa continent.

FIGURA 3.—Leucocytus polymorphonucleatus in hominis sanguine ex myelæmiâ ægroti. Mortuus est æger.

FIGURA 4.—Duo leucocyti polymorphonucleati in hominis sanguine ex pneumoniâ acutâ ægroti. Convoluit æger.

FIGURA 5.—Leucocytus polymorphonucleatus in hominis sanguine ex diabete cum lipæmiâ ægroti. Sanguinis plasma quoque puncta adiposa continet.

FIGURA 6.—Duo leucocyti polymorphonucleati in mulieris sanguine ex chlorose insigni ægrotæ.

FIGURA 7.—Leucocytus polymorphonucleatus in hominis sanguine ex pylori carcinomate ægroti. Puncta adiposa in cytoplasmate magnitudinis insignis sunt.

FIGURA 8.—Duo leucocyti in mulieris sanguine ex anæmiâ perniciosâ ægrotæ. In cytoplasmate continentur puncta insigniter tincta, magis fusca, autem, quam rubra ac sine pelluciditate guttularum adiposarum propriâ. Hæc, tamen, degenerationem indicare, opinamur, haud illi dissimilem quæ adiposa habetur, quod sanguine prius in alcohol absoluto quam in liquore Scharlach immerso, puncta non discerni possunt.

FIGURA 9.—Duo leucocyti in hominis sanguine ex pneumoniâ acutâ ægroti. Ex his in uno continentur puncta ut in figurâ præcedenti. Leucocyto in altero fusca tincta sunt granula eosinophila normalia. In sanguine et normali et abnormali, etsi sanguis in alcohol ethylico antequam in liquore Scharlach immergitur, hæc granula similiter colorantur.

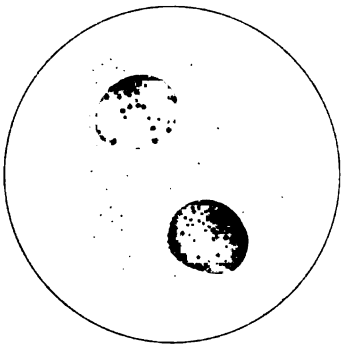

Fig 1

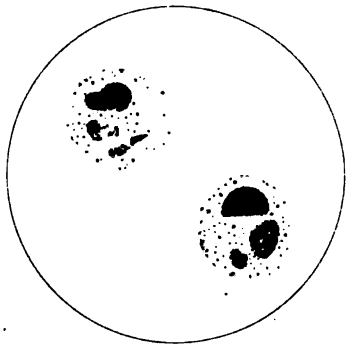

Fig 2

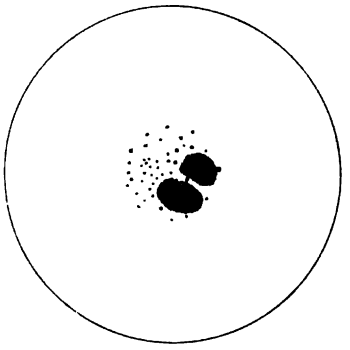

Fig 3.



Fig 4

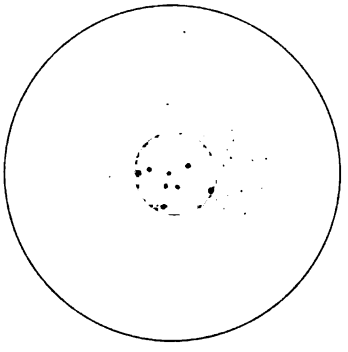

Fig 5

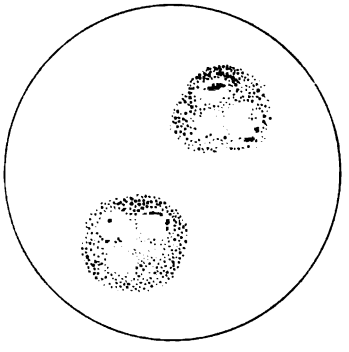

Fig 6

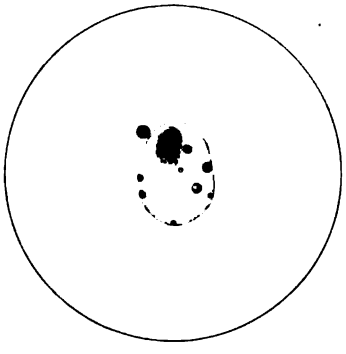

Fig. 7

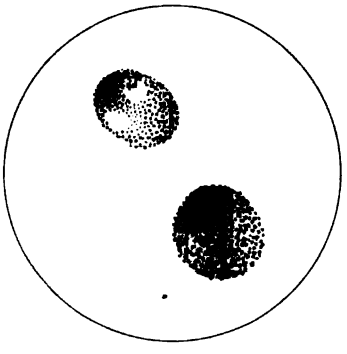

Fig 8



Fig 9

Lith. Anst. v. A. Funke Leipzig

In conclusion, we desire to express our thanks to Dr. G. Buckmaster and to Dr. J. B. Leathes for criticism and help in regard to certain of the points raised by the investigation.

May 21*st*, 1907.

---

21. *On cystinuria with diamenes.*

By F. H. Thiele.

In view of the great interest attaching to this condition from a physiological point I desire to place on record the results of my investigations on two cases in which this anomaly occurred.

The first was a case of a young man, aged 28 years, in whom the condition was accidentally discovered. He had to undergo an operation which involved prolonged rest in bed and so I was able to study the anomaly from several points of view.

I determined to investigate the effects of:—

(1) 24 hours' practical starvation.

(2) The administration of an almost completely carbohydrate diet.

(3) An excessive meat diet.

(4) The administration of 5 grammes of tyrosin.

(5) The administration of 4·6 grammes of the patient's own cystin.

The urine as ordinarily passed was of a clear yellow colour and had a large deposit of cystin crystals with some oxalates. The results of analysis of a 24 hours' specimen were as follows:

Amount	1150 c.c.
Total nitrogen	13·6 grammes.
Uric acid	0·78 „
Total sulphates as SO_3	1·3 „
Total sulphur less cystin	1·68 „
Aromatic sulphates	0·163 „
Cystin	0·532 „
Neutral sulphur less cystin	0·38 „

22·6 per cent. of total. S.

The urine did not give a red colour with Millon's reagent.

It was also tested by the method of Abderhalden and Schittenhelm (1). The urine was filtered free from its precipitate of cystin and a measured quantity was taken, strongly acidified

with glacial acetic acid, and evaporated under diminished pressure at 48° C. There was then a further precipitate of cystin which was removed. The urine was still further evaporated till no more precipitate occurred on cooling. The resulting precipitates were added together, dissolved in warm 10 per cent. AMHO and cooled. No precipitate occurred from this. The ammoniacal solution was then treated drop by drop with glacial acetic acid till the reaction was just short of neutral. The solution was then cooled. No precipitate occurred. Excess of glacial acetic acid was then added and the cystin precipitated. This precipitate was collected, dried and weighed. The spontaneously precipitated cystin was also purified, dried and weighed; from these results the total amount of cystin was determined. The whole of the cystin was thus removed from the urine, and if any tyrosin had been present it would have been detected as well by this method. The presence of other amido acids could not be accurately determined since the solubilities of the β-naphthalin sulphochloride compounds of the various amido acids have not been sufficiently determined to allow of their separation from one another. The solubilities of the leucin compound, however, appeared to be so definite that the reaction was tried, to see if any of this substance could be separated from the diamino compound. For this purpose the urine was taken after the removal of the cystin as mentioned above, made alkaline with N. caustic soda and shaken with an ethereal solution of β-naphthalin sulpho-chloride after the method of Abderhalden and Schittenhelm.

After the removal of the ethereal solution the urine was treated with 5/N. solution of HCl, the precipitate collected and treated with a small amount of cold absolute alcohol, which, on evaporation, was found to have extracted nothing from the precipitate, thus pointing to the absence of leucin since the β-naphthalin sulpho-chloride compound of this is easily soluble in cold absolute alcohol. The corresponding compound of the diamenes is apparently not soluble in cold alcohol.

The total sulphur and sulphates were estimated in some of the urine from which the cystin had been removed.

By these methods the total cystin, sulphur and sulphates, and the presence of mono-amido acids were determined. On applying Salkowski's test for thio-sulphates to the original urine they were found to be present in quantity. Some of the

original urine was then treated by the benzoylation method for diamenes. A copious precipitate occurred, which, after purification, proved to be benzoyl cadaverin. This was dissolved in a small amount of warm alcohol and was not precipitated when added to a large amount of ether. The melting point of these crystals was about 130° C., and ·1 gramme contained ·00895 grammes of N. estimated as ammonia, giving a percentage of 8·95 of N., the calculated percentage being 9·03. The unprecipitated benzoyl cadaverin in the urine was also separated and added to the other. From these results the total amount was estimated after drying and calculated to be 0·968 grammes for the 24 hours. A specimen of fæces was also treated after the method of Baumann and Udranzsky (3). A benzoyl compound was obtained which, after having been dissolved in a little warm alcohol, was found to be in greater part precipitated by an excess of ether, only a small part remaining in solution. The precipitated part was therefore benzoyl putrescin. Its melting point was 174° C., and it was found to yield 9·24 per cent. of N., the calculated percentage being 9·24. The soluble part was benzoyl cadaverin, but it was only very small in amount. The quantity of benzoyl putrescin was 0·54 grammes.

The examination of urine therefore brought out the following features:

(1) The presence of cystin.

(2) The absence of tyrosin and other mono-amido acids.

(3) The excess of neutral sulphur, this, in addition to the cystin, forming 22·6 per cent. of the total sulphur.

(4) The presence of cadaverin in the urine and putrescin in the fæces.

(1) *Effect of virtual starvation.*—The patient having to undergo an operation no food was taken for over 24 hours. The urine was collected on the day of operation from 8 a.m. to 8 a.m. on the following day. The patient had taken no food since midnight of the day of operation. Chloroform was administered.

The results of the analysis of the urine were as follows:

Quantity passed . . .	800 c.c
Total nitrogen . . .	5·152 grammes.
Uric acid . . .	0·4 „
Total sulphates as SO_3 . .	0·31704 „

Total sulphur, less cystin . .	0·6775 grammes.
Neutral „ „ . .	0·35946 „
Cystin	0·486 „
Benzoyl cadaverin . . .	0·318 „

From these results it will be seen that in spite of the practical abstinence from food there was scarcely any alteration in the amount of cystin passed, but a marked reduction in the amount of cadaverin.

(2) *Effect of an almost pure carbohydrate diet.*—On another occasion the patient was given a diet consisting of bread, butter, rice, fruit, tea, one pint of milk, and no meat. The urine was collected after the passage of the morning urine on the day of the experiment, for the next twenty-four hours.

The results of the analysis of the urine were as follows:

Quantity	1550 c.c.
Total nitrogen . . .	9·114 grammes.
„ uric acid . . .	0·412 „
„ sulphates as SO_3 . .	0·8235 „
„ sulphur less cystin . .	1·1626 „
„ neutral sulphur less cystin .	0·3391 „
„ cystin	0·57 „
„ benzoyl cadaverin . .	0·366 „

No other amido acids were discovered.

It would thus appear that a preponderatingly carbohydrate diet has very little effect on the cystin excretion, but that the diamene excretion is diminished about 60 per cent. This is in accord with the observations of Leo and Garcia.

(3) *The effect of an excessive meat diet.*—The patient was given 1lb. of meat in addition to his usual food.

The urine was collected in the way mentioned above.

The results of analysis were as follows:

Quantity	1625 c.c.
Total nitrogen . . .	17·29 grammes.
„ uric acid . . .	1·16 „
„ sulphates as SO_3 . .	2·04 „
„ sulphur less cystin . .	2·4681 „
„ neutral sulphur less cystin.	0·4281 „
„ cystin . . .	0·514 „
„ benzoyl cadaverin . .	1·108 „

No other amido acids were discovered.

There was thus practically no alteration in the amount of cystin passed.

The total amount of sulphur was increased. The diamenes were a little increased.

(4) *The effect of the administration of tyrosin.*—The patient was given 5 grammes of tyrosin with his food. The tyrosin was optically active.

There was no trace of tyrosin to be detected in the urine.

The benzoyl compound obtained from the urine on benzoylation appeared to be only benzoyl cadaverin; the substance described by Garrod and Hurtley (4) did not seem to be present.

Effect of the administration of cystin.—In addition to the ordinary diet 4·6 grammes of the patient's own cystin were administered. In order to obtain this amount the urine was collected for a prolonged period and treated with glacial acetic acid and a little chloroform. The urine was kept in the cold and the resulting precipitates of cystin collected. These were subsequently purified by dissolving in AMHO and re-precipitating with glacial acetic acid. In order to accurately investigate the urine for the purpose of this experiment it was collected for three days: (1) for the 24 hours before the administration of the cystin; (2 and 3) for the two successive 24 hours following. The cystin was estimated by Abderhalden's method (1). The spontaneously precipitated cystin was collected on a filter and dissolved in ammonia, the solution was added to the urine, and the whole was accurately measured. A definite quantity was taken and treated by this process. The β-naphthalin sulpho-chloride process could not be used for this purpose because there is as yet no method of separating the β-naphthalin sulpho-cystin from the similar diamido compounds. The urine was also treated by this method and the resulting precipitate treated with a large quantity of hot absolute alcohol and allowed to cool, when a crystalline material separated out, which was in excess of the amount of cystin calculated by the other method. However, the amount did not in the least approach the quantity of cystin administered, so that the results obtained by this method are really confirmatory of the other one.

The results of the analyses are :

	Twenty-four hours proceding administration.	First twenty-four hours after administration.	Second twenty-four hours.
Amount	1400 c.c.	1450 c.c.	1400 c.c.
Total nitrogen	12·48	12·612	11·987
„ sulphur	1·9686	4·3217	1·9818
„ sulphates	1·6317	3·15274	1·6502
„ neutral sulphur less cystin	0·337	1·1634	0·2696
„ cystin	0·577	0·604	0·561

From these results it will be seen that the cystin was not passed as such in this case, but it was rapidly excreted as sulphates and other less oxidised sulphur compounds, and by Salkowski's method there appeared to be a large amount of thiosulphates.

The following are the important features of this case :

(1) The absence of other amido acids besides the cystin.

(2) The presence of cadaverin in the urine, and of putrescin in the fæces.

(3) The non-appearance of tyrosin when administered by the mouth.

(4) The complete destruction of cystin obtained from the patient when given by the mouth.

(5) The small influence of diet on the cystin excretion by the greater on the diamenes.

The most interesting feature of this case is the fact that the patient was able to destroy his own cystin when it was given by the mouth after it had been purified. Hexagonal cystin obtained from proteid was not added to the ordinary output when similarly administered in the case investigated by Alsberg and Folin (5), but in that of Loewy and Neuberg (6) ordinary protein cystin given by the mouth was added to the usual urinary output and very little destroyed, but when cystin from a cystin calculus was administered it was broken up and converted into sulphuric acid and less completely oxidised sulphur compounds. These observers held that the difference was due to the two cystins being different bodies; that the hexagonal cystin obtained from proteid, the protein cystin, was an α-amido-β-thio compound, and that the calculous cystin was a β-amino-α-thio body. They also

found that their patient when given tyrosin or asparaginic acid by the mouth excreted almost the whole amount in the urine. These being also α-amino acids they concluded that their cystinuric patient was unable to deal with α-amido acids of which protein cystin is one, but could act upon β-amino acids. They held that these results confirmed their views of the constitution of the cystins, which resulted from their chemical investigations, in which they showed that whilst they agreed with Friedmann (7) that protein cystin is α-amino-β-thio propionic acid, the calculous cystin is an isomer of the constitution β-amino-α-thio propionic acid. Later researches by Emil Fischer and Suzaki (8) however tend to show that the two cystins are not really different, but that the apparent differences can be explained by the presence of impurities in the calculus, since they were able to show that some calculi obtained from the same source as Loewy and Neuberg's contained tyrosin.

Cystinuric patients also differ very much as regards the presence of other amido acids. In this case no other mono-amido acids were found in the urine. Tyrosin with or without leucin was present in the cases recorded by Piccini and Conti (9), Moreigne (10), Percival (11) and in the case of Abderhalden and Schittenhelm (12). In the cases examined by Alsberg and Folin (5), C. E. Simon (13) and Garrod and Hurtley (4) the urine contained no other mono-amido acids even after administration by the mouth. Garrod and Hurtley (4), however, found in their case on several occasions a substance which yielded on benzoylation of the urine a crystalline body, the melting point of which was 205° C., and after the administration of tyrosin another substance occurred which on benzoylation gave rise to a crystalline compound which melted at 253° C. and was not therefore the di-benzoyl tyrosinamide of Orton (15). Bödtker (14) also obtained in his case on the benzoylation of the urine a benzoyl compound which melted at 203° C.

It was not possible to make any observations in the case here recorded on the behaviour of the diamido acids when administered by the mouth. The old view that the presence of diamenes in the excreta is due to a peculiar form of bacterial decomposition has now been shown to be erroneous since Moreigne (10) and C. E. Simon (13) independently have shown that their presence is perfectly parallel with the occurrence of

the mono-amido acids in the urine and is similarly due to the same arrested metabolism only affecting the diamido acids.

The administration of arginin in the case of Neuberg and Loewy (6) gave rise to the appearance in the urine of putrescin, and of lysin to cadaverin, the urine previously containing no diamenes.

The only difference between the mono and diamido bodies in these cases is that the former may be excreted unchanged whereas the latter undergo slight change.

Thus lysin loses CO_2 and becomes cadaverin.

Lysin, $CH_2.NH_2.(CH_2)_3.CH.NH_2COOH$.

Cadaverin, $CH_2.NH_2(CH_2)_3.CH_2NH_2$.

Arginin loses CO_2 and cyanimide.

Arginin, $C(NH).NH.CH_2(CH_2)_2.CH.NH_2COOH$.

$NH_2CN.CO_2.NH_2CH_2(CH_2)_2.CH_2NH_2$.

Tetramethylene diamene.

Experimentally this result has only been obtained in the case of Neuberg and Loewy (6), but not in Garrod and Hurtley's (4).

It would thus appear that the only feature that cystinuric cases have in common is the presence of cystin, and that they differ widely in their behaviour to other amido acids, both when given as such or as natural proteid. It is, therefore, probable that other cases of disordered proteid metabolism may occur in which the cystin-yielding fraction may be normally broken up, and so nothing will be present in the urine to attract attention unless the urine be systematically investigated.

The investigation of this case also affords an opportunity of tracing the fate of proteids in the body. Physiologists are growingly of the opinion that the intestinal mucosa has ferments which dentrify the amido acids, and that these are absorbed as fatty acids and ammonia. In this case it would appear that all the cystin occurring in the urine was derived from tissue catabolism, since starvation, diet, and the administration of cystin by the mouth did not increase the output. The starvation experiment shows that the tissues of the patient were deficient in a ferment which normally removes the sulphur part from the thio-amido compound, and the diet experiments seem to show that the thio-amido compounds cannot be, to any great extent, absorbed as such, since having evidence of the deficiency of the tissues in the sulphur-removing ferment, variations in diet

should be followed by direct variations in the cystin excretion, especially when pure cystin is administered. All the experiments on cystinuric patients with the exception of that of Loewy and Neuberger (6) appear to lead to the same conclusion. If the thio-amido acids were absorbed as such then the deficiency of the sulphur-removing ferment in the tissues should allow of the greater part of these bodies to escape unchanged in the urine.

I also had the opportunity of examing another case of cystinuria in which there were no other mono-amido acids present, but the urine also contained some cadaverin. A specimen of fæces could not be obtained for examination.

In conclusion I desire to thank Mr. Godlee and Dr. Kean for allowing me to investigate their cases.

REFERENCES.

1. *Abderhalden and Schittenhelm.*—'Zeits. f. Phys. Chemie,' Bd. 45, p. 468, 1905.
2. *Abderhalden and Schittenhelm.*—'Berichte der Deutschen Chem. Gesell.,' 1902.
3. *Baumann and Udranzsky.*—'Zeits. f. Phys. Chemie,' Bd. 13, p. 562, 1889.
4. *Garrod and Hurtley.*—'Journ. of Physiol.,' vol. xxxiv, p. 21, 1906.
5. *Alsberg and Folin.*—'Amer. Journ. Physiol.,' vol. xiv, p. 54, 1905.
6. *Neuberg and Loewy.*—'Zeits. f. Phys. Chemie,' Bd. 43, p. 338, 1904.
7. *Friedmann.*—'Chemisches Centralblatt,' Bd. 2, p. 300, 1902.
8. *Emil Fischer and Susaki.*—'Zeits. f. Phys. Chemie,' Bd. 45, p. 405, 1905.
9. *Piccini and Conti.*—'Lo Sperimentale,' vol. xl, p. 350, 1891.
10. *Moreigne.*—'Arch. de Med. Exped. and d'Anat. Path.,' vol. ii, p. 254, 1889.
11. *Percival.*—'Arch. Ital. de Clin. Med.,' vol. xli, p. 50, 1902.
12. *Abderhalden and Schittenhelm.*—'Zeits. f. Phys. Chemie,' Bd. 45, p. 468, 1905.
13. *C. E. Simon.*—'Amer. Journ. Med. Sci.,' vol. cxix, p. 50, 1900.
14. *Bödtker.*—'Zeits. f. Phys. Chemie,' vol. xlv, 1905.

---

22. *A case of typhoid fever diagnosed on the eighth day by blood culture in the absence of the agglutination reaction.*

By T. J. HORDER.

RECENT observations made upon patients suffering from typhoid fever have shown that the typhoid bacillus can be cultivated from the blood in a very considerable proportion of cases of the disease.[1] A single case of successful blood culture

[1] In nearly 90 per cent. during the first week according to Abel, 'Bacter. Taschenbuch,' Auf. 10, 1906, p. 75.

would not, therefore, seem to deserve the notice of this Society were it not that the present instance possesses some points of special interest.

The patient was a young man, aged 27 years. He was taken ill on November 26th. Seen in consultation on December 3rd, the eighth day of his illness, the chief clinical features were high continued fever (103°–104° F.), headache, marked delirium, and slight general bronchitis. The presence of a urethral discharge had suggested the possible existence of gonococcal blood infection. There was, however, no arthritis, and no evidence of endocarditis. A series of investigations yielded the following results: (1) Films made from the urethral pus showed the presence of a few gonococci. (2) A leucocyte count showed the presence of a leucopenia, the white cells numbering 1400 only. (3) A blood-culture was undertaken, the technique consisting of the withdrawal of 5 c.c. of blood from a vein in the forearm and the inoculation of four broth tubes and two sloped agar tubes. (4) The marked leucopenia suggested that the disease might be typhoid fever; Widal's test was therefore performed, with the result that a 1 in 20 dilution of the blood gave a few clumps at the end of an hour; a 1 in 40 dilution gave no clumps at the end of an hour. With the possibility of typhoid fever still in mind, however, the contents of two of the blood broth tubes were added each to 50 c.c. of broth, it being usually held that considerable dilution of the blood is necessary to obtain growth of the typhoid bacillus. All the tubes were then incubated at 37° C. In twenty-four hours there was no visible growth in any of the tubes, but in forty-eight hours a fluffy growth appeared in the blood clot of the two broth tubes which had not been specially diluted, the broth outside the clot remaining clear. It was not possible to count the colonies, but they were very numerous. The two large tubes, containing the blood much diluted, showed uniform turbidity. In the blood-agar tubes growth had also appeared at the bottom of the slopes. On examination all the tubes yielded a motile, Gram-negative bacillus morphologically resembling *B. typhosus*. The serum from each of two patients convalescing from undoubted typhoid fever clumped this bacillus rapidly and completely with a dilution of 1 in 80. The nature of the disease was therefore reported to be typhoid fever. Classical reactions were given by

the organism in the course of the next few days in milk, neutral red broth, shake glucose gelatin, lactose litmus broth and McConkey's medium.

The patient developed rose-spots eight days after the blood-culture had been performed.

The points of interest in this case are: (1) the early diagnosis of the disease by means of blood-culture; (2) the demonstration of the bacilli in the blood before the appearance of the agglutination reaction; (3) the co-existence of a marked leucopenia with a large number of bacilli in the systemic blood stream; and (4) the facility with which the organism grew without having resource to high dilution by the medium, or to the addition of such substances as ox-bile, etc. This last observation raises the question whether any such special precautions are really necessary in order to cultivate the bacillus from the blood in typhoid fever. But it may be that in this particular case the bactericidal power of the blood for *B. typhosus* was exceptionally low; the number of bacilli per cm. of the patient's blood was certainly very large. It was chiefly owing to this last-mentioned fact that a bad prognosis was given in the case; and this was justified, for the patient died of heart failure on the eighteenth day of his disease.

January 15th, 1907.

---

23. *A third case of influenzal endocarditis diagnosed by blood culture.*

By T. J. Horder.

Nine months ago I read a paper before this Society, in which were described two cases of endocarditis, due to Pfeiffer's *B. influenzæ.*[1] A pure culture of the bacillus was obtained from the blood of each patient on more than one occasion, and in both cases *post-mortem* observations confirmed the existence of this organism in the heart valves, other organisms being absent. I suggested at the time that the occurrence of Pfeiffer's bacillus as a cause of ulcerative endocarditis was probably not rare. I am able to-night to report a third case of endocarditis in which a pure culture of *B. influenzæ* was isolated from the blood during life.

[1] Trans. Path. Soc. Lond., 1906, p. 58.

The patient was a postman, aged 50 years, admitted to St. Bartholomew's Hospital under the care of Dr. Samuel West, by whose kind permission I am able to refer to the case. He had had rheumatic fever when twenty-three. The onset of his fatal illness was insidious, and it is probable that its duration was at least four months. The clinical picture was that of a case of chronic ulcerative endocarditis; there was nothing to suggest the nature of the causal organism. The technique of the blood-culture was that described in the communication already referred to. In each of the blood broth tubes, as well as upon the agar slopes, minute colonies appeared in twenty-four hours, easily counted in forty-eight hours. It was estimated that not fewer than fifty colonies were present in each cubic centimetre of blood examined. The organism showed several of the features noted in the previous paper. Thus, the individual members of the culture in the original tubes were highly coccoid in form, and when seen as definite short bacilli they presented a bipolar appearance. Casual observation might have passed the film as being that from a culture of a short streptococcus. Again, second and third subcultures of the organism were obtained without the addition of blood, and the colonies in the first subculture on agar were large and opaque. Later subcultures, however, gave the characteristic dew-drop colonies and failed to grow without the use of blood. Gram-staining was, in all the cultures examined, persistently negative.

Unlike the two cases previously described, the leucocytosis in this case was low (10,000), thus resembling the cases of chronic streptococcal endocarditis.

Death occurred rather suddenly two weeks after the blood culture had been undertaken. A *post-mortem* examination was not obtained.

In view of the present difficulties in deciding the exact *rôle* of Pfeiffer's bacillus in the causation of influenza, the occurrence of these cases of chronic septicæmia due to this organism obtains additional importance. That it is possible for the blood-stream to swarm with this organism and for the patient meanwhile to be free from any acute symptoms would appear to be a serious difficulty in accepting Pfeiffer's bacillus as the sole causal agent in the disease clinically termed influenza.

January 15*th*, 1907.

24. *An acardiac acephalous ovarian embryoma, with remarks on the pathogenesis of the so-called dermoid cyst of the ovary.*[1]

By S. G. Shattock.

(With Plates IX, X, XI.)

De ovarii embryomate quodam acardiaco acephalo.

(Cum tabulis IX, X, XI.)

Summarium.

Embryoma quod in ovarii cystem projicitur, membris duobus inferioribus, rude autem evolutis, præditum est, vulvâ insuper, atque processu parvo et plano, qui membrum superius sed informe repræsentat.

E cute in pubis situ pili longiores dense excrescunt. Nonne potest hoc ascribi ad secretionem quamdam internam autositi quæ ad parasitum cum sanguine accessit?

Embryomatis super portionem cute tectam, apparet cavum in quo intestinum, utrâque extremitate autem imperforatum, continetur.

In telâ adiposâ ex quâ moles præcipue constat, dissectione monstrantur pelvis informis, columnæ quoque vertebralis ossa, illaque membrorum duorum inferiorum.

Tumor a muliere, virgine, ablatus est.

Dentium et ossium præsentia in cystibus ovarii dermoidibus, pathogenesem probat harum cystium ab illâ cystium aut trunci aut cervicis aut faciei differre.

Cystis ovarii dermoides, ut appellatur, cystis embryomatosa sive teratomatosa haberi debet, embryomate

[1] This paper was communicated to the Society in November, 1904, but for various reasons its publication in the 'Transactions' has been delayed. A full report of it appeared in the 'British Medical Journal' of November 5th, 1904, though several additions are made in the present communication.

diverse evoluto; casubus in quibusdam, quidem, nervorum apparatus includitur centralis.

In exemplis nonnullis teratoma, sicut telæ adiposæ eminentia apparet, ossibus absentibus, sed cute piliferâ induta, et in ovarii cystem projecta cujus a pariete ipsâ pili absunt. Ovarii teratomata comparari insuper possunt cum geminorum fetu acormo aut acardiaco acephalo aut amorpho.

Nunc de ovarii teratomatis pathogenese, adversus hypothesem vulgarem, quâ discitur teratoma embryonem impactam esse, opponi possunt et magna ejus frequentia in ovario, et magna raritas cystium in testiculo similium.

Hanc hypothesem, ergo, proponere audeo, quod teratoma ovarii cystis ex ovo embryonis fertilizato oritur. De fertilizatione embryonis ovi, illam, ut opinor, efficiunt spermatozoa quæ in excessu membranam ovi primi perforant, tempore fertilizationis suæ, et inter blastodermatis cellulas, unum ovorum embryonis ipsius fertilizare parata postea jacent.

Hæc hypothesis,[1] ut illa Parthenogenesis, maturationem ovi in embryone præmaturam (id est globulorum polarium extrusionem) postulat.

Phenomenon autem parthenogenesis generibus animalium tam minus evolutis limitatur ut opinari difficile est Parthenogenesem tam frequentissime in homine evenire quam ovarii teratomatum exempla postulant.

De cystibus testiculi dermoidibus haberi potest glandulam, in quâ cystis includitur, ovotestem fuisse.

Testiculi cystium raritas cum raritate ovotestis humani congruet.

Observationes deinde, a Schlagenhaufer confectæ de testis deciduomate quum membranarum fœtalium

[1] Epiembryogenesis appelletur.

evolutionem postulent, congruent, quoque, cum hac hypothese, quod cystis aut ovarii aut testiculi dermoides ex ovo embryonis fertilizato oritur.

Of the large number of dermoid cysts of the ovary which have passed under my observation this is the most remarkable. Not only has it the interest attaching to what is merely rare or curious, but it possesses the higher importance of proving beyond dispute what the true nature of such cysts is; and lastly, it has suggested to me a theory in regard to the pathogenesis of these cysts which I venture to offer for consideration in the present paper. I may first describe the preparation in detail and afterwards proceed with the reflections raised by it.

Description of the Specimen.

The ovary was removed in February, 1903, by Dr. C. J. Cullingworth, to whom I am indebted for the opportunity of recording it.

The patient was a single woman, aged 33 years, who had for two years noticed some swelling of her abdomen. She had not experienced any pain until a fortnight before her admission into St. Thomas's Hospital. Double ovariotomy was performed on February 2nd. The right tumour forms the subject of the present communication; the left ovary was the seat of a large "dermoid cyst," which contained numerous hairs, but no teeth were stated to have been observed in it. The specimen has been bisected but not mesially, so as to form two preparations which I have thus described in the Teratological Catalogue of the Museum of the Royal College of Surgeons.

4526 c. Portion of a large multilocular cystoma of the ovary.

One of the secondary cysts has been laid open to display a projecting teratoma in which the indications of a second fœtus are unusually evident.

The projection in question consists of an oval body about 6 cm. ($2\frac{3}{8}$ inches) in its chief diameter, is sessile at one end on the wall of the containing cyst, and is at present constituted only by its covering of true skin provided with downy hairs, the interior having been removed by dissection.

From the free, broader end there project two almost

symmetrical processes which represent lower extremities. No distinct subdivisions indicative of digits are present, though the end of each is irregularly cleft in a manner wanting elsewhere, and the epidermis on one aspect is notably thickened and hairless, as on the sole of the foot.

One of the lower extremities (the right) has been divided, the sectional surface showing an elongated thin-walled skeletal element representing one or more of the bones of a limb; the bone itself measures about 1·5 cm. in length and has been emptied of the adipose medulla which filled it. A similar process is present in the opposite limb.

Between the limbs are two distinct "labia" bounding a cleft ·5 cm. in length, behind which is an area of smoother character presenting a median perineal ridge or raphé, whilst in front, in what would correspond with the pubic region, the skin bears long pale hairs. There are no hairs on any portion of the cyst into which the teratoma projects, nor has its interior any of the characters of skin, the integument of the parasite ceasing abruptly at the base of the latter as it does normally at the insertion of the umbilical cord, or amniotic junction. At the base of the teratoma there is a second cavity (cœlom), the wall of which is quite smooth, and loosely adherent to the central part of that portion of the wall which lay on the adipose tissue and bone constituting the trunk, is a well-developed blind coil of intestine, furnished with a thick muscular coat.

Microscopic section of the gut shows a mucosa of lymphatic tissue and simple tubular glands, a muscularis mucosæ, and succeeding this two thick layers of unstriped muscle circularly and longitudinally disposed.

The space in which the intestine lies may be regarded as peritoneal.

4526 D. The remaining portion of the foregoing specimen.

The divided surfaces of what represent the trunk of the parasite and the right of its lower limbs consist of adipose tissue invested with skin and containing the osseous structures next described. The bone in the right lower extremity is the other half of that shown in the divided surface of the same extremity in the preceding preparation, the soft adipose medulla being left *in situ*.

In the trunk of the parasite the skeleton has been displayed by dissection almost in its entirety.

The chief portion comprises four or more flattened elements closely connected by intervening lines of cartilage, the chief of which is furnished with a neural arch of compact osseous tissue, the whole representing an abortive spinal column. The column bears two symmetrical appendages which together may be viewed as the pelvic girdle; that of the left side has been fully exposed, and consists of an elongated element 2 cm. in length, furnished with an expanded lower end to which is appended a bulbous enlargement 1 cm. long. The distal end of the proximal or first of these elements, however, is not merely enlarged but produced towards the middle line by means of a triangular process the apex of which lies in apposition with a precisely similar process from the bone of the opposite side. The paired elements in question circumscribe a space below, or beyond, the end of the abortive spinal column.

Although these structures clearly represent a pelvis, no actual continuity (as told by needling the intervening fat), exists between them and the osseous elements in the lower limb. From a foramen in the vertebral canal there was withdrawn during the dissection a well-defined tough cord which microscopic examination showed to consist of bundles of medullated nerve-fibres.

At the back of the preparation a portion of the wall of the cyst containing the projecting trunk of the teratoma has been cut away to show that the latter bears a rudimentary upper limb in the form of a flattened oval appendage about 1·5 cm. in its longer diameter. There is no corresponding rudiment of an upper extremity, however, on the other half of the trunk shown in the preceding preparation.

Microscopic examination of the cyst-wall at a distance from the embryoma shows it to consist of close fibrous tissue, without an epidermal lining, like the sterile loculus of an ordinary multilocular cystic adenoma.

The growth of pubic hair on the embryoma is a further subject of no little interest in this remarkable specimen. Seeing that the rest of the skin is covered only with fine lanugo, the growth referred to must be taken as marking the advent of puberty. As the presence of sexual glands in the teratoma itself may be excluded (for there is nothing but a coil of gut in the abdominal cavity) the explanation of its puberty must be sought in a maternal influence, or more definitely in the action of an internal

secretion produced by the sexual glands of the autosite; the autosite and the embryoma will have acquired the cutaneous marks of puberty simultaneously.

The general question of the formation of an internal secretion as a factor in the development of external sexual characters is dealt with in a communication by Dr. C. G. Seligmann and myself in the fifty-sixth volume of the Society's 'Transactions.' The teratoma under consideration affords further evidence in support of the views there put forward. It is, in fact, a natural experiment which successfully carries out one that was devised by ourselves, but was incomplete in result. Our experiment was planned to ascertain whether the blood of an intact individual would incite the production of external sexual characters in a second from which the sexual glands had been removed.

It consisted in grafting together by the legs a castrated cockerel and an intact cockerel of the same age and kind. Although the operation itself was successful, one of the grafted birds, in each of the four cases in which it was carried out, died within a few days, without obvious cause ('Path. Soc. Trans.,' vol. lvi). The object of the experiment was to see whether the castrated bird would, as it matured, put on the plumage and comb of the cock from the access of blood to it from the intact bird.

In the ovarian embryoma the experiment has been accomplished. The trunk of the embryoma being without heart and independent circulation has been supplied with blood solely from the side of the autosite, and with the result that the overgrowth of hair which marks the advent of puberty, has actually been brought about.

The Pathogenesis of the so-called Dermoid Cyst of the Ovary.

If we exclude the so-called dermoid cysts of the ovary and testicle, the pathogenesis of the common dermoid cyst cannot be said to present any difficulty. Yet even in regard to such it is necessary to distinguish proper dermoid cysts from certain others that have been and are still at times incorrectly named dermoids of the neck.

This subject I have discussed at length in the forty-eighth volume of the Society's 'Transactions,' where I have submitted that the presence or absence of a stratum granulosum should be

EXPLANATION OF PLATE IX,

Illustrating the communication by Mr. S. G. Shattock on "An acardiac, acephalous ovarian Embryoma," etc. (P. 267.)

FIG. 1.—The embryoma or parasite projecting into its containing cyst, viewed from the front, showing the ill-developed lower limbs and "vulva." Above the "vulva" is a well-marked tuft of pubic hair. Above the skin-covered portion of the parasite there is a cœlomic cavity, containing a blind coil of intestine. No. 4526c. Mus. Royal College of Surgeons.

FIG. 2.—A view of the parasite from the left side, showing a flattened pendulous process representing the single rudimentary upper limb.

FIG. 3.—A sagittal section of the parasite, showing the bones of a rudimentary spinal column and of the left lower limb, which have been dissected out from the other half, and project from the divided surface of fat, of which the mass chiefly consists.

FIG. 4.—The pelvis of the parasite, with the bones from the rudimentary lower limbs. The dotted line indicates the bones in the divided but undissected limb.

All the figures are of the natural size.

TABULA IX,

Ad dissertationem "De Embryomate quodam acephalo Ovarii" illustrandam.

S. G. Shattock. (P. 267.)

FIGURA 1.—Embryoma sive parasitus in cystem ovarii monstratur projectum, duobus membris inferioribus, rude autem evolutis, et vulvâ insuper præditum. E cute in pubis situ pili longiores dense excrescunt. Embryomatis super portionem cute tectam, apparet cavum in quo intestinum, utrâque extremitate imperforatum, continetur.

FIGURA 2.—Embryoma idem ex parte sinistrâ conspectum. Processus conspicitur parvus atque planus qui membrum superius sed rude evolutum repræsentat.

FIGURA 3.—Embryomatis ejusdem sectio sagittalis. Monstrantur columnæ vertebralis informis ossa, illa quoque membri inferioris sinistri. Hæc ossa, ex alterâ parte embryomatis dissecta, de telâ adiposâ, ex quâ moles præcipue constat, projiciuntur.

FIGURA 4.—Embryomatis pelvis ossa unâ cum illis membrorum inferiorum.

Figuræ ad magnitudinem naturalem delineatæ sunt omnes.

Fig 1

Fig 2

Fig 3

Fig 4

reckoned as the criterion between such classes of cysts, seeing that this stratum is the distinctive mark of epidermis as contrasted with the otherwise closely similar epithelium of such mucosæ as the buccal, pharyngeal, œsophageal, or vaginal. There are on this understanding dermoid cysts, and what I have ventured to call mucosal cysts of the neck, the latter being cysts formed from the branchial diverticula and furnished, it may be, with a stratified epithelial covering like that which in the later stages of embryonic development lines the pharynx itself. Disregarding mucosal cysts, then, the ordinary dermoid cyst is so aptly explained as resulting from epiblastic sequestration, *i. e.* as being due to the inclusion of portions of the primitive epiblast during the closure of embryonic clefts, that nothing further is required. Thus are fully explained, for instance, the dermoid cysts which occur in the mid-line of the trunk, whether over the sternum, or in the scrotum, or the perineum, or on the back.

The dermoid cysts of the ovary and testicle, however, have ever been a source of wonder, containing as they so often do such highly differentiated macroscopic structures as teeth and bone. There are, it is true, other situations than the ovary and testicle in which teeth may be encountered in relation with cysts, excluding, of course, the dentigerous or follicular cyst of the jaw originating in the sac of an unerupted tooth.

Such are the cysts to which Mr. Bland-Sutton[1] has, in this country, drawn attention, viz. the dentigerous cysts of the neck in the sheep and horse, although, as he observes, Gurlt had figured a similar specimen in the sheep in 1877.[2] A satisfactory explanation of such, however, has been offered in viewing them as the results of an abortive anterior dichotomy.

Just as in the case of a second, attached, or parasitic individual, all grades of hypoplasia are met with, so is it in the lesser phenomenon of what may be termed parasitic dichotomy, where in place of an equable or symmetrical duplication of the posterior or anterior part of the axis one of the duplicated portions fails to develop to the full extent. Thus, in the lower part of the trunk are explained the presence of a third lower limb (in which the fusion of a pair may be obvious), and certain of the tumours attached to the back of the sacrum, whether bearing the

[1] 'Path. Soc. Trans.,' vol. xlii, p. 477, 1891.

[2] 'Thierische Missgeburten,' Taf. xv.

rudiments of lower limbs or not, though other such tumours which present the rudiments of upper limbs as well as of lower[1] must be viewed as representing more than the results of an abortive posterior duplication, and rather as an abortive second individual connected with the sacrum of an autosite, the connection being of the kind observed in the lesser grades of dorsal union or opisthozygosis, where the two equally developed individuals are conjoined by the sacra (pygopagus).

In recent times living examples of pygopagus have visited London under the designation of the "Two-headed Nightingale" (1871, 'Lancet,' vol. i, p. 725), and the "Twin Hungarian Sisters," Rosa and Josefa Blazek (1904).

I may note, in passing, that amongst plants a similar disproportionate growth may be observed in some cases of the duplication of fruits arising from fusion (syncarpy). I have seen this in the apple, vegetable marrow, plum, almond.

It is interesting that here, also, the diminutive or "parasitic" element may present arrests in the development of its higher organs.

In two cases of the kind affecting the apple, which I have had the opportunity of examining, no seeds had developed in the ovary of one (853B, Coll. Surg.); and in the other (when the parasite was particularly diminutive (853A, Coll. Surg.) no ovary was discernible to the naked eye in the longitudinal section carried fairly through the remains of the calyx.

As in a parasitic posterior dichotomy, so in an anterior the parasitic element may be so abortive or monstrously developed that its true origin is hardly recognisable. Some such anterior teratomata appear to result from an ill-completed dichotomy, others to the impaction of a second embryo. Nor is it easy where the results are so aberrant to decide between the two, except that when the teratoma presents lower extremities, in addition to upper, together with rudiments of intestine, etc., it must be taken as arising from the cohesion or impaction of a second individual.

In the Obstetrical Society's 'Transactions,' vol. xliv, Mr. H. S. Stannus has described an example of teratoma of the head in a fœtus, to which he has appended a bibliography and a short

[1] As in the case figured by Braune, from Fleischmann, Taf. iii, fig. 7, "Die Doppelbildungen und Angebornen Geschwülste der Kreuzbeingegend."

account of cases of a somewhat similar character, some thirteen in number, exclusive of a specimen in the Museum of the Royal College of Surgeons, which the author has overlooked. The latter specimen, No. 168 (Teratological Series), is the injected head of a human fœtus with a large lobulated vascular tumour growing from the median fissure of the palate, which has been kept open by it. The parasite projects from the mouth, which is considerably dilated, and itself presents a widely extended mouth.

The skin of the tumour is covered with lanugo; one of its "lobes," which contained a compact mass of bones, presents three indistinctly separate, hard, white eminences, suggestive of aborted digits.

And to come back to the dentigerous cysts of the neck in the sheep before referred to: that these represent aborted parts of one of the elements in an imperfect anterior dichotomy is shown by the fact that the opening of the cyst in the neck is clearly that of a second mouth. The demonstration of this is due to Gurlt,[1] who describes one specimen, amongst several, in which two temporary incisors were fixed in an ill-formed mandible and associated with a diminutive tongue; the fistulous track communicated with the pharynx. Mr. J. Bland-Sutton describes and figures a less marked example[2] in which an incisor is lodged in a bony process surrounded by mucous membrane having the same features as the gums; the recess in which it lies presents, where in contact with the tooth, a number of processes resembling the papillæ on the sheep's lips, the arrangement of the wool on the outer surface of this accessory lip being, moreover, identical with that covering the normal lip of the sheep.

So long as the dermoid cyst of the ovary was considered to be essentially of the same nature as that found in the trunk or elsewhere, some explanation similar to that which sufficed for the latter was sought for in case of the former. Hence, when the epiblastic or ectodermal origin of the segmental or Wolffian duct became tenable, it was thought, in some obscure way, that the ovarian dermoid admitted of being accounted for, seeing that portion of the duct in question constitutes the main or horizontal tube of the parovarium between the layers of the broad ligament.

[1] 'Thierische Missgeburten,' Berlin, 1877, Taf. xv.

[2] J. Bland-Sutton, 'Transactions of the Odontological Society of Great Britain,' vol. xxxvi, 1903, p. 19.

Whatever is true, however, of the Wolffian duct, the tubuli of the mesonephros or Wolffian body arise from the splanchnocele or cœlom and open secondarily into the duct; they are certainly not ectodermal in source.

Conceding that such an explanation as that referred to held good at all, it would hold only for a simple dermoid cyst of the broad ligament, and could not be regularly extended to the ovary, seeing that the Wolffian tubuli in the hilum of the latter have not an ectodermal origin.

In the case of the complex ovarian dermoid with its contained bone and teeth the explanation advanced is inadequate, and its inadequacy becomes glaring when applied to such a teratomatous or embryomatous cyst as that described in the present communication.

Although the teratoma in question is so striking, it is unique rather in degree than in kind. Its chief anatomical interest lies, indeed, in the fact that it serves to establish the true nature of the less striking, and therefore ambiguous forms of the so-called ovarian dermoids, just as in normal morphology the nature of so many vestigial structures becomes apparent only from the gradations which link them to fully developed organs.

Who would have imagined, for example, that the ligamentum teres in the human hip-joint is the degraded representative of an intra-articular muscle arising from the ischium, as it appears in Sphenodon and certain other lizards?

In the Felidæ, again, the clavicle is represented at either end by fibrous tissue; and in Ungulata the last remnant of bone has disappeared, the entire element being replaced by a fibrous substitute.

Still more apposite are the examples furnished by the gradual degradation and ultimate disappearance of the limbs in certain families of the Order Lacertilia, for in the ovarian teratomata the recognition of limbs is in some cases made certain only by somewhat similar connecting links.

From the comprehensive 'Catalogue of Lizards' by Mr. G. A. Boulenger (Brit. Mus. Nat. Hist., second edition), all the necessary examples may be selected. In the family Pygopodidæ (Boulenger) "the serpentine body is destitute of functional limbs; the fore limb is entirely absent, while the hind pair is visible externally as a scaly flap, most developed in Pygopus, in which

the bones of the limbs may be felt more or less distinctly ; when the skin is removed in Pygopus, the foot, with five ossified toes, is seen most plainly, especially in the males ; the ischium appears. externally as a small spur on each side behind the anal cleft."

In the family Anguidæ the limbs may be more or less developed, or entirely absent externally, in which case, however, the rudiments of the pectoral and pelvic arches are always present.

The disappearance of the limbs is to be traced *gradatim* in the genera of the family.

Limbs four, pentadactyle . .	(1) Gerrhonotus.
Limbs absent, or the hind pair rudimentary externally . . .	(2) Ophisaurus.
Limbs four, pentadactyle. . .	(3) Diploglossus.
Limbs four, tetradactyle . . .	(4) Sauresia.
Limbs four, mono- or didactyle . .	(5) Panolopus.
External rudiments of the hind limbs .	(6) Ophiodes.
No trace of limbs externally . .	(7) Angius.

The common slow worm (Angius fragilis) is typical of the last genus.

In the family Scincidæ (Skinks) the limbs are in some genera present, in others absent externally, in others in various grades of disappearance.

In Lygosoma fragile, *e. g.* the limbs are very weak and tridactyle.

In Lygosoma gerrardii, the limbs are very weak, the anterior mono- or didactyle, the posterior didactyle.

In Lygosoma miopus the fore limb is represented by a minute tubercle; the hind limb is monodactyle.

In Ophiomorus latastii the body is limbless.

In Scelotes guentheri the fore limbs are absent ; the hind limb is a minute bud-like rudiment.

In Scelotes inornatus the limbs are absent.

I append a figure of the skeleton of the right half of the rudimentary pelvis and the hind limb, from a specimen of Ophisaurus apus lately added to the College Museum. The element of the limb is a minute simple piece of bone 4 mm. in length, which articulates with the pelvis (Pl. X, fig. 4). The only external indication of the limb in this lizard consists of a small scaly, somewhat flattened tubercle on either side of the vent.

Even amongst Ophidia, in certain of the highest forms, as the

python, a rudimentary hind limb is present, the external evidence of which is apparent in the presence of a single claw on either side of the anal opening. The osseous elements, as demonstrated by dissection, comprise a pelvis and a single bone representing the component structures of a limb. The single bone representing the skeleton of the limb is furnished with a claw, the limb being thus monodactyle.

It is possible to trace gradations, then, from so highly developed an embryoma as that described in the present communication to the mere limbless eminences of fat covered with piliferous skin, which may be found almost regularly projecting into an ovarian "dermoid."

These eminences, I submit (they have at times been called pseudo-mammæ from their fancied resemblance to a breast and nipple) are all of them teratomata in their lower grades of development. Yet there may be still, I believe, a lower one; the teratoma may possibly be represented by a mere patch of piliferous skin. For although the cysts are called dermoid, the hair does not grow indifferently from the whole of the interior of the cyst, but is confined to a limited or specialised area.[1]

And a more correct designation of the so-called ovarian dermoid would be that of embryomatous or teratomatous cyst of the ovary. By this name I will call such throughout the rest of this communication. The presence of teeth necessarily demonstrates the teratomatous character of the cyst in which they occur; but in the case of other ovarian teratomata, even those of a well-pronounced kind, teeth are wanting; there are none in the specimen which forms the subject of the present communication.

These differences we must attribute to differences in the developmental arrest, which involves now one part and now another of the embryoma. There are acormous (or trunkless) and acephalous (or headless) embryomata, as there are in the case of acardiac homologous twins, to which I will again refer.

In regard to the displacement or lateral dislocation of dentigerous and other bone, and the utter absence in most cases of any structure morphologically like a cranium, one must not

[1] A perusal of museum catalogues without an inspection of the preparations is in this respect liable to mislead. In many cases the cyst is said to be formed of piliferous skin, when it is quite smooth and hairless, the hair being, in short, confined to the skin-covered eminence representing the teratoma.

overlook the mechanical action of the enlarging cyst and the pressure of its contents in exaggerating what are, probably, also original defects of formation.

Nevertheless, in the osseous elements from teratomatous cysts of the ovary, which have been prepared by maceration, the general characters of cranial and facial bones are at times strikingly represented.

And that such resemblances are not to be in every case dismissed as merely fanciful is shown by the circumstances that some which carry teeth are like misshapen parts of the jaws.

In the collection of such macerated bones from ovarian cysts in the College collection, there is one (No. 4526A) which in its form is particularly suggestive of a badly developed temporal bone.

On sawing through what appears, from its density and position, to be a petrous bone, I found a well-defined, though irregular cavity within, highly suggestive of an auditory origin.

Embedded in another part of this bone there is a small tooth, in position suggesting those found in the mastoid of the horse.

The striking length of the hair in certain ovarian cysts, again, can hardly be explained except by regarding such hair as growing from a cutaneous area answering to the scalp, and this view is strengthened when the hair arises in the neighbourhood of a dentigerous process of bone, as in specimen No. 4511, Museum Royal College of Surgeons.

The hair in another College specimen, No. 4513A, is twenty inches in length. Here, as in other cases, the mass of hair is confined to an elevation covered with true skin, *i. e.* to the proper teratoma. The teratoma itself is of inconsiderable size, simple in external form, and projects into a cyst, which was the size of a cocoanut, and within which the hair, mixed with sebaceous material, was coiled up. The cyst was removed by operation from a woman in the third month of pregnancy.

Munde has described a mass of hair five feet in length from an ovarian cyst ('American Journal of Obstetrics,' vol. xxiv, p. 854), although here, as in certain other cases of extreme growth (*e. g.* of the beard), one must distinguish between the length of individual hairs and that of the mass as a whole, the length of which is in part due to the entanglement of hair already shed and carried forwards by that still growing behind.

But the view that such dentigerous bones represent the cephalic end of an embryo is definitely proved by the presence of central nervous tissue in connection with them. So long ago as 1853 Henry Gray[1] described such a case. It was that of a *single* woman, aged 28 years, from whom an ovarian cyst was taken after death. The main cyst contained a tooth, and hair, etc.; but projecting into this was another cyst, about the size of a walnut, situated near the dentigerous bone referred to; the wall of this latter cyst was delicate, its inner surface was highly vascular; the vessels were large, forming numerous meshes, which resembled somewhat those of the pia mater. The contents of the cyst consisted of a softish white substance, the surface of which was perfectly smooth and presented all the characters of brain. On microscopic examination it was found to consist entirely of the ordinary elements of nervous matter, being composed of a very large number of varicose nerve tubules of varying size, intermixed with the "elementary components of grey matter, viz. nuclei and nucleated vesicles containing granules."

In the absence of teeth and bone, however, though cephalic elements of an embryo are wanting, yet proof can be adduced in so many cases that the ovarian dermoid is teratomatous, that it may be almost assumed that this is true of all. And I may next proceed to select from many such cysts examples which show their teratomatous character by means of the morphological gradations which the teratomata present. One which comes nearest to that recorded in the present communication, and which supplements it by presenting a cephalic end in addition, was presented by Robert Liston to the Museum of University College. It is thus described in the Catalogue:

4035, University College. Portion of the contents of a dermoid cyst of the ovary.

The specimen consists of a portion of the cyst-wall attached to which is a mass having some resemblance to a human fœtus. The rounded portion above (about the size of a large walnut) represents the head, and in the centre of this is a rounded aperture, the mouth, through which three teeth project. On each side is a solid projection of soft tissue in the position of the ears. The rounded portion described as representing the head is

[1] "An Account of a Dissection of an Ovarian Cyst which Contained Brain," by Henry Gray, F.R.S., 'Med.-Chir. Trans.,' vol. xxxvi, 1853, p. 433.

bony, covered by integument, and consists of the lower jaw and part of the upper. At the top of it is a rounded cavity, lined by a smooth membrane; this probably represents the base of the skull—there is no roof.

The upper part of the trunk and the upper limb are rudimentary and ill-developed. On the left side are an arm and part of a forearm, with rudimentary joints.[1] The arm contains one bone—the humerus, but the radius and ulna are both present. On the right side the upper limb is represented by a fold of integument. The rest of the body (including the lower limbs ?) is represented by a large process of bone partly covered by integument, and connected by it to the front of the rudimentary chest.

The patient, aged 47 years, had borne several children. For some time she had suffered from disease of the abdomen, accompanied by "dropsy," which continued to increase, and ultimately destroyed life. At the autopsy a cyst containing two or three pailfuls of fluid was found in the abdomen. It was situated in the left iliac fossa and covered by healthy peritoneum. The cyst contained hair and fatty material in addition to fluid and to the parts preserved in the specimen.

The next preparation is remarkable in that the ovary contains three distinct cysts of different sizes into each of which there projects an embryoma:

4511, Museum Royal College of Surgeons.

The embryomata exhibit different grades of development, so that in the same ovary the nature of the least developed is deducible from that of the higher.

The largest of the embryomata, and the most highly developed, is furnished with two appendages of unequal size, but paired in relation to its longer axis, and representing the buds of lower limbs. The larger of the limbs measures 1·5 cm. in length; the other, which is more slender, and constricted into a larger proximal and a smaller distal segment, is but 1 cm. In the middle of the larger there is a slender splint of hyaline cartilage.

The only bone in the teratoma, the bulk of which consists of fat, lies at its base of attachment, and into this two teeth, which project from the free surface, are fixed.

[1] The length of the upper arm is 7·5 cm. (3 in.), that of the forearm about half this.

Growing from an area of the skin of the teratoma near its base, and in the vicinity of the projecting teeth, is a tress of flaxen hair, over seven inches in length. This hair, from its length and relationship with the dentigerous bone, must be viewed as representing that of a scalp.

Embedded in the fat of the teratoma near its base, but on the superficial aspect of the bone referred to, there is a well-defined spheroidal sac, half of which is discontinuous with the surrounding tissues, has a smoothly polished exterior, and lies in a thin-walled cavity representing the peritoneum or cœlom. Microscopic sections show the sac in question to consist of a thick wall of unstriped muscle-fibre, disposed in circular and longitudinal directions, and a mucosa in which a thin sheet of lymphatic tissue is present. The mucosa is lined with a single layer of well-formed cubical cells, but is devoid of glandular crypts and villi; at one spot the lymphatic elements are aggregated into a hemispherical eminence or solitary follicle.

This sac, therefore, may be taken as the representative of a primitive intestine in which no crypts have developed, and in which the hypoblastic cells have retained their original cubical form.

This preparation is remarkable, as already observed, in that the same ovary is the seat of two further, and quite distinct, teratomatous cysts, *i. e.* cysts into each of which a teratoma projects.

One of these cysts, which like the others has a smooth, hairless inner surface, is an inch in diameter, and bears a skin-covered, piliferous teratoma. The latter is not more than 1 cm. in its chief diameter, and on section shows to the naked eye only fat, without bone, or any indication of intestine or cœlom. In form the teratoma is spheroidal, yet it presents at one spot a pedunculated appendage 9 mm. in length, suggestive of a limb-bud.

In microscopic sections made to include the *appendage*, the trunk of the teratoma is found to consist mainly of very large sebaceous glands, which lie beneath a corium covered with epidermis. In addition to sebaceous glands there are well-formed sweat-coils. Some of the latter are dilated and exhibit the characteristic investment of longitudinally arranged and elongated cells commonly regarded as muscular.

In the centre of the *appendage* there is an oval nodule of

hyaline cartilage covered with a perichondrium; the cells of the cartilage are closely packed, and the central are of conspicuous size, the whole recalling the picture presented by the primitive cartilage of a long bone in the first stage of ossification, wanting the deposition of calcareous granules.

Around the cartilage there is a scanty amount of fat. The skin is furnished with sebaceous and sudoriferous glands.

The third cyst is about an inch and a half in diameter; within it there is an elongated teratoma, about 4 cm. in length, covered with piliferous skin, and bearing at one end a tooth.

The teratoma is attached only by its two extremities, and is unconnected with the cyst wall for the distance of an inch between. In longitudinal section it displays to the naked eye only hairs and sebaceous glands lying in adipose tissue.

The diseased ovary was removed from an *unmarried* lady, in whom symptoms of ovarian tumour were first observed when she was eighteen years of age.

No. **2371**, St. Thomas's Hospital Museum.

In this remarkable specimen there are, as in the preceding, three distinct cysts in the same ovary, each of which bears a teratoma. Both ovaries were diseased, and are preserved together in the specimen.

The lowest of the three cysts is not more than 3 cm. in its longer diameter. Its interior is quite smooth and hairless except for a well-defined area, continuous with the base of the teratoma.

The teratoma, which is 1·5 cm. in length and is attached by its two ends, is thin and membranous, except at its chief base of attachment, where it is covered in part with piliferous skin. On cutting it across it is found to be tubular, but no nervous tissue is recognisable in the wall as it is in the teratoma within the highest of the three cysts, its interior being uniformly smooth.

The tubular condition of the teratoma, judging from the evidence afforded by that within the highest cyst, may be regarded as due to an abnormal dilatation of the canal of a central nervous system.

The piliferous area of the cyst-wall in connection with the base of the teratoma must be itself viewed as portion of the latter, for it is sharply circumscribed and lowly raised from the presence of dense clusters of sebaceous glands. Moreover, at one spot the base of the teratoma and the adjoining portion of the cyst wall give attachment to a small, solid, piliferous process

in the divided surface of which, however, nothing appears except the sections of hairs and sebaceous glands. Microscopic sections of the cyst-wall at a distance from the teratoma show a complete absence of hairs and glands.

The middle one of the three cysts is almost spherical, and has a diameter of about 4 cm.; its general interior is smooth.

The teratoma within presents itself as a somewhat flattened hemispherical, piliferous eminence about 1·5 cm. in diameter; it is centrally more sharply elevated so as to bear a superficial resemblance to a nipple on its areola; at its base it presents a small tubercle which shows, however, in section nothing other than sebaceous glands. From this, the chief portion of the teratoma, which is sessile on the wall of the cyst, there is continued a short strap-like process covered with piliferous skin; this, which is about 1 cm. in breadth, is free or unattached to the cyst-wall for a distance of about ·7 cm., beyond which it is incorporated with the latter, the wall of the cyst for a short distance about its site of attachment being piliferous, and still further off being for some way lined with epidermis, though devoid of hairs.

The hair growing from the teratoma is about two inches in length, and of a well-pronounced brown colour. The hair contrasts in colour with that growing from the teratoma of the highest cyst, which is quite pale or flaxen.

Histology.—The chief feature in point of amount, in the sections carried through the entire teratoma, are the large sebaceous glands of the skin in connection with the hairs.

In addition there are sweat-coils in which the characteristic structure is particularly clear, the secreting epithelium being surrounded with a continuous sheath of longitudinally disposed narrow fibres or cells furnished with oval nuclei. Some of the coils are considerably dilated, but their nature is obvious from the persistence of the typical structure.

Were it not for the presence of the muscular sheath it would not be possible to identify the glands in question as sudoriferous. They might almost be taken for mammary.

Although the mammary glands, in mammals generally, have their source in modified sebaceous glands, nevertheless, in the Echidna and Ornithorhyncus, Gegenbaur[1] long ago recognised

[1] 'Zur Kenntniss der Mammar organe der Monotremen,' von Carl Gegenbaur, Leipsig, 1886.

their origin from sweat-glands, by means of the presence of the muscular sheath. The sweat-glands, certainly, in the teratoma are considerably modified and the coil abnormally voluminous, not from dilatation merely, but from overgrowth; they bear a remarkable resemblance to the lobules of the mammary glands of Echidna, which retain a tubular structure and open on the free surface of the skin without the intervention of a nipple.

When we consider how ill-developed these teratomata are, we may be prepared not only for reversion or atavism of a grosser kind, but one also of histological structure—a teleplasia, as I have ventured to name it.

Bundles of unstriped muscle-fibre (erectores) occur in the neighbourhood of the hairs.

By far the most interesting structures, however, are well-defined bundles of nerve-fibres, and a substance which represents a *central nervous system.*

The latter appears in the section as a small, almost circular body loosely connected peripherally with a narrow line of fibrous tissue—its meninges.

Of the nerves, some lie in, and some immediately beyond the "membranes." In the substance of one particularly conspicuous nerve, which is closely related to the meningeal fibrous tissue, ganglion cells are collected in large numbers; these cells are of great size, furnished with a prominent nucleus and nucleolus, and surrounded each with a proper nucleated sheath. This, possibly, represents a Gasserian ganglion.

To return to the central nervous system, its substance consists mainly of a felt-work of neuroglia, *i.e.* of delicate fibrils with appertaining cells furnished with small round or short oval nuclei, but supporting, in addition, a certain number of great nerve-cells. The cells in question have a large nucleus and nucleolus, and are polymorphous, produced into the angular processes characteristic of the largest cells of the central nervous system. From some of the cells, processes, axons and dendrons are traceable into the general fibrillar basis. In sections stained with aqueous solution of eosin and afterwards with toluidin blue (1 per cent. aqueous solution, half a minute, 80 per cent. alcohol, absolute alcohol, xylol balsam) Nissl bodies are displayed in the nerve-cells. No medullated fibres are discernible in the central substance. In sections so stained, the nerve-cells of the

gangliated cord already referred to, likewise show typical Nissl bodies arranged somewhat concentrically with the nucleus.

The wall of the cyst in which this teratoma is contained exhibits an epithelial lining of a single layer of muriform cells. There are no traces of hairs or of any kind of cutaneous glands.

To take, lastly, the highest of the three cysts in the same ovary: In this, which is about one inch and three quarters in diameter, there is contained a long tubular embryoma, which is wrapped in a circular manner against the interior to which it adheres in three spots, but is elsewhere free, or unattached. In the original incision made to open the cyst, the embryoma has been divided across its long axis into two nearly equal portions. For the sake of clearness the portion in each half of the cyst may be described separately. That in one half is about an inch and a half in length and three-quarters of an inch in diameter, and it is incorporated at either end with the wall of the cyst, being elsewhere non-adherent.

From it there grows a tress of pale or flaxen hair fully seven inches in length. The teratoma on cross section is tubular, and comprises a body-wall of piliferous skin and fat, enclosed by which there is a second tubular structure consisting for about half of its circumference of an extremely delicate membrane, and elsewhere of a pair of semi-circular masses joined peripherally by a commissure, but in the rest of their extent separated by a fissure which opens out into the membranous segment of the tube. As proved by its microscopic structure the tubular body itself represents a *central nervous system.*

The outer body-wall is for the most part formed of true skin and subcutaneous fat, but in two situations it is thin and membranous: one of these membranous areas (both of which run in the long axis of the teratoma) lies on the aspect farthest removed from the nervous substance referred to; the other lies immediately along its commissure. Although the general cavity of the cyst containing the embryoma is smooth, yet about the end from which the chief mass of hair arises it is lined with true skin in which the orifices of empty hair-follicles are obvious to the naked eye.

At this end of the embryoma there is a blind depression, admitting the end of a probe, and bounded by two very distinct lips. It lies in close connection with a ring of bone which, for

reasons to be presently stated, may be taken as portion of the base of a skull, and the depression itself must be viewed as a *stomodæum.*

The portion of the teratoma in connection with the other half of the cyst may be thus described: Not quite equal to the other in size it has a similar tubular form, but is thin and membranous without cutaneous investment. Like the other half it is attached by its two ends, and is elsewhere free. The interior of the tubular sac is vacant, without any trace of nervous substance.

At one pole of attachment the teratoma is continuous with the other portion in the opposite half of the cyst; the other pole is simply fixed to the wall of the cyst, a distinct interval intervening between the termination of the teratoma here and that in the other half of the sac, the parasite as a whole being somewhat horse-shoe shaped.

The cyst immediately about the anterior pole of attachment is formed of skin, and from the skin there here projects a small pedunculated, solid, skin-covered process as large as a small pea. This process consists microscopically of fat embedded in which there is a well-defined central process of cartilage. When the two portions of the tubular teratoma are pieced together the membranous sac is seen to be continuous with the other tubular portion by a narrow constricted process which traverses a ring of bone; and from the dilated spinal cord in one sac there is continued through this ring a process of nervous substance which projects for a short distance into the otherwise empty sac. The membranous sac itself may, therefore, be viewed as formed in connection with the cephalic portion of a central nervous system.

Let me finally, in connection with this specimen, refer to the *Histology* of the process containing cartilage, and of the central nervous substance. Microscopical examination shows the appendage to consist of connective tissue in which a few groups of fat cells lie; it is covered with piliferous skin furnished with erector muscles, large sebaceous glands and sweat-coils.

In its centre there is an oval area of cartilage. No bone formation is in progress. The central cells of the cartilage are of considerable size; more outwardly the cells become smaller, and are smallest at the periphery beneath the perichondrium. The matrix is not hyaline, but pervaded with closely intersecting stiff-looking fibrils of great delicacy. In sections treated with Unna's

acid orcein for twenty-four hours the reddish-brown colour taken by the fibrils proves that they consist of elastic tissue, and that the cartilage is of the elastic variety.

I, therefore, interpret the appendage itself to represent an abortive pinna, and not, in this case, a limb bud. Its proximity to the stomodæum supports this interpretation.

The skin and fat, *i. e.* the body-wall of the embryoma enclosing the central nervous system, present the usual components, viz. hair and large sebaceous glands, with bundles of unstriped muscle-fibres (erectores pilorum) and sweat-coils. The nucleus of many of the fat cells presents a single vacuole of varying size, such as I have elsewhere shown to be due to the storage of fat in the nucleus itself ('Path. Soc. Trans.,' vol. liv, p. 215).

The tubular structure representing a central nervous system is but loosely connected with the enclosing fat and skin. It comprises on one aspect two somewhat hemispherical masses of nervous substance united by a commissure and shading off on the opposite into a thin membrane which completes the tube. Opposite the commissure and at the other pole of the cross section the body-wall is thin and membranous; elsewhere it consists of skin and fat. The membranous portion of the tube is lined with columnar epithelium, which is continued into the cleft between the hemispherical processes of the nervous tissue, the whole cavity obviously representing that of a central nervous system, either cephalic or spinal, pathologically dilated by a hydrocephalic or hydromyelic process.

The nervous substance presents the same structure as that described in the teratoma of the middle cyst of this same ovary. It shows a delicate reticulum of fine fibrils provided with cells having oval nuclei, and in it there lie many large branching nerve-cells, furnished with conspicuous nucleus and nucleolus. In sections stained with toluidin blue Nissl bodies are obvious in parts of certain of these cells.

In addition to the triple teratomatous cysts of this ovary it is noteworthy that the opposite ovary of the same patient contains a further embryomatous cyst of larger size than any of the rest. The teratoma projecting into it is so deformed from internal distension that its true nature would be quite unrecognisable without the evidence afforded by those already described.

The cyst which bears the teratoma is quite four inches in its longer diameter, and its interior is quite smooth.

Into it there project side by side two thin membranous sacs, together nearly as long as the cyst, and each about one and a half inches in transverse diameter. Each of these is attached to the cyst by one of its longer borders, and they are, moreover, adherent to one another at the middle, where they communicate by an aperture about a quarter of an inch in diameter. Continuous with the attached portion of one of the sacs there is a piliferous area about as large as a florin, forming part of the wall of the containing cyst. This piliferous area must be viewed as a peripheral portion of the teratoma, although it shows nothing more to the naked eye on section than skin. Half surrounding the aperture of communication above referred to there is a semicircular plate of bone.

Although the sacs are for the most part fibrous, there is on one of them a track of attenuated piliferous skin about one and a half inches in length; this track is sharply defined on one of its borders, and here succeeded by a thin membrane, which forms the wall of the sac as far as the attachment of the latter to the containing cyst. Let it be finally noted as showing what the nature of the sacs is, that a thin, continuous membrane can be raised from the inner surface of them.

Now then, as to the interpretation. The bilobed sac is a teratoma of which a central nervous system has been enormously distended by fluid effusion, the delicate inner membrane representing meninges, and the thicker external one, of which parts are constituted by piliferous skin, the body-wall. One of the sacs represents a cerebrum, the other a spinal cord, the communication being by the constricted aperture mentioned, the bone around which probably marks the situation of a foramen magnum.

The general conformation, in short, is like that of one of the cystic teratomata already described in the other ovary, the correctness of the interpretation being proved by the fact that in the other teratoma the two halves of a spinal cord are quite distinct on the sides of the sac.

4511 A, Museum Royal College of Surgeons.

The next specimen is of interest in that although the embryoma consists only of fat it possesses a distinct central nervous system, sufficiently developed to be easily recognisable by the naked eye.

The embryoma, which is attached by a somewhat constricted base to the wall of its containing ovarian cyst, is a prominent oval mass of adipose tissue covered with piliferous skin, an inch and a half in longer diameter; the summit is constituted by a spheroidal process three eighths of an inch in diameter, the whole bearing a superficial resemblance to a mamma and its nipple. No bone is detectable by needling, and no intestine or cœlom appears in the sagittal section. On one side of the base of the projection the cyst itself presents a slightly raised patch, about the size of a threepenny piece, of rugose piliferous skin. This patch is continuous with the skin of the teratoma, and must be viewed as a portion of its base displaced in the distension of the cyst.

In the base of the spherical process there is exposed in the sagittal section a small, ovoidal, whitish structure, about 4 mm. in its chief horizontal diameter, and from this there is prolonged into the adjoining portion of the main mass or trunk of the teratoma a narrower process about 5 mm. in length. This is sharply bent in an **S**-like curve where connected with the portion first referred to.

The two structures, which form, in reality, a continuous mass, are enclosed in a well-defined sheath, the disposition being altogether remarkedly suggestive of a primitive brain and cord. This substance, as proved by microscopic examination, represents a central nervous system, although no central cavity indicative of cerebral vesicles or medullary canal appears in the sections.

On one side of the horizontal portion of this central nervous system, separated from it by the meninges, there is a large gangliated cord, probably Gasserian. From this a large trunk can be traced for a short distance into the fat of the spherical head-like process of the teratoma.

One further histological element must be noticed. Contiguous with the gangliated cord, and immediately beneath the skin, there is a dense knot of unstriped muscle in intersecting bundles. There is in this no disposition suggesting the wall of a viscus, yet the fact that a nerve of conspicuous size penetrates it invests it with some morphological significance.

The central nervous system displays the following histological structure. It consists of a mesh-work of fibrils, the nuclei of the cells pertaining to which are, some of them small, deeply-

staining, round, or when viewed longitudinally, short ovals, and others larger, oval, and with a more open chromatin net. Gradations between the two kinds occur. The structure in question must be regarded as neuroglia; for towards the surface the fibrils are continuous with the coarser processes of neuroglia which penetrate from the exterior. The capillaries are comparatively few. No medullated fibres are anywhere indicated.

Corpora amylacea occur in sparse numbers.

In the membrane confining the structure there are groups of grotesque, branching pigment cells; the pigment granules nowhere present any trace of red or brown, but are of deep black.

The really important elements, however, are large branching nerve-cells, in the cytoplasm of which the presence of Nissl bodies is very evident in sections stained with toluidin blue.

The chief group of these cells lies about the centre of the transversely elongated portion of this central nervous system.

Elsewhere the cells are few, and their numbers quite inadequate to justify the view that the fibrils of the main substance may be to any large extent axons or dendrons.

Excepting for the nervous structures and unstriped muscle, the teratoma is constituted solely by fat, the skin investing which is furnished with hair, large sebaceous glands, and sweat-coils, the latter of which present no cystic or other pathological condition. Considerable numbers of branching pigment cells occur in the connective tissue of the corium. There is no pigment in the epidermis.

The pigment granules are everywhere of an intense black colour, and the cells often deeply loaded.

Of the source or meaning of this pigment in the corium and meninges I can offer no suggestion, unless it represents the monstrously misplaced elements of a nascent choroid and retina.[1]

Microscopic sections of the wall of the cyst at a distance from the embryoma show a complete absence of hair-follicles and glands of any kind. The innermost portion is formed of a dense zone of connective tissue. Here and there remnants of an investing epithelium occur; this, where most perfect, is a simple cubical layer, with a thin stratum of overlying flat cells without intervening polyhedral forms.

[1] Virchow has described pigment cells in the normal pia mater of the adult like those of the choroid. (Tumours: melanoma of the pia mater.)

With the following specimen I may close the list, as representative of almost the lowest grade which the ovarian embryoma may take, but in which, nevertheless, the presence of a minute process of bone and of a small ill-developed intestine in the mass of fat composing the teratoma reveals its true nature.

4526E, Museum Royal College of Surgeons.

A diseased ovary (left) with the end of the Fallopian tube. The ovary is enlarged by the growth of a smooth-walled cyst, about three inches in diameter, into which there projects a small, well-defined oval mass of fat representing a degraded embryoma or teratoma. The teratoma measures 2·8 cm. ($1\frac{5}{16}$ inch) in its longer diameter, and is covered with piliferous skin, but unfurnished with any processes suggestive of limbs. The true skin ceases abruptly at the base of the parasite, which is attached by a flat, thin, flexible pedicle, about an inch along its site of insertion into the wall of the cyst; the surface of the pedicle, like the rest of the interior of the cyst, is quite smooth. Growing from one pole of the parasite is a tress of hairs, the longest of which measures seven inches (18 cm.). The rest of the skin is furnished with shorter hairs, the chief of which do not exceed one inch. The long hairs, the length of which suggests that they represent those of the scalp, like the rest are individually pale or flaxen, and though in mass the colour appears somewhat darker, it is far removed from black.

Free within the cyst lay the compact mass, nearly three inches in diameter, of tangled flaxen or pale yellow hair, preserved in the preparation succeeding it (4526G). The section, which has been carried through the teratoma, shows it to consist almost solely of fat covered with piliferous skin, but in the base of the fat near the attachment of the pedicle there has been exposed by dissection a small nodule of dense bone, about the size of a barley-corn, though of less regular form, and on one end of this there lies a still smaller nodule of cartilage.

In the midst of the fat and in proximity to the osseous process described there is a small well-defined spheroidal cavity about 3 mm. in diameter, which shows on microscopic section a well-developed wall of unstriped muscle-fibre, and an epithelial lining without villi or glands. The epithelium is not columnar, but a simple layer of somewhat cubical cells. This structure may be taken as representing a primitive intestine, with ill-

EXPLANATION OF PLATE X,

Illustrating the communication by Mr. S. G. Shattock on "An acardiac, acephalous ovarian Embryoma, etc." (P. 267.)

FIG. 1.—An embryoma projecting into a smooth-walled ovarian cyst, in a case in which there are three distinct cysts in the ovary, into each of which a parasite projects, the embryomata themselves presenting different grades of development. (Specimen No. 4511, Mus. Royal College of Surgeons. Nat. size.) The parasite is furnished with two paired, though not symmetrical, appendages, representing lower limbs. The cephalic end of the embryo is represented at its base of attachment by an irregular process of bone bearing teeth, from the skin in the neighbourhood of which there has grown a tress of hair over seven inches in length. The length of the hair, and its insertion near the dentigerous bone, indicate that it answers to that of the scalp.

FIG. 2.—A vertical section of the same, showing a simple intestine, part of which lies free in an abdominal cavity or cœlom, the whole being embedded in the fat which composes the trunk of the embryoma.

FIG. 3.—Part of a second distinct cyst in the same ovary. Into it there projects an amorphous eminence which represents a low grade of embryoma; from one spot a rudimentary limb-bud has grown out; in this there is, as shown by microscopic examination, a process of hyaline cartilage.

FIG. 4.—The skeleton of one of the hind limbs and part of the pelvis of a lizard (*Ophisaurus apus*) in which the hind limbs are rudimentary (Mus. Coll. Surg.).

FIG. 5.—The skeleton of the hind limb and pelvis of one side of *Python sebæ*, showing the rudimentary limb terminated by a claw (Mus. Coll. Surg.).

FIG. 6.—Portion of a single ovarian cyst into which there projects an oval amorphous embryoma. One pole bears a tress of hair, the length of which (seven inches) indicates that it arises from an area of skin corresponding with the scalp. The rest of the cyst is, histologically, lined with a single layer of flat epithelium. Natural size. (2526 E, Mus. Coll. Surg.)

FIG. 7.—The same embryoma in sagittal section. It consists of fat covered with piliferous skin. Near its base of attachment, embedded in the fat (from which it has been partly dissected out), there is a small oval nodule of bone capped with cartilage. In the fat, moreover, there is a small spherical cavity, the wall of which consists of unstriped muscle-fibre, and a mucosa lined with cubical epithelium; this probably represents a primitive intestine. Natural size. (2526 E, Mus. Coll. Surg.)

FIG. 8.—A vertical section of an embryoma projecting into an ovarian cyst. Natural size. (4511 A, Mus. Coll. Surg.) The embryoma consists of a mass of skin-covered fat, but in this there is exposed a rudimentary central nervous system, in which microscopically there are groups of typical nerve-cells lying in neuroglia. The form of the nervous system is suggestive of a brain and cord. The small circular body on the left hand of this is a large gangliated nerve, possibly Gasserian.

FIG. 9.—One of the cysts of an ovary in which there are three separate cysts, each of which bears an embryoma. (2371, St. Thomas's Hospital Museum. Natural size.) The embryoma in the cyst shown is of elongated form, and is provided at one end with a long tress of hair; at this end there is a blind sac with projecting lips, representing a stomodæum; into this a bristle has been inserted. In front of the stomodæum there is shown part of a divided membranous sac which is continuous through a ring of bone with the tubular cavity of the rest of the teratoma.

FIG. 10.—The stomodæum viewed from the front.

FIG. 11.—A cross-section carried through the middle of the embryoma. Within a covering or body-wall of skin and subcutaneous fat there is a tubular sac, which represents a spinal cord, of which the central canal is abnormally distended (hydromyelus). The upper part of the sac is thin and membranous,

the lower is bounded by a symmetrical mass of tissue which microscopically consists of neuroglia supporting large nerve-cells. (Natural size.)

FIG. 12.—The embryoma in a second cyst of the same ovary (2371, St. Thomas's Hospital Museum. Natural size). A bristle is placed beneath a strap-like process prolonged from the chief mass composing the teratoma.

FIG. 13.—A vertical section of the preceding. In the midst of the tissue will be seen a minute circular structure which represents a central nervous system, as told by its consisting of neuroglia supporting large branching nerve-cells. (Natural size.)

TABULA X,

Ad dissertationem "De Embryomate quodam acephalo Ovarii" illustrandam.

S. G. Shattock. (P. 267.)

FIGURA 1.—Embryoma sive teratoma in ovarii cystem projectum. Membris inferioribus duobus, sed inequaliter evolutis, præditum est. Extremitas embryomatis cephalica repraesentatur ossis processu dentigerenti cujus ex cute excrescunt crines.

FIGURA 2.—Embryomatis ejusdem sectio. Monstratur intestinum in cavum abdominale projectum, intra telæ adiposæ molem ex quâ embryomatis truncus constat.

FIGURA 3.—Teratoma in cyste aliâ ovarii ejusdem projectum. Ex embryomate, rudissime evoluto, protruditur membrum minutum in quo cartilaginis processus continetur. In ovario eodem teratoma tertium in cyste tertiâ projicitur.

FIGURA 4.—Unum e membris inferioribus rude evolutis, cum pelve conjunctum, ut apparet in "Ophisaurus apus."

FIGURA 5.—Unum e membris inferioribus rude evolutis, cum pelve conjunctum, ut apparet in "Python sebæ."

FIGURA 6.—Embryoma simpliciter conformatum quod in ovarii cyste projicitur. Parasiti e cute, in loco quodam, crines, in longitudinem 18 centimetra excrescunt.

FIGURA 7.—Teratomatis præcedentis sectio. E telâ constat adiposâ cute piliferenti indutâ; in illâ monstrantur processus ossis minutus, et cavum quod intestinum repræsentat.

FIGURA 8.—Embryomatis in ovarii cyste projecti sectio. In telâ adiposâ ex quâ teratoma constat, systema includitur nervosum centrale. Scrutatio microscopica hoc constare probat ex neuroglia in quâ cellulæ magnæ nervosæ sustinentur.

FIGURA 9.—Embryoma tubulare in ovarii cyste projectum. In parte dextrâ embryoma crinibus atque stomodæo (in quo seta infigitur) præditum est.

FIGURA 10.—Embryomatis præcedentis stomodæum supra conspectum.

FIGURA 11.—Ejusdem embryomatis sectio transversa. Structura tubularis, cute circumtecta, ex systemate nervoso centrali constat, canalis cujus abnormiter dilatata est, ut in hydrocephalo aut hydromyelo.

FIGURA 12.—Embryoma aliud in cyste aliâ ovarii ejusdem projectum.

FIGURA 13.—Embryomatis præcedentis sectio. In medio ipso discerni potest sectio systematis nervosi centralis.

Figuræ ad magnitudinem naturalem delineatæ sunt omnes.

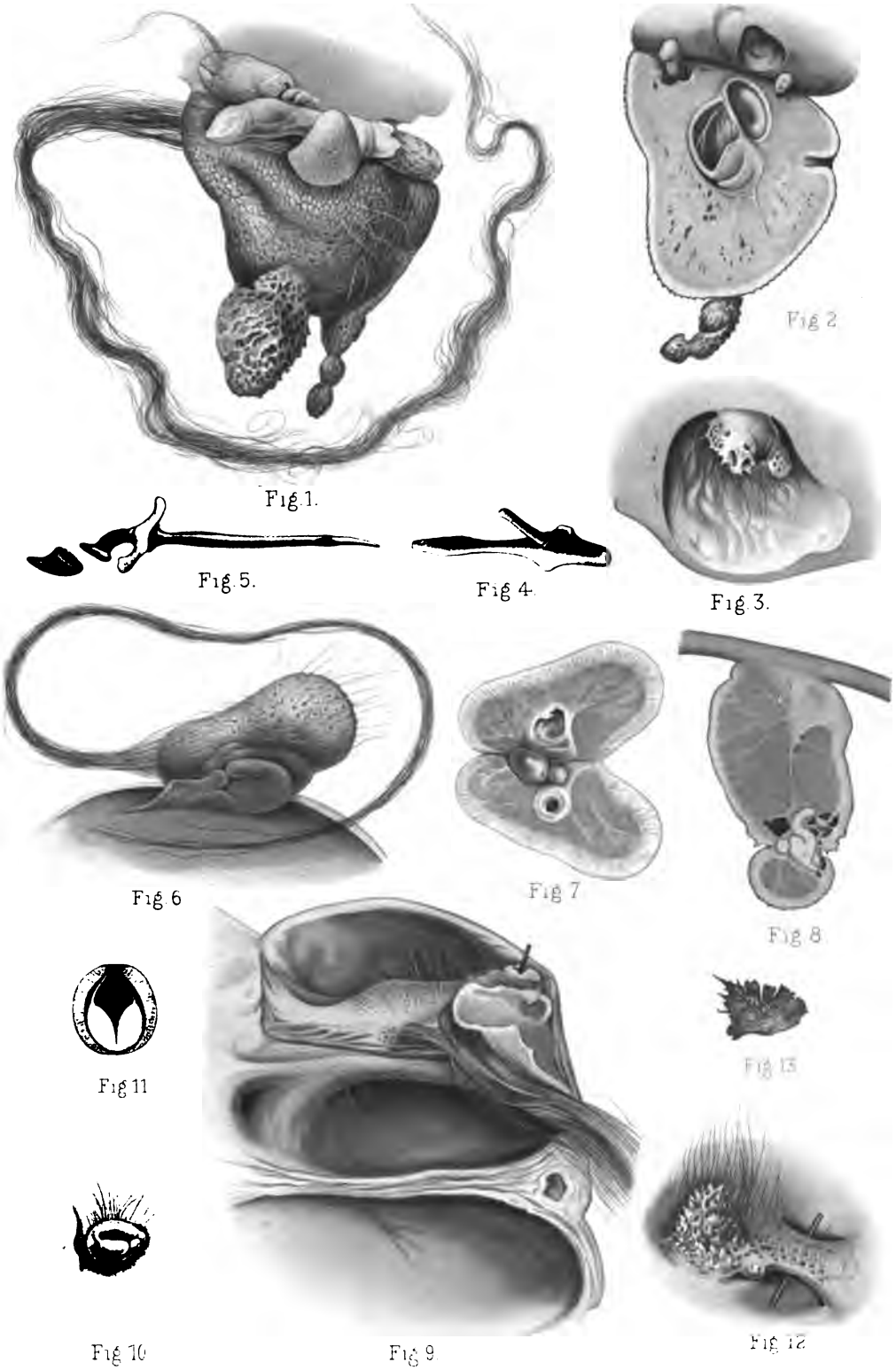
Fig. 1.
Fig. 2
Fig. 3.
Fig. 4.
Fig. 5.
Fig 6
Fig 7
Fig 8
Fig 9.
Fig 10
Fig 11
Fig 12
Fig 13

TABULA XI,

Ad dissertationem "De Embryomate quodam acephalo Ovarii" illustrandam.

S. G. Shattock. (P. 267.)

FIGURA 1.—Monstratur systema nervosum centrale embryomatis in figurâ 13 tabulæ præcedentis depicti.

FIGURA 2.—Embryomatis ejusdem sectio microscopica pilos monstrans unâ cum glandulis sebaceis et sudoriferentibus.

FIGURA 3.—Systematis nervosi centralis margo, et nervus infrajacens cellulis permultis nervosis præditus.

FIGURA 4.—Una e cellulis nervosis, corpora Nissl, nucleum nucleolumque monstrans.

FIGURA 5.—Monstratur cellula nervosa in neurogliâ sustenta in substantiâ nervosâ centrali in figurâ 1 delineatâ.

FIGURA 6.—Glandulæ sudoriferentis portio ab extra conspecta, cellulas longas musculares monstrans.

FIGURA 7.—Glandulæ sudoriferentis sectio; monstrantur cellulæ epithelii atque cellularum muscularium circumjacentium sectiones.

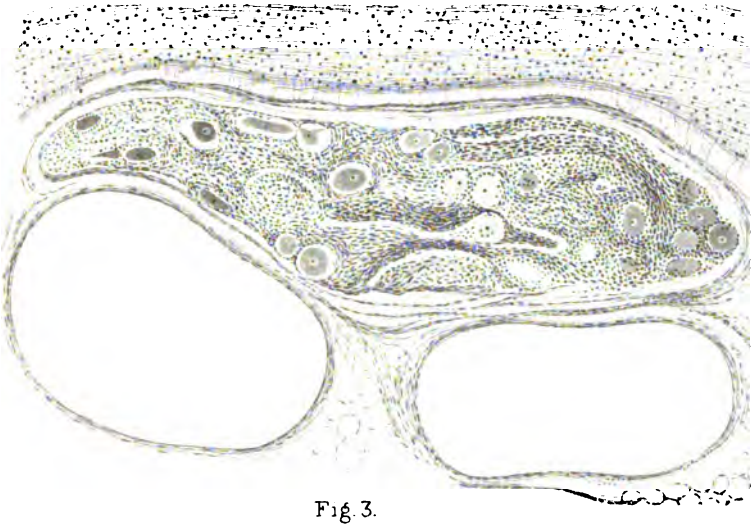

Fig. 3.



Fig 4.

Fig 6.



Fig. 5.



Fig. 7.

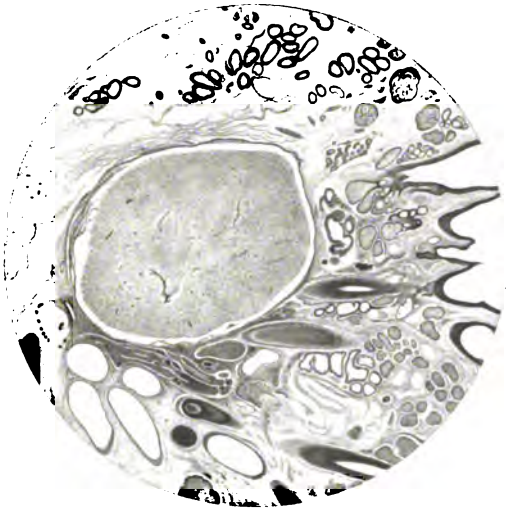

Fig 1.

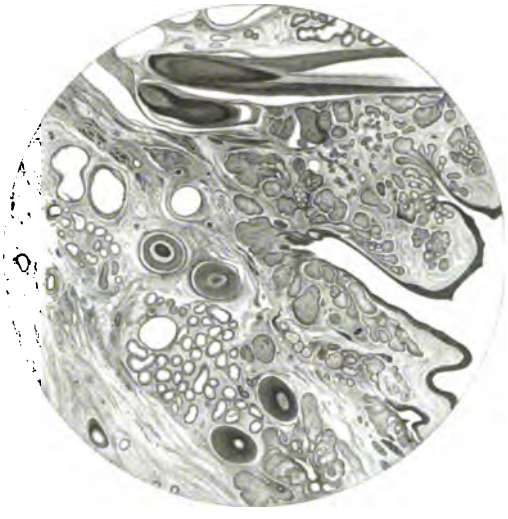

Fig. 2.

developed mucosa, its epithelium corresponding in character with that of the hypoblast of the area pellucida, which later gives rise to the intestinal epithelium.

Histological examination of the wall of the cyst into which the parasite projects reveals a complete absence of epidermis and epidermal appendages. The wall itself consists of wavy fibrous tissue, the innermost lamina of which is differentiated by reason of a greater closeness and less wavy condition of fibre; this is lined with a distinct single layer of extremely flattened epithelial cells. No giant cells were found in the substance of the cyst-wall. The only piliferous area of the cyst (as distinguished from the parasite) is a minute circular patch about 5 mm. in diameter, at a spot almost opposite to the teratoma; this area is of a pale brownish colour and bears three or four hairs.

In the remains of the ovary at a site opposite to the Fallopian tube there has grown a hemispherical fibroma about an inch and a quarter in diameter.

The cyst was removed from a Polish-Jewess, aged 37 years, who had borne two children.

It is noteworthy that whilst the hair of the teratoma and the mass shed into the cyst is flaxen or yellow, the hair of the patient and that of her husband (a Polish-Jew) are quite black.[1]

The theoretical significance of this striking difference in colour I will discuss later.[2]

Let me here refer to a certain difficulty which arises in the

[1] I have preserved a sample of the patient's hair in the College preparation No. 4526G.

[2] That the anatomical existence of the lower form of teratomatous eminence in ovarian cysts was not unknown to Morgagni will appear from the following quotation ("De sedibus et causis morborum per Anatomen indagatis," Liber iii, 'De Morbis Ventris,' epist. 39, art. 41, 1761). Concerning a subject examined by Manfredi, he writes: "Huic enim connatum fuisse, ad me scripsit, globum prægrandis ovi magnitudine, comprehensum alba et quasi cartilaginea tunicâ, quibusdam tamen locis tenuiore et nigricante: intra eum globum, delituisse pilorum glomerem, ab ea tunicâ omnino sejunctum, et quodam quasi sebo delibutum: *intra glomerem autem nucleum quendam, ex quo vasa aliquot in continuatam testis substantiam pertinebant.*" The nucleus in the middle of the ball of hair, from which vessels passed into the continuous substance of the ovary, is obviously a piliferous teratoma, the hair itself being everywhere unattached to the proper wall of the cyst. In regard to the word "testis" it must be observed that the ovary is, in Morgagni's work, spoken of as the female testis, and that it is so used in the above citation.

occasional presence of piliferous skin in more than one spot in the cyst, such as occurs in Spec. No. 4526E, already detailed, where, in addition to the projecting piliferous teratoma, there is a small unraised patch (5 mm. in diameter) bearing three or four hairs, at a spot almost opposite to the teratoma; the wall of the cyst in general is lined with a single layer of flat epithelium.

There is firstly, then, the possibility of epithelial transplantation from the parasite to another part of the cyst. Epithelium might be transplanted from the teratoma at an early stage in the development of the latter, the implanted epiblastic cells subsequently developing the cutaneous appendages of hairs and glands.

When we recall the fact, moreover, that epithelial grafts may be started upon a granulating surface by means of transplanted hairs (*i.e.* of course, through the root-sheath adhering to the hair) as well as by means of portions of the fully-grown epidermis, and remember the extensive shedding of hair so common in dermoid cysts, the possibility of shed hair becoming attached to other parts of the cyst will not appear unreasonable.

There is, morever, a spurious attachment of hair which has been shed into the cyst, that must not be mistaken for an original growth. This spurious attachment I have seen in the case of a teratomatous cyst or "dermoid" of the testicle.

The inner surface of this cyst (which is again referred to later in the communication), excluding the proper, skin-covered dentigerous teratoma, consists of granulation-tissue in which a certain number of hairs are embedded, the granulation-tissue having grown up about hairs which have been shed, for the latter are not furnished with any trace of follicle, but lie simply embedded for a certain distance in the new tissue.

The engagement of shed hair in granulation-tissue has been described in the case of "ovarian dermoids" by Dr. Herbert Williamson ('Obstet. Soc. Trans.,' vol. xlvi, 1905).

Another process clearly traceable in some cysts is that by which the progressive distension of the sac stretches the peripheral part of the piliferous skin pertaining to the teratoma, so that we may find the interior of the cyst lined by piliferous skin, or skin which presents the patulous apertures of enlarged

and empty follicles, for a varying distance around the teratoma itself. The results of such distension are naturally more marked the larger the cyst, and may reveal themselves in a wide separation or dislocation of the teratomatous elements.

Spec. No. 4513, Museum Royal College of Surgeons, is an unusually large teratomatous cyst quite eight inches in its chief diameter. From one point there grows a thick mass of hair; at a distance of about four inches from this there project four teeth which are themselves widely disparted.

It need hardly be pointed out that simple patches of calcification of the cyst-wall must be distinguished from the proper osseous elements of the teratoma. For the wall of an ovarian cyst may calcify like that of a thyroid cyst, or like the pleura, pericardium, or tunica vaginalis.

No. 4520, Museum Royal College of Surgeons (a dried ovarian cyst), exhibits, in addition to two projecting irregular plates of bone, which bear teeth, multiple patches of calcified substance of simple flattened form, occupying a considerable area, far away from the proper teratoma, and clearly areas of calcification.

And lastly, the occurrence of twin or triple teratomata in a *single* cyst is a possibility not to be ignored or lost sight of in explanation of more than one piliferous area or eminence.

The astonishing excess of teeth, in rare cases met with in a teratomatous cyst, is perhaps explained by such a supposition. Or, it may be that the excess is brought about by an abnormal extension of the epithelial surface corresponding with that of the gum during the early enlargement of the cyst, so that the enamel germs are broken up or subdivided, and give rise to as many teeth or ill-formed denticles.

For even if we allow that two complete sets of teeth, a first and second, have been produced, the total (20 + 32) would not equal the numbers which have been encountered, which may be over a hundred.[1]

One must not, of course, fall into the error of reckoning multiple dentigerous cysts in the same ovary as a single

[1] That some such teeth are "permanent" is clear from their size. Thus, in Spec. No. 4523, amongst several milk teeth there is a unicuspidate tooth 6 mm. in length with the fang still incomplete, widely open, and measuring 5 mm. across the incompleted end.

"dermoid," and must also recognise the possibility of such coming to communicate through their partitions so as to produce a single multilocular cavity.

Not only does the ovarian teratoma present a likeness to the appendages which represent a parasitic individual, or the results of a parasitic dichotomy, but it is comparable, moreover, with some of the forms which obtain in the misdevelopment of a second distinct person, or twin. This will be apparent if we take the acardiac acephalous monster representing an homologous twin, the second twin being in such circumstances normally developed. The acardiac twin may be microcephalic, or provided with an ill-formed cranium, but usually it is acephalous, the head and thorax being absent.

Externally such a twin may be little more than a spheroidal skin-covered mass, the only semblance of which to human form may lie in its possession of one or of two imperfectly developed lower extremities; or these may be conjoined as in syreniform monsters; and associated with the presence of such lower extremities there may be one or two shorter upper limbs. (Nos. 8, 9, 12, 13, 14, Teratological Series, Mus. Coll. Surgeons; 2637 Mus. St. Thomas's Hospital.)

On dissection, such a monster, the chief bulk of which consists of œdematous connective tissue or fat, may exhibit viscera in the most varying grades of development. There may be, for the most part ill-developed, lung, stomach, intestine, kidneys, bladder, uterus and ovaries, testes; and representing skeletal structures, a rudimentary spine (with spinal cord), and osseous elements in the ill-formed limbs. In microcephalic acardiacs certain of the cranial bones may admit of recognition.

Or the acardiac twin may be acormous, *i. e.* trunkless, consisting of the head alone, or the head and a very defective trunk.

This is the condition commonly presented by the ovarian teratoma in which the structures recognisable, besides the skin, consist of ill-defined pieces of bone in which teeth are implanted.

Or lastly, the twin may be reduced to a shapeless mass of connective tissue covered by skin, in which there may or may not be traces of an alimentary cavity, the whole well meriting the name which has been applied to such of "fœtus amorphus."

And this is the condition presented by the lowest grades of the ovarian teratoma.

Not one of the least strange things in connection with ovarian teratomata is that though themselves so abnormal they may nevertheless be the seats of disease. Setting aside the different degrees of aplasia and hypoplasia which, *ipso facto*, they illustrate, or the misdevelopment of particular teeth, or the presence of odontomata upon their fangs, we must look upon the relative amount of fat as, in some cases, quite reaching the proportion of disease.

It is not simply subcutaneous fat duly proportionate to the skin over it, but it may constitute the bulk of the embryoma, the amount of bone and other structures being relatively insignificant as in the case described in the present communication, or in others already referred to from the College Museum (Nos. 4511, 4511A, 4526E).

The morbid condition, in short, is that of lipomatosis, or a generalised abnormal formation of fat, as distinguished from a local tumour or lipoma. For it must be borne in mind that the presence of any fat in the ovary itself is something altogether as abnormal as it is in the testicle, and that the fat of the embryoma appertains entirely to the latter. I am not aware of a fatty tumour ever having been observed in the ovary. Neither the whole of the vast experience of Rokitanski nor that of Virchow furnishes an example of lipoma of the ovary, or, it may be added, of the testicle. In the testicle I have examined one only, and this in the horse; and so far as my knowledge goes it is unique. The specimen is in the College museum, and I have thus described it in the catalogue:

No. **4217A**. "A vertical section of the undescended testicle of a horse, removed during life.

"In its substance, anteriorly, immediately beneath the tunica albuginea, there has grown what microscopical examination proves to be a pure lipoma, about an inch in diameter."[1]

But that hydromyelus should occur is still more strange. Yet it is shown in three of the teratomata already described, in Spec. No. 2371 from St. Thomas's Hospital Museum. In one of these the tubular hydromyelic sac is lined with columnar epithelium, and the halves of the spinal cord lie one on either

[1] Some may be inclined to view even this tumour as representing a teratoma.

side of it, the whole being invested with a separable membrano-cutaneous covering or body-wall.

As there is no spinal column we cannot speak, of course, of a spina bifida.

The largest example of this morbid condition of the embryoma is contained within an ovarian cyst in the opposite ovary of the same patient. It consists of a double sac, the portions of which, each about 3½ inches in length, lie side by side, and communicate by a small aperture half surrounded by a process of bone. From the inner aspect of the sac a delicate continuous membrane can be raised; there is no trace of further structure.

Yet that this bilocular sac is an embryoma dilated into a great cyst by hydromyelic and hydrocephalic distension is clear if it be compared with that first referred to in which the halves of a spinal cord lie on the sides of the sac; and by the circumstance that the sac itself presents a delicate, separable lining representing the meninges of the dilated central nervous system, and an outer membrano-cutaneous body-wall.

We may, indeed, classify the last as a new form of cyst and add it to the heterogeneous category of such without violence, for it is as simple in structure, though not in its origin, as a cyst, say, of the urachus. It is a cyst produced from an embryo, and I venture to name it an *embryonal cyst.*

And such teratomata may become the seats of malignant disease. We may be sure that the localised epithelioma or squamous-celled carcinoma encountered at times in an ovarian cyst has arisen in the cutaneous covering of a teratoma.

In the catalogue of St. Thomas's Hospital Museum I have described such a specimen (No. 2376 A)—an oval cyst, 5 by 3 in. in its chief diameter. One end is capped with a concavo-convex new growth, 2½ in. in diameter and 1 in. in extreme thickness. Over its centre the outer surface is rough in consequence of its having been detached from the bladder to which it was adherent.

Histologically the growth is a squamous-celled carcinoma, the cells of which are in places undergoing keratinisation.

The cyst was removed by Dr. Cullingworth, May, 1899, from a woman, aged 60 years, a widow, who had felt pain in the side for four months and noticed a swelling for six weeks. The cyst was adherent to the abdominal wall, bladder, and omentum.

The bladder was not perforated, and, as found after death, the vesical mucosa was everywhere intact, proving that the carcinoma arose not from the bladder but the interior of the cyst.

The cavity contained a yellow, fatty substance with intermingled hair. Death took place on June 2nd from intestinal obstruction, due apparently to adhesions and kinking or twisting of the gut, part of which was collapsed and empty, and above this distended. No metastasis was discovered in the abdomen or lymphatic glands.

But more frequently the tumour arising from the teratoma is of a mixed kind; all the histological elements of the teratoma, seeing that they are all embryonic residua, may partake in the abnormal overgrowth, and the resulting tumour may be simple, or malignant producing metastasis.

Mr. H. T. Hicks and Mr. J. H. Targett have published two cases of malignant embryoma of the ovary, one of the patients being but 6 years of age.[1]

And a case of yet younger age is recounted by Mr. L. S. Dudgeon,[2] where a huge tumour of this kind filled the abdomen of a child under four years old.

In some of the similar cases reported cerebral tissue has been found in the tumour.

The Pathogenesis of the Ovarian Teratomatous Cyst.

To return now to the theories which have at different times been advanced in explanation of the so-called ovarian dermoid.

With that which refers it to epiblastic sequestration I have already dealt in the early part of this communication; assuming it to be anatomically applicable it would not account for the presence of any structures other than skin in such cysts.

One, which has been long held, is that such cysts result from an impregnation which has been relatively abortive and incomplete in result. As a sufficient refutation of this view it can be pointed out that these cysts may be met with in the unmarried and in children, and this objection has not yet been met.

We often find it recorded that a patient from whom such a teratomatous cyst was taken, was unmarried. Yet such a history of itself is scientifically inconclusive in this regard.

[1] 'Journal of Obstetrics and Gynæcology of the British Empire,' August, 1905.
[2] *Ibid*, January, 1906.

And then we come aross one of those decisive but simple observations of Hunter, which forces us to believe that he saw its importance for the simple reason that he made it.

In the case of the Hunterian specimen (No. 4508 in the College Museum), we find it recorded that the hymen was intact. The cyst was taken from a woman, aged 18 years, and from its otherwise smooth interior there projects an embryoma covered with piliferous skin and bearing a tooth. The same integrity of hymen is recorded of a later specimen, No. 4519, which consists of a piece of dentigerous bone from an ovarian cyst taken from an unmarried woman, aged 27 years.

And as regards the presence of such cysts in children, No. 4514 is a thin-walled ovarian cyst bearing a small piliferous teratoma which contains cartilage, the parts being removed from a girl, aged 8 years.

It is clear, moreover, that in the case of the teratomatous or so-called dermoid cyst of the testicle, the swelling has, in some instances, been observed from the time of birth, as in a specimen lately added to the College Museum (No. 4225 B), to which I will refer in detail later; and that a post-natal impregnation of the testicle, in any case, reduces the theory to an absurdity.

The view usually adopted in regard to the ovarian teratoma is that the latter is due to the impaction of a second individual which has started on its development synchronously with its host, but which has subsequently failed in its progress.

One excellent example of what is commonly regarded as the intra-abdominal impaction of an abortive second individual has come under my own observation. I have thus described it in the Pathological Catalogue of St. Thomas's Hospital Museum.

No. **2635**. "Vertical sections of a diminutive parasitic fœtus which was found within the abdomen of a *male* child, aged 11 months. It lay in front of the first and second lumbar vertebræ with the pancreas stretched over its anterior surface. As seen in the section the parasite possesses a short spinal column and vertebral canal, surrounded by a series of cartilaginous and osseous elements which possibly represent a basis cranii. In front of the spine is a closed cavity corresponding with the primitive intestine, and on every side of the former is a thick accumulation of adipose tissue invested with a thin integument which was encased with vernix caseosa. On removing the last-

named, ill-formed upper and lower limbs, misshapen from compression, were disclosed. Behind the divided spine are the cut surfaces of cartilaginous and osseous elements pertaining to the pelvic girdle and lower limbs."

There are two specimens of the same class in the Museum of the College, viz. Nos. 173 and 175.

In one of these the fœtus, which was encysted within the abdomen of a well-formed *male* child between nine and ten months old, is devoid of head; its trunk possesses four misshapen limbs.

In the second the ill-developed fœtus also lay in a cyst of the abdomen of a *boy* between fifteen and sixteen years of age. It has no head, but some slips of membrane unite the upper part of the vertebral column with a funis; they represent the membranes of the brain.

A quantity of long, thick, matted hair is seen growing from near the same point, probably from what should have been the frontal region.

"The limbs are very ill-proportioned and strongly flexed."

In such cases of fœtal inclusion the included embryo is assumed to be an homologous twin.

As Lowne remarks (Teratological Catalogue, Royal College of Surgeons, p. 51), it is not easy to understand how a second ovum could enter the body cavity of an embryo, whilst there is no difficulty in understanding how a second embryo on a common yolk could be so included.

The chief argument against the theory of a twin impaction in explanation of the ovarian embryoma is the sheer commonness of the latter; partly this, and partly the difficulty of understanding why such an impaction should so regularly take place into the substance of the ovary, and why being so common in the ovary it should be of such excessive rarity in the testicle, seeing that these organs occupy the same primitive position and are, in fact, at first indistinguishable from one another.

The occurrence, again, of a teratomatous cyst in each ovary adds to the difficulty of accepting this explanation.

This bilateralism is, indeed, very far from rare.[1]

The presence of two or even three teratomatous cysts in the

[1] No. 4031 B, University College Museum, showing both ovaries; and Nos. 4032 and 4036, showing the ovaries (mounted separately) from the same patient; No. 2371, St. Thomas's Hospital Museum, etc.

same ovary accentuates the difficulty, for it would involve the impaction of as many embryoes.

In the College Museum Spec. No. 4511 shows three such in one ovary; No. 2371, St. Thomas's Hospital, shows three such in one ovary, and a further teratomatous cyst in the opposite gland.

In a case recorded by F. Hue in 'La Revue Médicale de Normandie,' July 25th, 1904, a "dermoid cyst" was found in each ovary of each of two sisters.

A further difficulty in regard to the theory of impaction arises from the discrepancies referable to the colour of the hair in such cysts. In multiple teratomatous cysts of the same ovary the hair may be of different colour.

In Specimen 2371 (St. Thomas's Hospital Museum) there are three quite distinct teratomatous cysts in one ovary. These have already been fully described in the earlier part of this communication; each cyst bears a teratoma. In one of the cysts the hair growing from the teratoma comprises a thick tress seven inches in length of flaxen colour, and the shorter hairs on the eminence are of the same, but that growing from the keratoma in one of the other cysts is all of a dark brown.

In bilateral "dermoids," too, the hair may be of different colours; it has been found dark in one cyst, and light in the other.[1]

The colour of the hair in the "dermoid" again may be markedly different from that of the patient. In the case described in the present communication, the hair of the teratoma, which consists of a tuft growing from the pubes, the parasite being acephalous and devoid of teeth, is of the palest flaxen, whilst that of the patient is of a well-pronounced or medium brown, although, as is so regularly the case, it had darkened since infancy; it is fair, however, to contrast the two, for the growth of the pubic hair in the parasite must be regarded as synchronous with the puberty and not with the infancy of the patient.[2] A more striking instance of this difference is afforded by the specimen presented to the Royal College of Surgeons by Dr. F. J. McCann and already referred to (2526 E).

In this the cyst is filled with a mass of shed hair, the colour of which is flaxen or light yellow; hair of similar colour grows

[1] Mr. C. J. Bond, 'British Medical Journal,' February 10th, 1906.

[2] The hair of the patient's father was black; I have preserved samples in the College Museum, No. 4526 E.

from the teratoma. In this case the hair of the patient and that of her husband are of a full black.

Such facts go towards showing, in the first place, that the piliferous skin of the "ovarian dermoid" has not the same histological origin as the skin of the patient, *i. e.* that its pertaining epidermis is not a portion of the general and primitive epiblast.

In the second place they go towards showing that the embryoma is not an impacted homologous twin. For such twins (which arise from a single ovum, are formed on a single blastodermic vesicle, and enclosed within a single amniotic sac) are not only of the same sex, but so alike in detail as to be with difficulty or not at all distinguishable.[1]

This, too, is true of double monsters, which have the same kind of origin as homologous twins, from the misdevelopment of which they arise. For the colour of the hair is, I find, invariably the same upon the two heads. Were the ovarian embryoma due to the impaction of an homologous twin its hair should be of the same colour as that of the patient; and in the case of multiple embryomata it should, moreover, be of the same colour in all.

The Author's Theory of Epiembryogenesis.

The foregoing considerations lead me to propose a theory which may explain both the frequency of the ovarian embryomatous cyst and its particular location, a theory, moreover, with which the occurrence of embryomatous cysts in the testicle is not incompatible, and which at the same time is in harmony with their rarity.

This theory is that the ovarian teratoma results from the fertilisation of one of the primordial ova in the ovary of the embryo, so that the embryo gives rise to a second imperfect individual whose origin is therefore not synchronous with, but of later date than, itself. It is the formation of one embryo within another, and the name I venture to suggest for the theory is that of "epiembryogenesis." The term "epigenesis" would be less cumbersome, but it has already been devised and used in a different sense.

It may be helpful to recall the facts that the primordial ova,

[1] So far as sex and the colour of the hair alone are concerned, the converse does not, of course, hold true. The colour of the hair *may* be alike in heterologous twins, and this whether the sexes are the same or different.

which are formed at quite an early stage of embryonic development, arise on the inner surface of the abdominal cavity, amongst and out of the cells of the germinal epithelium, the accumulation of which constitutes the genital ridge. These larger and more spherical cells occur in both sexes, and are named primordial ova, although their destiny differs in the two sexes; in the male they normally give rise to the spermatogenic cells of the testicle. At this early stage sex is undifferentiated. Later the primordial ova in the female become carried from the surface into the ovarian stroma by the ingrowths of epithelium known as the egg-tubes of Pflüger, the latter cells producing the epithelial investment of the ovum, or epithelial lining of the Graafian follicle. It is believed that most, if not all, of the proper ova are produced in the human subject long before birth.[1] In considering the possibility of a fertilisation of primordial ova, the rapidity with which the formation of such proceeds must be appreciated. What the time in the human embryo is is not precisely determined, and it, of course, would not be so rapid in man as in the rabbit, or in the fowl. In the chick at forty-five hours, the spinal cord is already tubular, and the pleuro-peritoneal cavity or cœlom has appeared: following quite rapidly upon the formation of the cœlom is the appearance of the genital ridge which results from a localised proliferation of the cells lining the body-wall, and in this germinal epithelium the primordial ova are actually found differentiated by the fourth day.

In the next place, with respect to the access of the spermatozoa to the primitive ova, it is not necessary to suppose that a second penetration of the developing "ovum" takes place.

It is well known that more than a single spermatozoon may perforate the investing membrane of the ovum; in the rabbit multiple spermatozoa have been observed in the perivitelline space, *i.e.* between the membrane and the cytoplasm of the ovum.

In the dog-fish and certain reptiles the ovum is regularly penetrated by many spermatozoa, only one of which fertilises it

[1] In the rabbit Miss J. E. Lane-Claypon thinks there is evidence (from a study of histological sections) that besides this, interstitial cells, derived from germinal epithelium like the ova, pass through the nuclear transformations of ovogenesis and become true ova during pregnancy ('Proceedings of the Royal Society,' June 16th, 1905).

(polyspermia); the surplus elements go into the yolk, multiply (with half the somatic number of chromosomes), and become yolk-cells. It becomes thus quite conceivable that surplus spermatozoa may remain about the segmenting mass or morula, may become engaged between its component cells, and in this way be actually ready in the blastoderm to fertilise the primordial ova which are developed soon after its lamination and the cleavage of the mesoblast which results in the formation of the body-cavity.

The longevity of spermatozoa when under conditions not adverse to their life is a subject upon which little is known.

The observation that the leucocytes of the rabbit will remain alive in oxalate plasma *in vitro* for six weeks is not one from which any direct application could be safely made.

In the queen bee the sperm is retained in the living state in special sacs. After the exhaustion of these the queen lays unfertilised eggs, from which the drones are developed.

More to the point, however, is the fact, well known to poultry-keepers, that after a single impregnation the hen of the turkey will lay her whole brood, that is, will lay the entire succession of fertile eggs, about twelve in number, which makes the brood, one egg being laid about every other day, and the whole process extending over a period of about four weeks. It is, in fact, a common practice to take the male from farm to farm for the purpose of impregnating the hens.

Mr. W. B. Tegetmeier has told me that he knew of one instance in the common fowl in which fertile eggs were laid and hatched six weeks after the access of the cock bird.

Not only does this theory of an epifecundation of primordial ova in the ovary of the embryo explain the frequency and particular location of embryomatous cysts of the ovary, but it explains the multiplicity of such cysts in the same ovary, and their occurrence in both the ovaries of the same patient.

The theory, again, will account for the difference in colour of the hair in multiple teratomatous cysts, or of the teratomata in cysts of opposite ovaries.

For such differences become examples only of the differences in colour so frequently seen in children born of the same parents, or still more closely, in heterologous twins whose hair may be of different colour.

Nor does the difference in colour between the hair of the embryoma and that of the patient offer any difficulty.

The patient is, whilst yet an embryo, the mother of the teratoma; the father of the teratoma is the father of the patient.

The colour of the hair of the embryoma need not, therefore, resemble that of the patient, the mother; it might resemble that of the father, or it might not resemble either, but that of a more remote ancestor.

Amongst zoologists three methods of embryogenesis are recognised in addition to the common one in which the ovum, previously and independently matured by the extrusion of its polar globules, is fertilised by a spermatozoon.

(1) *Shock-fertilisation.*—This involves the preliminary, independent maturation of the ovum, but the incentive to the subsequent division of the latter and the development of the embryo is mechanical. The ova of the star-fish, as is now universally known, can be "fertilised" by means of "soda-water" added to the sea-water of the aquarium, or by mere shaking.

(2) *Parthenogenesis,* which takes place in many of the Insecta (Aphis, and particularly the bee), involves a maturation of the ovum, but not a proper fertilisation, the embryogenesis being started by the return, or want of extrusion, of the second polar globule which acts in place of the male element.

(3) *Sporogeny.*—Here the embryo develops from the ovum without any preliminary maturation of the latter, and apart from fertilisation. This phenomenon has been observed in the jelly-fish.

The theory of epiembryogenesis in connection with ovarian embryomata involves (as would also that of parthenogenesis) a premature preliminary "maturation" of the ovum, seeing that the process of fertilisation would take place in the embryo itself.

The phenomenon of parthenogenesis, however, is limited to forms so far below mammals that it is difficult to think it obtains with such great frequency in the human subject as the common occurrence of ovarian teratomata would necessitate.

Still more inapplicable is the phenomenon of sporogeny, the only one which does not involve an histological "maturation" of the ovum, when the extreme lowness of the forms in which it occurs is considered.

Amongst certain Diptera (in several species of the genera Miastor and Oligarces) a remarkable phenomenon occurs in which larvæ are produced directly from the larval form of the insect. This phenomenon, which has been named Pædogenesis, is shortly described thus [1]: a female lays a few very large eggs, out of each of which comes a larva that does not go on to the perfect state, but produces in its interior young larvæ that, after consuming the interior of the body of the perfect larva, escape by making a hole in the skin. It was at one time thought that such larvæ were produced from the rudimental or immature ovaries of the parent larva, but it is now alleged that their source is from "germs" in connection with the substance known as the "fat-body."

It may be said that the theory of epiembryogenesis not only involves a premature histological maturation of the ovum, but the persistence in a potentially functional condition of surplus spermatozoa.

Yet we have to bear in mind how monstrous are the anatomical facts presented by the ovarian embryoma; and monstrous results imply an equally monstrous causation.

The so-called "Dermoid Cyst" of the Testicle.

Let me, in conclusion, refer to the difficulty presented by the occurrence of similar embryomatous cysts in the testicle. The examples of such that fall under individual observation are few indeed. The only one I have ever seen, and the only one in the College Museum, is that recently presented by Mr. Bland-Sutton, who had previously very briefly referred to it in the first volume of the 'Archives of the Middlesex Hospital,' and this example came from China. Mr. Bland-Sutton's notice of this valuable specimen is wanting in certain particulars, which I may fill in from a further examination.

For in connection with such cysts, we have carefully to differentiate dermoids of the scrotum from those of the testicle. The former are of the common sequestration kind, like those that have been observed in the perineum.

The specimen in question (No. 4225 B) is the testicle of a boy, enlarged so as to measure two and a quarter inches in its chief

[1] 'The Cambridge Natural History; Insects,' part ii, p. 460.

diameter, by the growth of a teratomatous cyst. Projecting into the cyst is an irregularly lobulated process about an inch and a half in its larger axis, from one pole of which there protrudes the crown of a multicuspidate tooth. Over one area the surface of the process is coarsely papillary, and bears a certain number of black hairs. At the upper part of the section the tunica albuginea is traceable for some distance over the wall of the cyst. By dissection I was able to reflect a tunica vaginalis and to expose a flattened body which microscopic examination

FIG. 35.

A vertical section of a teratomatous, or so-called dermoid cyst, of the testicle, showing a tooth and hair projecting from a prominent teratoma within the cavity. Microscopic examination discloses the presence of a thin layer of testicular tissue on the exterior of the wall of the cyst. Spec. No. 4225 B, Mus. Coll. Surgeons. (Natural size.)

EXPLICATIO FIGURÆ.

Cystis dermoidis testiculi sectio, dentem atque pilos in teratomate infixos monstrans. Scrutatio microscopica laminam telæ testiculi cystem circumtegere probat. Magnitudinis naturalis.

proved to be the epididymis. A microscopic study of the wall of the cyst in two different situations further revealed the presence of a thin layer of well-developed testicular tubuli lying beyond the dense fibrous tissue composing the chief thickness of the cyst-wall.

From a blind boy, aged 16 years. There was a history of the enlargement having been congenital. He had suffered from frequent inflammatory attacks of the scrotum following injury, such as crushes against a stool, etc. At the operation the right testicle was found to be small, but normal in position.

The skin over the front of the left testicle was reddened, and a sinus was present at the junction of the scrotum and penis. The left testicle appeared as an elastic globular mass, no distinction being palpable between the body of the testis and the epididymis.

In the course of the operation some pus escaped from beneath the reddened skin. The sinus and adherent skin associated with it were excised; the testicle was removed entire. Recovery was uninterrupted.

When cut through in the recent state, the cyst was found to be filled with fat and hair.

The operation was carried out by Dr. Booth, Hankow, Central China, the patient having been an inmate of the blind school there for nine years.

How is the occasional occurrence of such cysts in the testicle to be accounted for on the theory advanced?

In the embryonic sexual gland, whether of man or other forms, the proper reproductive cells are at first undifferentiated from one another. These cells (the primordial ova erroneously so-called) become subsequently in the female the true ova, and in the male, the spermatogenic elements of the testicle.

The occurrence of embryomatous cysts of the testicle, then, would involve, on the theory of epiembryogenesis,an hermaphrodite condition of the gland in which the cyst is formed, and the intra-embryonic fertilisation of one of the proper ova. True it is that in the human subject the condition of glandular hermaphroditism is but rarely observed, but quite as rare is the teratomatous cyst of the testicle. The rarity of the one accords with the rarity of the other. Yet on the theory of fœtal impaction the teratomatous cyst of the testicle should be as common as that of the

ovary, seeing that the anatomical position of the two glands themselves is the same.

We are apt to regard hermaphroditism in man as something altogether monstrous and inexplicable.

Yet the correct manner of viewing it, if, indeed, it be not its explanation, should rather be as an atavistic reversion. Amongst Vertebrata it is the normal condition in certain groups of fish. And sporadic examples of it have been met with in every class above.

In describing an example of true hermaphroditism in the domestic fowl, Dr. Seligmann and I have discussed this subject in its general aspect.[1]

And so far as man is concerned it is fully discussed in the same volume by Mr. T. W. P. Lawrence, who has described an example of a mixed sexual gland or ovotestis in a fœtus.

The wonder, indeed, is that glandular hermaphroditism in the human subject is not more frequent.

For how can we explain the fact that every human embryo is furnished with two sets of sexual passages, Wolffian and Müllerian; that the male, like the female, is furnished with a mammary gland; and the female, like the male, with an intromittent organ?

How can these facts be interpreted unless it be that man is descended through an hermaphroditic ancestry? They point to a primæval community of sex, and a reversion to this is not surprising.

---

25. *The hæmogregarines of snakes.*

By L. W. Sambon and C. G. Seligmann.[2]

(With Plates XII, XIII, XIV, XV.)

Having had the opportunity of examining several new hæmogregarines, chiefly from snakes, it appeared that it might be of interest, possibly of service, to gather all the scattered information concerning hæmogregarines in general and publish a catalogue of the Ophidian hæmogregarines known up to date.

The hæmogregarines belong to a group of the Hæmoprotozoa

[1] 'Path. Soc. Trans.,' vol. lvii.

[2] The first part of this communication is by Dr. Sambon; the second, conjointly by Dr. Sambon and Dr. Seligmann.

(26) of which we have but scanty information. Their systematic position is still uncertain, their life-history very imperfectly known. Yet they are so numerous in species, so frequent in occurrence, so widely distributed both geographically and zoologically, that they must play an important part in the economy of nature. Till quite recently these cell-parasites were believed to be confined to cold-blooded vertebrates, but in 1894 Bentley discovered a hæmogregarine in the dog in Assam, and since then several species have been described from mammals by Patton, Christophers, Balfour, Laveran, and others. It is by no means improbable that they occur in man.

The first hæmogregarine known to science was *Hæmogregarina minima,* a parasite of the edible frog (*Rana esculenta*), described and figured by Chaussat (9) in 1850. Believing it to be a minute nematode, Chaussat named it *Anguillula minima.* In 1871 Ray Lankester (18) also noticed and figured the free sporonts of *H. minima.* He thought they might represent some particular stage in the life-history of *Trypanosoma rotatorium,* and believing the latter to be an undescribed organism proposed to call it *Undulina ranarum.*

In 1880 Gaule (12) described the endocorpuscular forms of the frog hæmogregarine, which he termed *Blutwürmchen.* He declared, however, that they were nothing more nor less than a degeneration product of blood-corpuscles and tissue-cells.

In 1882 Ray Lankester (19) refuted Gaule's theories and again maintained the parasitic nature of *H. minima,* which he proposed to call *Drepanidium ranarum.* At the same time he suggested that the organism might represent the young stage of a sporozoon allied to Sarcocystis or to Coccidium, possibly to the coccidium discovered by Lieberkühn in the kidney of the frog.

The generic name proposed by Lankester could not be retained because it had been used previously by Ehrenberg, in 1861, to denominate a ciliated infusorium. Likewise the specific designation *ranarum* had to be rejected, by law of priority, in favour of *minima,* given by Chaussat in 1850.

The term *Hæmogregarina,* now generally used,[1] is the correct

[1] The term *Drepanidium* is still erroneously used by certain authors. Thus we find it in a paper by Dutton, Todd, and Tobey, "Concerning certain Parasitic Protozoa observed in Africa," published in November, 1907, in the 'Annals of Tropical Medicine and Parasitology.'

generic name. It was proposed by Danilewsky (10) in 1885, to designate similar blood-parasites found by him in the European pond tortoise (*Emys orbicularis*) and in several species of Lizard (*Lacerta agilis, L. muralis, L. viridis, L. ocellata*).[1]

In 1894 Labbé (15) proposed to divide the hæmogregarines then known into three distinct genera based chiefly on the relative proportions of the parasite and its host-cell. His classification is as follows:

(1) *Drepanidium.*—Parasite not more than three fourths the length of the host-cell: *D. princeps* (= *H. minima*), *D. monilis* (= *H. minima*), *D. avium* (the oökinetes of leucocytozoa and hæmoprotei).

(2) *Karyolysus.*—Parasite not exceeding the host-cell in length and exercising a destructive influence on the cell nucleus: *K. lacertarum* (=*H. lacertarum*).

(3) *Danilewskya.*—Parasite exceeding the host-cell in length, and doubled up within it: *D. stepanovi* (=*H. stepanovi*), *D. lacazei* (=*H. lacazei*), *D. Krusei* (= *H. magna*).

Until quite recently, with the substitution of the name *Lankesterella* for *Drepanidium*, and *Hæmogregarina* (*sensu stricto*) for *Danilewskya*, Labbé's classification has been followed by the great majority of authors. Indeed, it is still in a way retained by Lühe in his admirable system of the hæmoprotozoa contributed to Mense's 'Handbuch der Tropenkrankheiten' (1905—1906). Since so many new species have been described, Labbé's classification proves quite inapplicable. Therefore, until we know more about the life-history and development of these organisms they had better be arranged, as suggested by Laveran, according to the different orders of their hosts and under the collective name *Hæmogregarina*.

In the present state of our knowledge it is not possible to state the exact systematic position of the hæmogregarines. With Neveu-Lemaire (28) and Lühe (20) I place them in a separate family—*Hæmogregarinidæ*. They are characterised by a definite club-like form, the presence of a minute retractile projection at the wider anterior extremity, the absence of black pigment, the constant presence of a capsule save in the earliest stages, the doubled-up attitude that most of them assume within their

[1] Danilewsky erroneously included in this genus the oökinetes of leucocytozoa and hæmoprotei, which he proposed to call *Hæmogregarina avium*.

capsules, their oökinetes, so far as we know at present, after encystment producing sporozoites in secondary cysts or spore-bags.

As already stated, Ray Lankester at first believed that *H. minima* might represent a particular stage in the life-history of *Trypanosoma rotatorium*. The connection between hæmogregarines and trypanosomes was again brought forward by Billet (3) in 1904. In examining a number of leeches of the species *Helobdella algira*, which had been sucking the blood of frogs infected with *Hæmogregarina minima*, Billet found in their intestines a trypanosome, *Trypanosoma inopinatum*, and other forms more or less round provided with two nuclear bodies, which he viewed as intermediate between a hæmogregarine and a trypanosome stage. The investigation was somewhat complicated by the presence in the same frogs of another trypanosome —*T. rotatorium*. Some of the frogs had in their blood both hæmogregarines and trypanosomes, whilst others had only the hæmogregarine; nevertheless, the leech in both instances presented trypanosomes. Subsequently Billet placed leeches, whose digestive tube contained *T. inopinatum*, on frogs free from hæmoprotozoa: afterwards he found hæmogregarines only in these frogs. Billet considers the trypanosome phase to be very uncommon in the frog, but of general occurrence in the leech, and, conversely, the hæmogregarine phase to be absent, as such, in the invertebrate host, but common in the vertebrate.

Brumpt, (5) in a short preliminary paper on the development of hæmogregarines and trypanosomes, states that the sporogony of *Hæmogregarina bagensis*, a parasite of the Spanish terrapin (*Clemmys leprosa*), occurs in the œsophagus and stomach diverticula of the leech *Placobdella catenigera*. He describes the oökinetes as provided with two nuclear bodies, a large nucleus of the ordinary type, and a smaller, highly-staining body resembling the centrosome of a trypanosome.

In his paper on "The Hæmatozoa of Marine Teleostei," Lebailly (24) discusses the possible relation between hæmogregarines and trypanosomes. The relation is suggested by the frequent concurrence of both in marine fishes, but against their identity stands the fact that so far[1] hæmogregarines have not been found in fresh-water fishes, notwithstanding

[1] Since the publication of Lebailly's paper Laveran has described a hæmogregarine (*H. lignieresi*) from the eel.

the frequent occurrence of trypanosomes in such. The author points out that he has never seen any blepharoplast in the hæmogregarines that might suggest a flagellate nature. He never found in the blood of the infected fishes any intermediate form between hæmogregarines and trypanosomes. He believes the discrepancy in size between the two kinds of hæmatozoa to be a further argument against the probability of any relation.

Miss M. Robertson (31) fully believes that hæmogregarines have a free trypanosome stage. She describes a blepharoplast in a hæmogregarine found by Dr. Logan Taylor in the blood of an African python from the Gambia, and says: "In the light of Schaudinn's researches into the life-history of *Trypanosoma noctuæ,* and particularly in view of the presence of a well-marked blepharoplast, it is pretty clear that the parasite in question is really the intra-corpuscular stage of a trypanosome, and I propose to call it provisionally *Trypanosoma pythonis.*" She also describes a "centrosome" in the hæmogregarines of the plaice (*Pleuronectes platessa*) and of the common flounder (*P. flesus*). She says: "A centrosome is not present as a constant structure in the majority of specimens, but a well-marked granule, whose appearance and staining reaction strongly suggest a centrosome, is to be seen in a number of cases," and concludes: "there is, it appears to me, strong presumptive evidence that this form has a flagellate stage, very probably in some invertebrate host."

Finally, Prowazeck (30) describes and figures a blepharoplast in the hæmogregarine of a Gecko (*Platydactylus guttatus*), and states that this structure frequently breaks up into fine granules—Chromidia of the blepharoplast. He was unable to discover any flagellate stage in the life-history of the Gecko parasite, and concludes that in the hæmogregarines the blepharoplast is a disused structure merely of phylogenetic interest, since trypanosoma-like forms provided with flagellum and undulating membrane no longer occur in these hæmoprotozoa.

Schaudinn's observations concerning the development of *Hæmoproteus noctuæ* and *Leucocytozoön ziemanni,* those of Rogers and Leishman on the culture forms of *Leishmania donovani,* and those of Miyajima on the culture forms of *Babesia parva,* have suggested that the hæmogregarines may possibly

also present a flagellate stage, but so far there is no real evidence in support of such a hypothesis. With regard to the assumed relation between *Hæmogregarina minima* and *Trypanosoma inopinatum,* Billet was evidently misled by the multiple infection of both the frogs and leeches used in his experiments. Brumpt (6) has shown that *Trypanosoma inopinatum,* when taken up by the leech, rapidly assumes the herpetomonad form, and that infected leeches when placed on a "clean" frog, even as late as a month after the first feeding, produce a severe and even fatal trypanosomal infection after a period of incubation of from eight to ten days. The binucleated "intermediate forms" described by Billet were no doubt resting forms of trypanosomes which had cast off their locomotor apparatus and become rounded.

In the numerous snakes I have examined I have often found hæmogregarines, but never any trypanosomes. Indeed, whilst hæmogregarines have been found very frequently in the Ophidia by numerous investigators, no trypanosomes[1] have so far been described from these reptiles. Miss Robertson's *Trypanosoma pythonis* is not a trypanosome, but a true hæmogregarine as evidenced both by her drawings and description. In lizards, also, I have frequently found hæmogregarines, but never trypanosomes. Here, again, though hæmogregarines are of common occurrence, trypanosomes appear to be somewhat rare. So far only two have been described, one by Gehrke in a Gecko, the other by Martin in a scink, *Mabuia raddonii.* Several authors, and amongst them Laveran, at any rate in his paper on *Hæmogregarina stepanovi,* published in 1898, ascribe the hæmogregarines to the Coccidia; others consider them to be more nearly related to the Gregarinida.

Life-history.—The life-history of the hæmogregarines, like that of other hæmoprotozoa, is divided into two cycles: a schizogonic or "vegetative" cycle spent in the blood of vertebrates and characterised by asexual multiplication, and a sporogonic or sexual cycle spent in the digestive organs of blood-sucking invertebrates and characterised by sexual reproduction.

Schizogonic cycle.—In examining fresh blood preparations

[1] Dutton, Todd, and Tobey, in their paper "Concerning certain Parasitic Protozoa observed in Africa" ('Ann. of Trop. Med. and Parasit.,' 1907, vol. i, p. 303), state they found a "single trypanosoma-like object" in a puff-adder caught in the Gambia.

from vertebrates harbouring hæmogregarines we find these parasites usually enclosed within the blood-cells they select for their development, but *in vitro* occasionally a number may be seen moving free in the *liquor sanguinis*. The intra-cellular parasites may vary greatly in size, structure, and appearance, according to the stage of development attained. For convenience of description we may distinguish three principal forms: *Young forms*, oval, fusiform, or club-shaped, with nucleus median, large, round, or oval, homogeneous. At first they are free within the stroma of their host-cells, later, encapsuled. *Adult sporonts*, club-shaped, more or less bulky, usually doubled up, always encapsuled, nucleus median, with chromatin filament forming a more or less open skein, or broken up into rods. Host-cells as a rule unaltered. *Adult schizonts*, large, more or less oval, bean-shaped or roundish, surrounded by a thick capsule; cytoplasm crammed with plastin spherules. Nucleus median, large, round; chromatin broken up into a number of chromosomes. Host-cell usually greatly altered.

Young forms.—The earliest forms or merozoites derived from the breaking up of the adult schizonts may be seen either on or within the blood-cells they have attacked, or still free in the *liquor sanguinis* within those organs of the vertebrate host in which segmentation takes place. They consist of a small body of oval or fusiform shape varying much in size, according to the species to which they belong and the nature of the schizonts from which they derive. Their cytoplasm is almost hyaline, their nucleus median and composed of a single dense mass of chromatin. Whilst free they exhibit various kinds of movement. They may alternately shorten and lengthen the body, or bend it in any direction. By the aid of such movements they manage to penetrate into their host-cells. Once within they soon begin to grow, their cytoplasm assuming a granular condition, and they appear as long, slender, club-shaped bodies, somewhat arched so as to present an inner concave and an outer convex aspect.

Adult sporonts.—When the parasite has attained certain dimensions, and is already enclosed within a capsule, the attenuated posterior extremity in most cases turns upwards along the inner surface of the body and extends a longer or shorter distance. In some species the recurved portion may be very

short and resemble the hook of a crochet-needle, in others it may attain a length equal to the anterior portion, giving the doubled parasite the appearance of a compressed letter U. In some species, as in *Hæmogregarina mesnili*, the parasite becomes so greatly elongated that it is obliged to form a more intricate coil within its capsule.

Capsule.—In stained preparations a white peripheral rim surrounds the parasite more or less completely. According to some authors the parasite lies in a mere gap of the surrounding protoplasm, which it fills completely in fresh smears, but only partly when contracted by fixing reagents, hence the colourless space at one or both sides of stained specimens. Others believe that a kind of cyst is formed by condensation of the host-cell protoplasm round the parasite. The examination of numerous species of hæmogregarines from mammals, reptiles, and amphibians has convinced me that all the endocorpuscular forms, save the very earliest, are enclosed within a shell or capsule produced by the parasite itself, either by means of a special secretion or by a process of ecdysis, the hæmogregarine shrinking from its detached former skin as do certain flies in the formation of their puparium. The capsule varies much in size, shape, thickness, transparency, and other particulars, according to the species of hæmogregarine to which it belongs as well as to the stage of development. In some cases it is so exceedingly thin and transparent that it may escape detection, the parasite appearing to be lying merely in a kind of cavity in the substance of the host-cell. In other cases it is very thick and resists considerably the penetration of stains, so that prolonged staining is necessary to colour the parasite within and bring out details of structure. The presence of a capsule may be evidenced by a number of indications. Thus, in preparing films for microscopical examination some of the hæmogregarine-infested blood-cells may be disrupted; the parasites remain closely doubled up, being evidently confined by a capsule to the exterior of which fragments of the host-cell nucleus may be seen adhering. By the addition of a drop of water to the fresh blood-film, as suggested by Hagenmüller, it is quite easy to demonstrate the presence of a capsule. The water dissolves the hæmoglobin and renders the capsule opaque. The parasite within is no longer visible, but the opaque oval capsule becomes quite evident. In specimens deeply

stained with Giemsa's stain the outline of the capsule assumes a bright pink colour, and is frequently stippled with deeply-stained granules which show it up very distinctly. Sometimes we may detect a second inner shell produced by a subsequent ecdysis. This inner membrane also may show deeply-staining granules. After the escape of the parasite the remains of the broken capsule may be seen either still within the host-cell or free in the *liquor sanguinis*. The capsule appears to burst along certain definite lines of cleavage, which I have been able to detect in all the species of hæmogregarines I have had the opportunity of examining. Two of these lines are to be seen, one at each end of the capsule passing transversely across its long axis at 1μ to 2μ from the corresponding extremity. They resemble the opercular lines of certain trematode eggs. A third longitudinal line may at times be seen running along the middle of the capsule between the opercular lines. In specimens

FIG. 36.



Showing the halves of the burst capsule.

deeply stained with Giemsa's stain the cleavage lines assume a pinkish colour similar to that of the contour line of the capsule; in others they show as white, unstained lines, owing to a difference in light refraction. After bursting open the two halves of the capsule roll up after the fashion of the mature seed-pods of certain leguminous plants, and may be easily detected in the shape of two deeply-stained scrolls lying side by side or crosswise.

Escape of sporonts from their capsules and host-cells.—According to Labbé (15, p. 188), every hæmogregarine, on attaining its full growth, escapes from the host-cell to spend a period of free life in the *liquor sanguinis* and conjugate; it then re-enters a fresh host-cell (erythrocyte, leucocyte or tissue cell) for the purpose of reproduction. This interpretation of the life-history of hæmogregarines has been accepted by the majority of authors. Professor Minchin, in his article on "Protozoa" contributed to Allbutt and Rolleston's 'System of Medicine' in 1907, says: "The

hæmogregarines of cold-blooded animals frequently quit the corpuscle and become free for a time in the blood-plasma, after which they may penetrate a blood-corpuscle again. Free stages appear to alternate in this way with intra-corpuscular stages in a normal sequence." And quite recently Prowazeck (30, p. 35), speaking of the hæmogregarines of a python (probably *Python reticulatus*) says: "These hæmogregarines often change their host-cell." My observations lead me to consider this interpretation as erroneous. It is perfectly true that some of the parasites, the fully developed sporonts, do escape from their capsules and host-cells, but never in the blood of their living host, only after the death of the host and in blood that has been abstracted from the vessels and exposed to extra-corporeal conditions. Already Danilewsky (11, p. 21–23) had noticed that the free sporonts of *Hæmogregarina stepanovi* were more abundant in abstracted blood after an interval of 24 to 48 hours than in fresh preparations, and Laveran (22), working with the same organism in 1898, showed that in blood fixed immediately on abstraction there are found only endocellular parasites, whilst many free forms may be seen in the same blood examined without a fixative agent some time after abstraction. A similar observation was made by Durham concerning the hæmogregarines of certain toads at Parà in 1900, and by Christophers with regard to *Hæmogregarina canis*. All the hæmogregarines of cold-blooded animals I have been able to examine were always intracellular so long as they remained within the circulation of their hosts. In abstracted blood kept for some time *in vitro* I occasionally found numerous free parasites, but only when adult sporonts were present in the blood. I have never seen young forms or adult schizonts quit their capsules and host-cells, therefore I do not believe that the encapsuled parasites "often change their host-cells" as suggested by Labbé and his followers. The facts that all hæmogregarines are encapsuled and that the sporonts as a rule do not damage their host-cells are adverse to any change of habitat. The schizonts do not escape until broken up into merozoites; the sporonts only when adult, and when placed in conditions similar to those which obtain when they are naturally transferred to the gut of their necessary invertebrate host.

Conjugation.—Labbé (15) describes isogamous union both in

Hæmogregarina minima and *H. lacertarum*, and states that the conjugation may occur either amongst the free forms in the blood-plasma or amongst the intra-cellular parasites. The free forms may be watched *in vitro* approach one another, place themselves side by side, then unite. Fusion of the cell-plasma begins usually at the posterior extremities and is accompanied by karyogamy. The conjugation of intra-cellular parasites is mentioned also by Marceau (27) for *H. lacertarum*. So far as the intra-cellular forms are concerned, neither Labbé's nor Marceau's descriptions are convincing. Judging from his figures, Marceau probably mistook closely-applied double inclusions for conjugating forms. With regard to conjugation

Fig. 37.

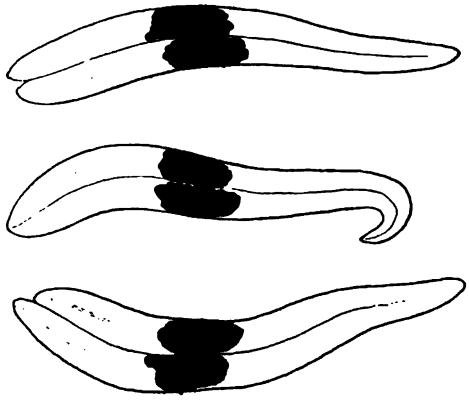

of free sporonts I can fully confirm Labbé's observations, having witnessed it not only *in vitro* but also in blood taken from the gut of a tick fed on a hæmogregarine-infected lizard. I have had the opportunity of examining the process of accouplement so frequently in *Hæmogregarina seligmanni* that I have no doubt whatever about it. In some of my slides the pairings are strikingly numerous. In each case the exactly similar adult sporonts are closely applied, their posterior extremities usually apparently fused and describing together the same curves, but I have not seen the nuclei of the conjugating hæmogregarines unite as described by Labbé. According to this author, the conjugation is followed by re-entrance into a fresh blood-cell and subsequent segmentation. This is certainly a mistake.

The accouplement occurs only amongst the free sporonts and is undoubtedly a first step in the sporogonic cycle which must take place in the gut of the invertebrate host.

The belief that the free sporonts do re-enter fresh blood-cells is not without some apparent foundation. In the first place, owing to their peculiar rostrum, the free parasites pierce quite easily through the erythrocytes. This has been witnessed by numerous observers and I have seen it myself many times. Occasionally they appear to settle within the erythrocytes.

FIG. 38.

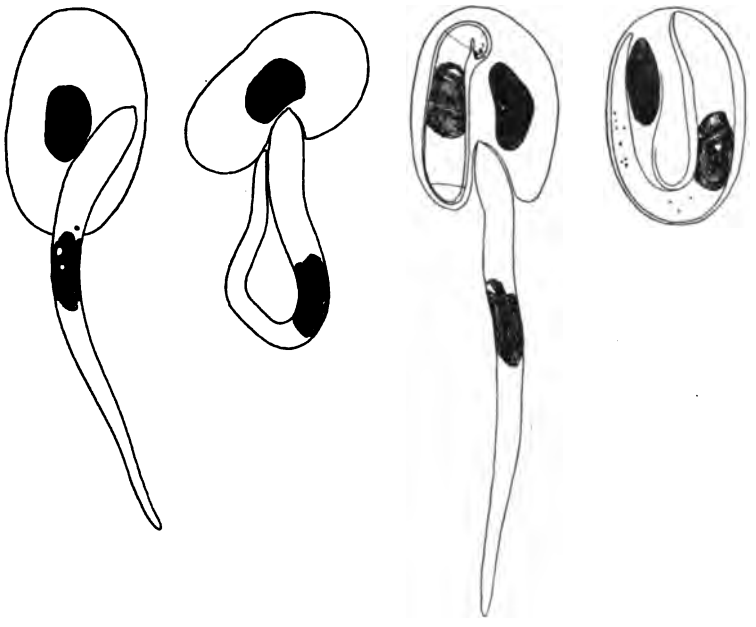

Certainly, in examining stained preparations one meets with cells containing parasites which seem to have entered during the preparation of the film. In fact they differ from the ordinary intra-cellular forms by the following characters: they are not encapsuled, their bodies describe a wide curve instead of being closely doubled up; their cytoplasm stains very deeply as in the free forms; they invariably encircle the host-cell nucleus which is always to one side in the ordinary intra-cellular forms. I believe that the forms looked upon as evidence of re-entrance are in reality parasites fixed and stained whilst endeavouring to

escape from their host-cells after breaking through their capsules, hence the deep staining and unfolding. The fact that they encircle the nucleus is accounted for by their peculiar method of escape: they usually swing rapidly several times round the nucleus as if to acquire impetus and finally rupture the erythrocyte membrane, bulging it out by means of their anterior extremity, which always protrudes first from the cell.

Structure of free sporont.—The free sporont is not amœboid, but has a body of definite form. It is invariably club-shaped but its proportions differ considerably in the various species. The anterior extremity corresponds to the thicker, rounded end of the club; the tail tapers more or less to a point. About the middle of the body is the nucleus, which may be round, oval, or quadrilateral. The endoplasm is alveolar and contains a variable number of cytoplasmic granules. The cytoplasm is modified

Fig. 39.

into *epicyte, sarcocyte,* and *myocyte.* The epicyte is a cuticle which may be shed by a process of normal ecdysis or torn off during film preparation (Fig. 39). The myocyte is composed of muscular fibrils which form a network about the entire body. These fibrils or myonemes have been described in the hæmogregarines by numerous authors from Labbé (1894) to Papovici Baznosanu (1907). I have seen them myself, but very imperfectly, as minute cross stripes. Presumably they subserve active movement. At the apex of the rounded anterior extremity may be seen a minute beak-like projection which appears to be retractile. I have seen it in all the hæmogregarines so far examined, but in certain species it seems to be more developed than in others. Probably it is this rostrum that enables the parasite to pierce the erythrocytes. From the base of the rostrum there can be seen a slender, somewhat sinuous line or tube running through the middle of the anterior portion of the body

to a point about halfway between the anterior extremity and the nucleus. It appears to be a permanent and definite organelle.

Motility of sporonts.—All encapsuled hæmogregarines are perfectly quiescent so long as they remain within the body of their living vertebrate host, but the fully developed sporonts begin to move and endeavour to escape from their host-cells as soon as the blood is abstracted from its vessels. In films rapidly fixed, when few or no sporonts have had time to rupture their capsules and escape, the enclosing host-cells are surrounded by a narrow colourless area, which seems to indicate that the included parasites had moved whilst the film was drying, thereby detaching the cells from the desiccating plasma.

The free sporonts exhibit a variety of movements, the most characteristic being one of perfect translation, uniform and rectilinear, analogous to that of certain gregarines. The animal seems to slide rapidly along, broad end foremost, without the slightest alteration in shape; it can travel to right or left, arrest or resume motion. This peculiar gliding movement was at one time ascribed to imperceptible undulations of the body, but now we know that it is the result of a secretion of gelatinous substance from the ectoplasm as observed by Schewiakoff in gregarines, Schaudinn in Coccidia and Lauterborn in certain diatoms. Hintz pointed out that occasionally a tiny droplet of gelatinous substance may be seen at the posterior extremity of the free sporonts of *Hæmogregarina minima*, and Chaussat, in 1850, actually represented it as part of his *Anguillula minima*. Several observers have noticed that the erythrocytes may occasionally cling to a free hæmogregarine and be dragged some distance, and that the animal, unable to free itself of a cell, will whirl round so fast that it is quite impossible to follow its movements. Besides gliding between the erythrocytes, the hæmogregarines may bend and unbend the anterior third of their body in every direction or coil themselves up into a ring. Not infrequently they will bring their extremities together and then suddenly relax the bend, making a peculiar jumping movement not unlike that of a fish out of water. Occasionally during the progressive gliding movement wave-like annular constrictions may be seen passing backwards along the body of the animal. A second and even a third constriction may commence before the first one has run off, thus giving a bead-like outline. Sometimes the constriction is

arrested at one spot for a considerable time and some of the hæmogregarines may be fixed in this condition and thus present a moniliform appearance.

Sexual differentiation.—Simond (44), in his paper on the endocorpuscular hæmoprotozoa of reptiles, suggested that, provisionally at least, the absence of any sexual differentiation might be taken as one of the characteristics of the genus *Hæmogregarina.*

In 1900, Billet described a hæmogregarine (*H. platydactyli*) of the Moorish Gecko (*Tarentola mauritanica*), and pointed out that it presents two distinct appearances, which may be looked upon as representing male and female forms respectively. Two years later Hintze, in a study of the development of *Hæmogregarina minima*, described for this organism three different forms, viz. male, female, and indifferent. Quite recently Prowazeck has likewise recognised three different forms in a hæmogregarine of the Indian Gecko (*Gecco verus* [syn. *Platydactylus guttatus*]).

In the hæmogregarines I have had the opportunity of examining, I have been unable to distinguish three different forms simultaneously in the same species. In some I have observed a marked sex-differentiation into male and female forms, not only in the adult sporonts, but also in the forms undergoing schizogony. Thus in *Hæmogregarina rarefaciens* the schizonts are clearly differentiated into male and female forms. Indeed, in many species two distinct kinds of "cytocysts" have been described, and I have seen myself some containing numerous long, slender merozoites (micro-merozoites), others fewer, short bulky merozoites (macro-merozoites) corresponding to male and female forms respectively. In other species there is apparently no differentiation. Thus in *Hæmogregarina seligmanni* all sporonts and schizonts look exactly alike if compared in the same stage of development. I have seen many free sporonts of this hæmogregarine associate two by two, and in every case the coupled organisms were exactly similar in all structural details.

Adult schizonts.—The adult schizonts were described first by Danilewsky (10, p. 52–56) in *Hæmogregarina stepanovi* as large, oval bodies, occupying almost entirely their dilated host-cells, the nucleus of which may be seen at one side greatly elongated and flattened. They are characterised by a peculiar granular

appearance of their cytoplasm and a large round nucleus. In a more advanced stage their surface presents a number of rounded protuberances, which give them a mulberry-like appearance, and the enclosing erythrocytes become dehæmoglobinised. Finally they break up into eight, twelve or sixteen merozoites. Danilewsky proposed to call the mature schizonts *cytocysts* or *cytospores*, and pointed out that they are most numerous in the bone-marrow. Labbé (15) showed that both in *Hæmogregarina minima* and *H. lacertarum* the adult schizonts might be of two kinds: some (*cytocystes à macrosporozoites*) giving rise to a certain number of comparatively large merozoites—found at any season—and others (*cytocystes à microsporozoites*) producing smaller and more numerous merozoites, occurring chiefly in summer, from May to June, and more especially in very acute infections. Several investigators have confirmed Labbé's observation and describe macro- and micro-merozoites in other species of hæmogregarines. A similar dimorphism is also witnessed to a certain extent in the schizogony of other hæmoprotozoa, such as *Plasmodium danilewskyi*, a parasite of the common house-sparrow (*Passer domesticus*). Probably, as in certain coccidia and gregarines, it may indicate an early sexual differentiation, true gametocytes being preceded by one or more generations of sporonts multiplying by schizogony. In certain hæmogregarines of fishes the schizogony is greatly reduced: thus in *Hæmogregarina quadrigemina*, a parasite of *Callionymus lyra*, segmentation is represented by longitudinal division into four merozoites, whilst in *Hæmogregarina bigemina*, a parasite of the smooth blenny (*Blennius pholis*), it is merely a binary fission.

Schizogony may occur in the peripheral circulation: thus both *Hæmogregarina simondi*, a parasite of the sole (*Solea vulgaris*), and *H. metchnikovi*, a parasite of an Indian soft tortoise (*Trionyx stellatus*), break up into merozoites within the peripheral blood of their respective hosts, but more frequently segmentation takes place within the capillaries of the internal organs, and may be confined to one selective organ such as the liver, the lung, or the bone-marrow. In *Hæmogregarina jaculi*, a parasite of the jerboa (*Jaculus jaculus*), schizogony takes place in the liver and kidneys of the host, not in the erythrocytes within the capillaries, but in the tissue cells of these organs. As a rule, in most species of hæmogregarines the adult schizonts in their pre-segmenting

stage occur in the peripheral circulation. These forms are easily recognisable; they are comparatively large, oval, or rounded bodies provided with a large, round, central nucleus, the chromatin of which is usually broken up into chromosomes. Their cytoplasm is literally crammed with large refractile plastin granules or spherules, which give them a very striking appearance. The host-cells containing them are enlarged and dehæmoglobinised. The enlargement is frequently considerable. The erythrocytes containing adult schizonts of *Hæmogregarina seligmanni* may measure more than twice their normal size.

It is not quite clear whether the segmenting forms develop directly from the young forms or whether they first assume the doubled-up form characteristic of the adult sporonts. Labbé says: "The Drepanidium (*Hæmogregarina minima*), to become round, approaches its extremities, the suture line soon disappears, and the parasite assumes a perfectly round form." Billet and others likewise believe that the segmenting forms are derived from the bent forms, a complete fusion taking place between the two extremities. I have seen forms suggesting such a fusion (see Pl. XII, fig. 23).

Action on host-cell.—The majority of hæmogregarines are parasites of the erythrocytes; some inhabit the leucocytes, both mononuclear and polymorphonuclear, others are found indifferently in erythrocytes, erythroblasts, and leucocytes. The action of the parasite on its host-cell varies considerably according to the species and the stage of development. As a rule the sporonts do not injure their host-cells. The preservation of the latter is indispensable to their safety. According to Labbé a veritable cytosymbiosis is established between the two. The sporont grows very slowly and may have to remain quiescent for a long period until liberated by the necessary blood-sucker. The segmenting forms, on the other hand, grow very rapidly and must necessarily rupture the enclosing cells to scatter their progeny, and they give rise to very destructive changes.

In most species the sporonts do not appear to cause any change whatever in their host-cells. The infected erythrocytes remain normal in size, shape, and appearance, and the staining reactions of their protoplasm are unaltered. Their nuclei remain free and retain both their normal characters, and, in many cases, their central position. Very frequently, however, the nuclei are

more or less displaced, either when the parasite assumes large dimensions or when two or more parasites occupy the same cell. The relative positions of the parasite and host-cell nucleus may vary considerably. As a rule the parasite is placed on one side of the nucleus with its long axis parellel to that of the nucleus and its convex aspect turned, in the majority of cases, towards the periphery of the cell, but it may lie obliquely above, below, or across the nucleus, or indeed in every conceivable position. At times, especially in heavy infections, one meets with a certain amount of variation in the size of the erythrocytes; in such cases the infected cells may be either above or below the average size quite independently of any action of the parasite on its host-cell.

The segmenting forms almost invariably cause a considerable swelling of the cell with progressive loss of hæmoglobin. The nucleus is always closely adherent to the encapsuled parasite, greatly hypertrophied, flattened, or fragmental. In certain cases (see *Hæmogregarina rarefaciens*) the affected erythrocytes become distended to about three or four times their normal size and completely dehæmoglobinised. The cells occupied by *Hæmogregarina brendæ* are likewise considerably enlarged, but chiefly in their long diameter; they usually present a colourless peripheral zone surrounding a dense layer of hæmoglobin about the nucleus and parasite.

It is quite possible that the great increase in the size of the erythrocytes containing the segmenting forms may favour the arrest of these forms in the small visceral capillaries.

Billet (2) has noticed some very interesting changes in the cells occupied by *Hæmogregarina viperina.* Whilst the parasite brings about a complete disruption of the nucleus the enlarged discoloured erythrocytes becomes stippled with numerous chromatic granules disposed in concentric circles round the parasite. Billet considers these granules as analogous to the Schüffer-Maurer dots because they present the same staining reactions.

Sporogony.—Our knowledge concerning the sporogony of the hæmogregarines is very imperfect. At first the hæmogregarines were confounded with certain Coccidia. Lankester (24) in 1882 suggested that *Hæmogregarina minima* might represent the young stage of a coccidium (*Tsospora liebkühni*) discovered in

1854 by Lieberkühn in the kidney of the edible frog, and Hintze, in 1901, confounded it with a coccidium of the intestinal epithelium, and declared he had reproduced the infection in three clean frogs by feeding them with the intestines of coccidium-infected frogs, whilst a fourth frog fed solely on the muscles of the infected amphibians did not contract the disease. According to Hintze, under natural conditions, the infection is contracted either by the frogs eating one another or through ingestion of their excreta. Two years previously Langmann (22) had expressed the opinion that probably snakes acquired their hæmogregarines by feeding on infected frogs.

In 1901 Simond (44) suggested that ticks should be examined as probable conveyors of hæmogregarine infection amongst land reptiles, and Laveran (26), the year after, declared that the sporogony of the hæmogregarines, like that of other hæmoprotozoa, must take place in the body of blood-sucking ectoparasites.

In 1902 Durham (14) examined some small toads at Parā and found a hæmogregarine both in the blood of the amphibian and in the body of certain ticks which infested it. "Examination of the contents of the ticks showed curious cysts, evidently different from the curious nuclei of the tick's economy, varying in size up to about 60 μ. It was noted that the movements of free drepanidia in the fluids from the tick's stomach were much more active than in the toad's blood; appearances suggestive of conjugation were also seen."

In 1903 Schaudinn (42) discovered that the sporogony of *Hæmogregarina lacertarum* takes place in a common dog tick, the Castor Bean Tick (*Ixodes ricinus*), the larvæ and nymphæ of which are found on lizards, birds, and small mammals. He found the oökinetes in the tick's stomach, and proved that the ticks may transmit the infection not only directly but also through their progeny—a necessary provision because during the adult stage they attack mammals only.

Soon after Siegel (43) found that the sporogony of *Hæmogregarina stepanovi*, parasite of the European pond tortoise (*Emys orbicularis*), takes place in a leech, *Placobdella catenigera*. So long as the imbibed blood remains stored in a concentrated form within the diverticula of the leech's stomach, the encapsuled sporonts remain quiescent. To witness a change, it is necessary

to examine that minute quantity of blood which passes each day into the intestine. Here the erythrocytes are destroyed and the hæmogregarines liberated. The free sporonts penetrate between the cells of the intestinal wall and become differentiated into male and female forms. The microgametes are exceedingly small. After fertilisation has taken place in the intestine, the motile oökinetes pass through the wall into the blood sinuses which embrace the intestine and are thence carried to the heart, and finally reach the pharyngeal glands. Here they settle, become round (oöcysts), and enlarge considerably. Meanwhile their contents break up into numerous sporoblasts, each one of which contains a number of sporozoites. Finally the cysts burst and the sporozoites, in the form of minute spirally-twisted filaments, may be seen within the lumen of the gland waiting to be transmitted to other tortoises during the act of sucking. Some of the oökinetes, instead of migrating to the pharyngeal glands, seem to pass to the ova. Siegel found the sporozoites also in the hardly developed glands of embryos still subsisting on the yolk of the ovum, thus proving the existence of hereditary infection.

As elsewhere stated, Billet, in 1904, asserted that the sporogonic cycle of *Hæmogregarina minima* took place in *Helobdella algira*, the parasite assuming the form of a trypanosome in the leech.

Brumpt (5 and 6) examined a large number of leeches with a view of elucidating the sporogony of the hæmogregarines, and he found the oökinetes of *Hæmogregarina bagensis*, a parasite of the Spanish Terrapin (*Clemmys leprosa*), in *Placobdella catenigera*, and those of *Hæmogregarina simondi*, a parasite of the sole (*Solea vulgaris*), in *Placobdella soleæ*. He also found similar oökinetes in *Placobdella scorpii* from the sea scorpion (*Cottus scorpius*), in *Trachelobdella lubrica* from *Scorpœna porcus*, and in *Branchellion torpedinis* from the Angel or Monk fish (*Squatina angelus*). He believes the sporozoites described by Siegel to be nothing more nor less than bacteria.

In 1905 Christophers (10) stated that he had discovered the sexual cycle of *Hæmogregarina gerbilli*, a parasite of the Indian field rat (*Gerbillus indicus*) in the rat's louse, *Hæmatopinus stephensi*. He described large oöcysts, 10 to 350 μ in diameter, from the body cavity of the insect. Each cyst contained

numerous sporoblasts, and each sporoblast six to eight sausage-shaped sporozoites 15 μ long by 4 μ broad. In a later paper, however, he expresses a doubt as to whether these cysts have anything to do with the hæmogregarine.

In 1906 Captain Patton (36), in describing *Hæmogregarina funambuli*, a parasite of the five-striped palm squirrel (*Funambulus pennanti*), stated that he had seen free sporonts in the stomach of the squirrel's louse, also a species of *Hæmatopinus*.

In 1907 Christophers (11) claimed to have proved that the sporogony of *Hæmogregarina canis* occurs in *Rhipicephalus sanguineus*, a tick very common on the pariah dogs of India. Within the tick's gut the sporonts escape from their capsules and lodge themselves in the large cells of the gut; here they multiply by fission and give rise to sexually differentiated forms which conjugate and become encysted. The resulting oöcyst attains a diameter of 14 μ. Further development is uncertain. The sexual cycle of *H. canis* seems to take place solely in the adult female ticks. In the larva and in the male tick Christophers was unable to trace any development. In the nymph the parasites exhibit the early stages of development, but completely disappear by the fourth day.

In 1905 Laveran and Negre (28) found a protozoon parasite in the stomach contents of ticks collected from specimens of the Algerian tortoise (*Testudo ibera* [= *T. mauritanica*]). The ticks were identified as specimens of *Hyalomma ægyptium*, and the parasite was looked upon as possibly representing a developmental stage of *Hæmogregarina mauritanica* (a hæmogregarine of the Algerian tortoise discovered by Sergent in 1904), although found also in ticks from tortoises presenting no hæmogregarines in their blood.

The frequent occurrence of *Hyalomma ægyptium* on the Algerian tortoise and of *Hæmogregarina mauritanica* in the blood of the latter induced Nicolle and Comte (35) to carry out some experiments in order to verify the suggestion made by Laveran and Negre. They found that neither the adult male nor the adult female ticks can transmit the infection directly, because as a rule they do not pass from one host to another, therefore infection must take place by hereditary transmission. In 1907 Papovici Baznosanu declared that the sexual cycle of

Hæmogregarina mauritanica occurs in *Hyalomma affine* (= *H. syriacum*).

In line with Laveran and Negre's observations concerning the protozoal parasite of *Hyalomma ægyptium*, it is interesting to recall the gregarine-like organism found by Johnson (19) in female specimens of *Anophiles maculipennis* and the "coccidium" described by Dutton, Todd, and Tobey (15) from *Pyretophorus costalis*. I have myself found conjugating hæmogregarines in the stomach contents of a female tick of undetermined species detached from a very heavily infested monitor.

Distribution of hæmogregarines according to host species.—So far hæmogregarines have never been found in birds. In mammals several species have been described within recent years; they occur in rats, squirrels, dogs, cats, and oxen. In fish their distribution is peculiar; they are very common in all kinds of salt-water fish, but unknown in fresh-water fish, with, as yet, only one exception—the eel, which grows in rivers and spawns in the sea. In batrachians and reptiles they are exceedingly common.

With regard to snakes, all families seem liable to hæmogregarine invasion; these parasites have been found in the Boidæ, in the Colubridæ, and in the Viperidæ all the world over. Some species appear to be more liable to this kind of infection than others, and this may be due in some way to the nature of their habitat. Langmann noticed that water-snakes are more frequently infected than land species. So far I have not been able to find hæmogregarines in the puff-adder (*Bitis arietans*), although I have examined most carefully forty specimens of this snake from various parts of Africa.

Distribution according to locality.—Locality seems to have considerable influence with regard to the distribution and prevalence of hæmogregarine infection, and this is more noticeable in those species which are not strictly limited to particular stations. Whilst carrying out certain experiments and researches in the Roman Campagna during the malarial season of the year 1900, Sambon and Low (32) noticed that lizards collected in the district of Maccarese, at the mouth of the Tiber, were far more frequently infected with *Hæmogregarina lacertarum* than those captured in the district of Ostia, on the opposite side of the river. Celli and Sanfelice (8), though they never observed *H. stepanovi*

in the fresh-water tortoises (*Emys orbicularis*) from the swamps of Ostia and Maccarese, yet found it frequently in tortoises of the same species from Pisa and Venice. Laveran found it in 70 per cent. of specimens from the Italian lakes, and Danilewsky in almost every specimen from the neighbourhood of Kharkow. It should not be forgotten, however, that the prevalence of the infection may vary considerably from year to year in the same locality. Thus, in 1890, Celli and Sanfelice examined 100 specimens of the wall-lizard (*Lacerta muralis*) and twenty specimens of the green lizard (*L. viridis*) from the Roman Campagna, but failed to find any parasites. In 1900, in the same region, Sambon and Low examined 120 specimens of the wall-lizard and twenty-five specimens of the green lizard, and found *Hæmogregarina lacertarum* in nine of the former and in one of the latter.

With regard to snakes, Celli and Sanfelice examined sixteen specimens of the common snake (*Tropidinotus natrix*) from the Roman Campagna, but with negative results. Labbé (15), in 1894, stated that he had never been able to find any blood-protozoa in European snakes, and amongst the species examined he mentions the common snake (*Tropidonotus natrix*), the common viper (*Vipera berus*) and the smooth snake (*Coronella austriaca sen lævis*). In 1900, in the Roman Campagna, Sambon and Low examined twenty-five snakes belonging to the species *Zamenis gemonensis, Coronella austriaca, C. girondica,* and *Vipera aspis,* also with negative result. So far hæmogregarines have been reported only three times from European snakes. Hagenmüller described one from *Macroprotodon cucullatus,* Börner a second one from *Coluber longissimus,* in Sicily, and Giordano another from the black viper (*Vipera aspis*), captured in Calabria, Italy.

Number of parasites.—The number of parasites in any given infection varies greatly. Sometimes they are so scarce that they may be easily overlooked in a hasty examination. There may be only two or three in a slide; it may be necessary to examine two or three slides even to find a single example. On the other hand, the hæmogregarines may be so numerous that they are present in a third of the blood-cells. In heavy infections it is quite common to find two parasites within the same host-cell, and some slides may present as many double inclusions as single ones. As a rule the two parasites are of about equal size, but not infrequently the same host-cell may contain two organisms

differing greatly in the stage of their development. In rare instances three parasites may be found in a single blood-cell.

Species.—There is a considerable diversity of opinion with regard to the specific difference of the hæmogregarines from different species of reptiles. Some authors refer them all to the type species *H. stepanovi* described by Danilewsky from the European pond tortoise (*Emys orbicularis*). Others admit of just a few types corresponding to the main divisions of reptiles. Thus Lutz considers all the hæmogregarines found in snakes as belonging to one and the same species, for which he proposes the name of *Drepanidium serpentium.* Others, again, consider that to each species of reptile there is a corresponding and distinct species of hæmogregarine.

As a rule, it is true that different species of hæmogregarines are found in different species of crocodiles, lizards, snakes, or tortoises, especially when the latter belong to different zoological regions. This is exactly what we should expect seeing that, under similar conditions, the metazoan parasites of these reptiles, such as *Ascaris, Physaloptera, Filaria, Bothridium, Echinorhynchus, Porocephalus,* are represented by different species. On the other hand, certain species of hæmogregarines, like certain species of metazoan parasites, may be found in a variety of hosts belonging not only to closely allied species, but to different genera or even families when the latter inhabit the same zoological region and are attacked by the same species of blood-sucking ectoparasites.

The question of species is the same in hæmogregarines as in other hæmoprotozoa. The differences are not always very clear, and the derivation of one species from some other species in a different host is, of course, beyond dispute. I should be inclined to look upon the hæmogregarines and other parasites of closely-allied host-species as "host-varieties" or "host-races" corresponding to the so-called "geographical races" of certain non-parasitic animals. To the casual observer all hæmogregarines may seem alike, but a careful comparative study discloses several marks of distinction, both morphological and biological, that suggest their separation into different species or varieties. The characters most serviceable for determination are the size and relative measurements of the parasite, the amount of lengthening and recurving of its posterior extremity, the thickness of

the capsule it produces, the action it exercises on the host-cell and its nucleus.

Pathogenesis.—Most authors look upon the hæmogregarines as of little or no pathogenic importance. Laveran (22), in a careful study of *H. stepanovi*, a common parasite of the European pond tortoise (*Emys orbicularis*), says: "The reproductive forms of *H. stepanovi* are somewhat rare, and this explains why the parasite is so slightly pathogenic. The infected tortoises do not appear to be ill even when their blood contains a large number of parasites. The parasites end by destroying the erythrocytes they occupy, but contrary to what occurs in malaria the destruction is very slow. In captive tortoises, not exposed to fresh causes of infection, the number of parasites tends to diminish progressively, and in such conditions the tortoises frequently recover." Likewise Soulié, in describing *H. psammodromi*, a parasite of the Algerian sand-lizard (*Psammodromus algirus*), says: "Even when the parasites are very numerous, there is neither diminution in the activity of the animal nor any apparent sign of disease."

Numerous observations on snakes and lizards affected by hæmogregarines have convinced me that these parasites are not infrequently deadly to their hosts. It is true that in some of the infected reptiles I also found other causes of death. For instance, in a Mocassin snake (*Tropidonotus fasciatus*), I found both the liver and spleen crammed with minute whitish tubercles which, on examination, proved to be teeming with acid-fast bacilli. In several snakes and lizards I found either intense enteritis or inflammation of the lungs, and in almost all some kind of helminth, but in the majority of cases the hæmogregarine infection was the most evident cause of death in the pathological complex. Indeed, in some cases the infection was so intense that quite one third of the total number of blood-cells was occupied by the parasites. Under such circumstances life is hardly conceivable.

The helminthes found in the hæmogregarine-infected reptiles were represented by various species belonging to the genera *Ascaris, Physaloptera, Kalicephalus, Bothridium,* and *Porocephalus.* Some are new species, and will be described in separate papers.

With regard to other blood-parasites in reptiles none were

ever found. Trypanosomes and spirochætæ were specially looked for, but the result was invariably negative. Yet trypanosomes have been described in a Gecko by Gehrke, in *Mabuia raddonii* by Martin, in a tortoise (*Damonia reevesi*) by Laveran and Mesnil. Dutton, Todd and Tobey have seen a "single trypanosome-like object" in a puff-adder caught in the Gambia colony.

Part II.

Hæmogregarines of Snakes.

History.—Pfeiffer (29), in his book on Protozoa, published in 1890, merely mentions the fact that hæmoprotozoa are found in the blood of snakes.

The first to describe them in the Ophidia was Billet (1), who, in 1892, found hæmogregarines in three species of snakes at Cao-Bang in Upper Tonquin. The snakes were: *Python reticulatus, Bungarus fasciatus,* and *Tropidonotus stolatus.* The parasites of the first two species he described and figured, naming them *Danilewskya pythonis* and *Laverania bungari* respectively, but having kept no slides or drawings of the hæmogregarine of *Tropidonotus stolatus,* which he found once only, Billet merely notes its occurrence and remarks that it resembles the parasite found in the python, and, in a general way, the hæmoprotozoa of tortoises.

In 1898 Hagenmüller (13) found hæmogregarines in *Macroprotodon cucullatus.* He distinguished two genera—a drepanidium resembling *Drepanidium princeps* (*Hæmogregarina minima*), parasite of the edible frog (*Rana esculenta*), and a danilewskya which he proposed to call *Danilewskya joannoni.*

In 1899 Langmann (17), whilst carrying out investigations on the venom of snakes, examined the blood of numerous species and found hæmogregarines in thirty-eight out of eighty-three snakes, viz. in all the Mocassin snakes (*Ancistrodon piscivorus*) from Florida with the exception of one born and reared for two years in captivity in New York, in two copper-heads (*Ancistrodon contortix*) from North Carolina, in one diamond-back[1] from

[1] This is probably a mistake. "Diamond-back" is the name given in America to a water-tortoise (*Malacoclemmys terrapin*), whilst a snake called the diamond rattlesnake (*Crotalus adamanteus*) occurs in the same part of America and is no doubt the species the author had in view.

Florida, in two prairie rattlers (*Sistrurus catenatus*) from Texas, in one Elaps (*Elaps fulvius*) from Florida, in one garter snake (*Tropidonotus sirtalis*) from Florida, in one ribbon snake (*Tropidonotus saurita*) from Sullivan County, New York, and in one water snake (*Tropidonotus sipedon*) from Florida. Langmann considered all the hæmogregarines he found in the various snakes as belonging to one species, and, having found them more frequently in water than in land snakes, suggested that the former might possibly become infected by feeding on frogs.

In 1901 Lutz (25) published a valuable paper on the hæmoprotozoa of snakes. He found hæmogregarines in the following species: *Eunectes murinus* (Anaconda), *Boa constrictor, Drymobius bifossatus, Coluber corais, Spilotes pullatus, Xenodon neuwiedii, Rhadinæa merremii, Philodryas olfersii, Herpetodryas carinata, Oxyrrhopus trigeminus,* and in various species of *Crotalus* and *Bothrops* (=*Lachesis*). In some species infection was the rule; in others it was quite exceptional to find these parasites. Thus, notwithstanding repeated examinations, he found hæmogregarines only once in *Oxyrrhopus trigeminus.* Lutz describes the schizogony of the snake hæmogregarines which he found to occur at certain seasons within the internal organs, and he figures, unfortunately very roughly, the segmenting schizonts of a hæmogregarine (*H. serpentium*) of the Anaconda (*Eunectes murinus*), which he discovered within the capillaries of the lung. He looked upon the endoglobular parasites found in the blood of the various snakes as belonging to one species, for which he proposed the name of *Drepanidium serpentium.*

In 1901 Simond (28), in a paper on the hæmoprotozoa of reptiles, stated that he had found hæmogregarines in the cobra, *Naja tripudians,* and in an undetermined species of *Coluber* in India, and in *Bothrops viridis* (*Lachesis gramineus*) in Further India.

The same year Börner (4), in a paper on hæmogregarines, described a new species found in the blood of *Coluber æsculapii* (*C. longissimus*) from the neighbourhood of Catania in Sicily. He names it *Hæmogregarina colubri,* and remarks that at certain stages of development it presents a halteridium-like form similar to that of the parasite of the Banded Krait (*Bungarus fasciatus*), which Billet ascribed to the genus *Laverania.*

In 1902 Laveran (25) described four new species of snake-

hæmogregarines: *Hæmogregarina najæ*, found by Dr. Gouzien in the blood of the Indian cobra (*Naja tripudians*) at Pondichéry, India; *H. zamenis*, found by Professor Soulié in the blood of *Zamenis hippocrepis* at Algiers; *H. crotali* and *H. mocassini* found by Dr. Langmann in the blood of *Crotalus confluentus* and *Ancistrodon piscivorus* respectively. Laveran, having had the opportunity of examining sections of the lungs of the Anaconda prepared by Professor Lutz and containing segmenting forms of *H. serpentium*, confirms the latter's observations as to the schizogony of this parasite. Finally, he discusses Langmann's theory as to the mode of infection, and suggests that the hæmogregarines of snakes, like those of lizards and tortoises, and like other hæmoprotozoa, must be inoculated by blood-sucking ectoparasites.

In 1894, Castellani and Willey (7), in a paper on the hæmatozoa of vertebrates in Ceylon, described a new species of hæmogregarine, *H. mirabilis*, discovered in the blood of *Tropidonotus piscator* in Colombo.[1]

The same year Billet (2) described a new hæmogregarine which he found in the blood of *Tropidonotus viperinus*, and named *H. viperini*.

During the past two years we have found several new and interesting hæmogregarines in snakes confined in the Zoological Society's Gardens.

During the years 1906 and 1907 over three hundred snakes were brought to the Prosectorium; of these two hundred and sixty were examined. They belonged to the following species:

BOIDÆ.—*Python sebæ* 7, *P. regius* 5, *P. molurus* 3, *P. reticulatus* 1, *P. spilotes* 2. *Boa constrictor* 5, *B. diviniloqua* 2. *Corallus madagascariensis* 2, *C cookii* 3. *Charina bottæ*, 1. *Eunectes notæus* 1. *Eryx jaculus* 2, *E. conicus* 4, *E. johni* 2.

COLUBRIDÆ.—*Tropidonotus natrix* 5, *T. tessellatus* 5, *T. viperinus* 2, *T. ordinatus* 1, *T. fasciatus* 2, *T. septemvittatus* 1. *Helicops angulatus* 1. *Ablabophis rufulus* 1. *Boodon lineatus* 3. *Pseudaspis cana* 11. *Zamenis gemonensis* 3, *Z. dahli* 2, *Z. hippocrepis* 1, *Z. mucosus* 1, *Z. constrictor* 1, *Z. flagelliformis* 2. *Lytorhynchus diadema* 8. *Chlorophis natalensis* 2. *Coluber leopardinus* 1, *C. quatuorlineatus* 2, *C. scalaris* 1, *C. corais* 1, *C.*

[1] According to Boulenger the Ceylon snake is specifically distinguishable from the common Indian *T. piscator*, and has been named by him *T. asperrimus*.

melanoleucus 7. *Heterodon nasicus* 2, *H. platyrhinus* 7, *Coronella austriaca* 4, *C. getula* 4, *C. triangulum* 3, *Contia vernalis* 1, *Homalosoma lutrix* 3, *Dasypeltis scabra* 1. *Tarbophis fallax* 1. *Leptodira hotambœia* 6, *L. annulata* 1. *Trimerorhinus rhombeatus* 9. *Cœlopeltis monspessulana* 5. *Rhamphiophis oxyrhynchus* 1. *Psammophis crucifer* 4, *P. sibilans* 2. *Dispholidus typus* 2. *Erythrolamprus æsculapii* 2. *Brachyaspis curta* 1. *Naia flava* 2, *N. tripudians* 2. *Sepedon hæmachates* 2.

VIPERIDÆ.—*Causus rhombeatus* 3. *Vipera berus* 12, *V. russelli* 1, *Bitis arietans* 40, *B. nasicornis* 10, *B. gabonica* 3, *B. atropos* 2. *Ancistrodon contortrix* 1, *A. piscivorus* 1. *Lachesis lanceolatus* 12, *L. mutus* 1, *L. alternatus* 2, *L. atrox* 1. *Crotalus scutulatus* var. *atrox* 1, *C. horridus* 1.

Hæmogregarines were found in the following species:

Python molurus 1, *P. spilotes* 1, *Boa constrictor* 1, *Corallus cookii* 1, *Eryx conicus* 1, *Tropidonotus fasciatus* 1, *Pseudaspis cana* 1, *Zamenis flagelliformis* 1, *Coluber corais* 1, *C. melanoleucus* 1, *Coronella getula* 1, *Psammophis sibilans* 1, *Naia tripudians* 1, *Lachesis lanceolatus* 1, *L. mutus* 1.

Whilst this paper was still in proof, Dr. D. Giordano sent me some blood-films from a black viper (*Vipera aspis*) in which he had discovered a new hæmogregarine. His description is given at page 363.

A DESCRIPTIVE CATALOGUE OF THE HÆMOGREGARINES AT PRESENT KNOWN IN SNAKES.

1. **Hæmogregarina pythonis** (Billet, 1895) Laveran, 1899.

Bibliography.—Billet (1).

Synonymy.—*Danilewskya pythonis*, Billet, 1895.

Hosts.—Schizogony in erythrocytes of Reticulated Python, *Python reticulatus* (Schneider).

Description.—According to Billet, the parasite has a definite gregarine-like form. It is longer than the erythrocyte, in the interior of which it lies doubled up; one extremity is rounded, the other attenuated, a median nucleus, and scattered deeply-staining granules which show up distinctly in films stained with methylene blue. The host-cell is enlarged and of a paler colour than the normal erythrocyte; its nucleus is pushed aside

by the parasite. Not infrequently the parasite presents the form of a large, more or less oval cyst with granular contents, which the author correctly interprets as the "cytocyst" of the schizogonic stage.

Observations.—Billet found the parasite in three specimens of *Python reticulatus* which he had the opportunity of examining at Cao-Bang, Upper Tongking. The infected cells were in the proportion of about 1 to 25.

The reticulated or Malay python is found in Burma and Indo-China, in the Malay Peninsula and Archipelago. Neumann

FIG. 40.

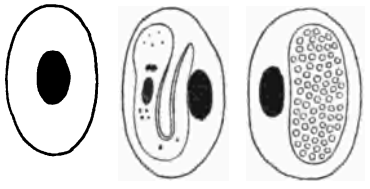

Hæmogregarina pythonis. (After Billet.)

reports two ticks from this snake—*Amblyomma furcosum* and *Amblyomma quadrimaculatum.*

2. **Hæmogregarina pococki** Sambon and Seligmann, 1907.

(Plate XII, figs. 1–7.)

Bibliography.—Sambon and Seligmann (41).

Hosts.—Schizogony in erythrocytes of the Indian python, *Python molurus* L.

Description.—The full-grown parasite occupies about two thirds of the enclosing erythrocyte; it measures from 11 μ to 12 μ in length by 3 μ to 4 μ in maximum breadth. It has the characteristic club-shaped form of hæmogregarines. The anterior extremity is broad, has a rounded contour, and measures about 4 μ in width; the posterior extremity is attenuated and flexed more or less sharply on to the concave aspect of the body for a distance varying between 3 μ and 4 μ. The cytoplasm is granular and stains blue with Leishmann's stain. In a few specimens it stains more faintly. The nucleus is usually median, but sometimes nearer one or other extremity; it is of a reticulate structure containing eight to ten deeply-staining coarse granules, and occupying a large round, oval,

or quadrate area, as a rule extending the entire width of the body and measuring about 4 μ in length. In some cases the nuclear chromatin is arranged in a skein-like formation. Frequently minute, deeply-staining granules are seen in the cytoplasm near to the nucleus or at either or both extremities. In the earlier more slender forms the nucleus is more compact. The parasites are surrounded by a narrow, clear zone, which indicates the existence of an enclosing capsule. The latter is brought out quite definitely by deep staining with Giemsa, which stains the outline and opercular lines. The position of the parasite within the blood-cell is either parallel to the long axis of the cell or more or less oblique. The host-cell does not

FIG. 41.[1]

Hæmogregarina pococki.

appear to be altered in shape, size, colour, or staining reactions; its nucleus is always displaced, but otherwise seems normal. The relative positions of the cell-nucleus and parasite are most varied, and seem determined only by chance.

Observations.—No free forms were seen, nor any other stage in the development of the parasite. Smears from the liver, spleen, kidneys, lungs, showed no other forms. A few eelworms were found in the stomach, numerous specimens of *Bothridium pythonis* in the intestine, and five specimens of a Porocephalus resembling *P. crotali* in the body-cavity.

Python molurus has a wide distribution in Asia; it is found in India, Ceylon, Southern China, the Malay Peninsula, and

[1] The circle in this and succeeding figures represents a human red blood-cell, for a standard of size; the nucleated oval represents the red cell of the snake.

Java. No ticks were found on the specimens examined, but the following species have been recorded: *Ixodes fuscolineatus, Aponomma gervaisi,* and *Aponomma latum.*

3. **Hæmogregarina robertsonæ**, n. spec.

Bibliography.—Robertson (39).

Synonymy.—*Trypanosoma pythonis* Robertson, 1906.

Hosts.—Schizogony in erythrocytes of an African python (either *Python regius* or *P. sebæ*) from the Gambia colony.

Description.—Under the name of *Trypanosoma pythonis,* Miss Robertson describes and figures (Fig. 42) a hæmogregarine found by Dr. Logan Taylor in the blood of an African python from Gambia. The host may be either the Royal Python, *P. regius,* or the West African Python, *P. sebæ,* since both are found in Gambia. Miss Robertson gives the following structural details:

FIG. 42.

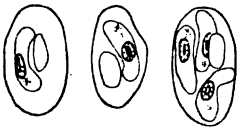

Hæmogregarina robertsonæ. (After Miss Robertson.)

Length of parasite, 12μ to 15μ or 16μ. One extremity slightly pointed and inclined to curl up, but never assuming the bent-up, double-shanked appearance peculiar to hæmogregarines. Protoplasm finely alveolar, no conspicuous granules, large nucleus composed of a hollow sphere, showing eight masses of chromatin and a karyosome, also at times hollow, and likewise showing eight masses of chromatin. A small, well-defined granule is frequently discernible, either lying closely apposed to the large nucleus or more or less remote, but usually bound to it by a quite definite thread. This small granule the author interprets as a blepharoplast. She says it is undoubtedly a product of the large nucleus, and probably arises from it by heteropolar mitosis. Although she did not find any actual flagellate forms she believes this parasite to be a trypanosome, and suggests that "the flagellate forms may possibly be found in the deep-seated organs, such as the liver or the spleen, or may only finally be developed in another host."

The description and figures given by Miss Robertson leave no doubt as to the hæmogregarine nature of the endocorpuscular parasite she describes from the blood of the python (cf. *H. pococki* and *H. shattocki*).

Observations.—On the West African Python the following ticks have been found: *Aponomma exornatum, Aponomma transversale, Aponomma globulus.*

4. **Hæmogregarina shattocki** Sambon and Seligmann, 1907.

(Pl. XII, figs. 11–16.)

Bibliography.—Sambon and Seligmann (41), — Manson (32).

FIG. 43.

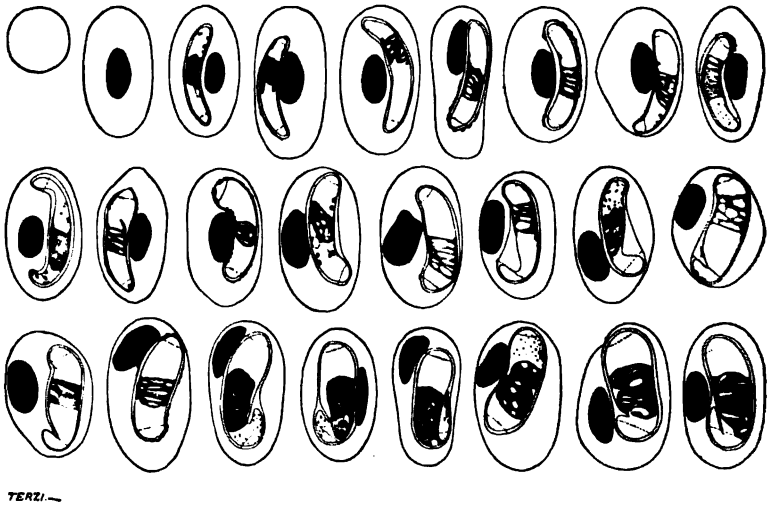

Hæmogregarina shattocki.

Hosts.—Schizogony in erythrocytes of the Diamond Snake, *Python spilotes* (Lacép.).

Description.—The full-grown sporonts are somewhat similar to those of the parasite of *Python molurus,* but much larger, measuring 22 μ by 4 μ. They are accompanied by numerous slender forms 11 μ to 15 μ long by 2 μ broad, of a crescentic shape, with both extremities rounded, and differing only slightly in thickness. This hæmogregarine, like *H. pococki,* seems to have little or no influence on its host-cell. The nucleus is

invariably displaced by the large forms which occupy more than half the erythrocyte. Sometimes the cell is slightly distorted, bulging out on the side to which the nucleus has been pushed.

Observations.—*Python spilotes* is a snake of Australia and New Guinea. The specimen examined came from Australia. Its stomach and intestines contained numerous eelworms. No ticks were found on it.

5. **Hæmogregarina terzii** Sambon and Seligmann, 1907.

(Pl. XV, figs. 37–42.)

Bibliography.—Manson (32).

Hosts.—Schizogony in erythrocytes of Common Boa, *Boa constrictor* (L.).

Description.—The full-grown sporonts are club-shaped organisms with the anterior end broad and rounded, the posterior extremity tapering slightly to a blunt point and folded back hookwise for a length of about 3 μ. They are enclosed within capsules measuring 14 μ in length by 4 μ in breadth. The nucleus measures, on an average, 3 μ in length by 4 μ in breadth, and is usually placed in the posterior half of the body. A variable number of deeply-staining granules are commonly present in the cytoplasm on either side of the nucleus. The host-cells enclosing these forms show no signs of degeneration.

The full-grown sporonts are found together with younger, more slender forms, measuring 13 μ to 14 μ in length by 1·5 μ in breadth. The latter have an elongated median nucleus, and their posterior extremity is not recurved.

The above-described forms were accompanied by a few very long and exceedingly slender forms occupying either normal sized erythrocytes (18 μ by 12 μ) or smaller cells (erythroblasts) measuring 13 μ to 14 μ in length by 8 μ to 9 μ in width. These long, slender organisms are enclosed within capacious capsules 11 μ to 12 μ long by 4·5 μ to 5 μ wide, which stain deeply of a bright crimson by Giemsa's method and prevent a clear view of the parasites within. The latter, so far as could be determined, measure about 14 μ in length and from 0·5 μ to 1 μ in breadth. Their nuclei show quite plainly through the capsules and measure 4 μ to 5 μ in length by 0·5 μ to 1 μ in breadth. The

host cells are somewhat poor in hæmoglobin, their nuclei are hypertrophied, measuring 8 μ to 11 μ in length by 2·5 μ to 3 μ in width, and are adherent to the capsules of the parasites and stain deeply.

Observations.—*Boa constrictor* is a South American snake. It ranges from Venezuela to Buenos Ayres. The hæmogregarine-infected specimen presented numerous tapeworms (*Bothridium obovatum*) in the intestine and several specimens of *Porocephalus crotali* in its lungs.

Out of the five boas examined one only, a non-infected one,

FIG. 44.

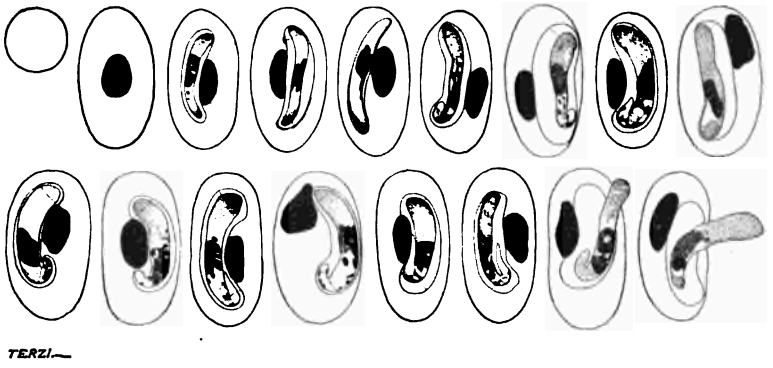

Hæmogregarina tersii.

presented a few male specimens of *Amblyomma dissimile*. Other ticks known to occur in *Boa constrictors* are *Ixodes fuscomaculatus*, *Aponomma gervaisi*, and *Aponomma læve*.

6. **Hæmogregarina lühei** Sambon, 1907.

Bibliography.—Manson (32).

Hosts.—Schizogony in erythrocytes of Cook's Tree Boa, *Corallus cooki* Gran.

Description.—Only full-grown sporonts were seen, some in longer, sausage-shaped capsules measuring about 14 μ in length by 4 μ in breadth, others in shorter, ovoid shells 10 μ to 11 μ long by 4 μ to 6 μ broad. The enclosed parasites are distinctly club-shaped, with their anterior extremities large, stout, and rounded, while their posterior ends are conical and recurved for

a length varying from 4 μ to 9 μ. The nucleus usually formed by cross strands of chromatin occupies a quadrilateral area, 3 μ to 4 μ long by 4 μ wide, situated within the thicker anterior portion. In specimens stained by the Giemsa method the cytoplasm is speckled by minute scattered chromatic granules, and the tail end for about a length of from 4 μ to 5 μ from the posterior extremity takes a peculiar dark greyish-blue stain. The contour and the opercular lines of the capsule often stain a bright crimson and show up very distinctly, especially in wrinkled specimens.

FIG. 45.

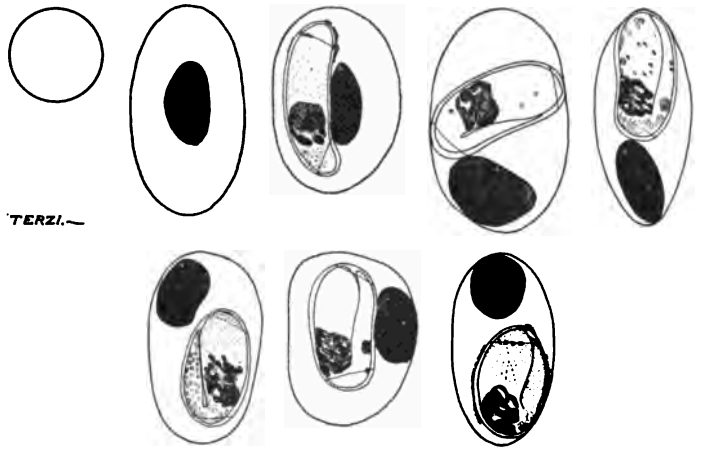

Hæmogregarina lühei.

Observations.—*Corallus cooki* is found in Columbia, Venezuela, British Guiana, Trinidad, and The Windward Islands of the West Indies.

Several ticks were found on two of the specimens examined, but they have not been determined.

The hæmogregarine-infected snake presented beneath its skin numerous specimens of a *Sparganum*.

7. **Hæmogregarina serpentinum** (Lutz, 1901) Sambon, 1907.

Bibliography.—Lutz (31), Laveran (25), — Lühe (30), — Manson (32).

Synonymy.—*Drepanidium serpentium* Lutz, 1901; *Karyolysus serpentium* Lühe, 1906.

Hosts.—Schizogony in erythrocytes of the Anaconda, *Eunectes murinus* (L.).

Description.—Lutz gave no particular description of this species, but described and figured its segmenting schizonts, which he found chiefly in the lungs. Two kinds of "cysts" were seen, some containing from two to twenty large granular "germs" with nucleus frequently near one extremity, and others

FIG. 46.

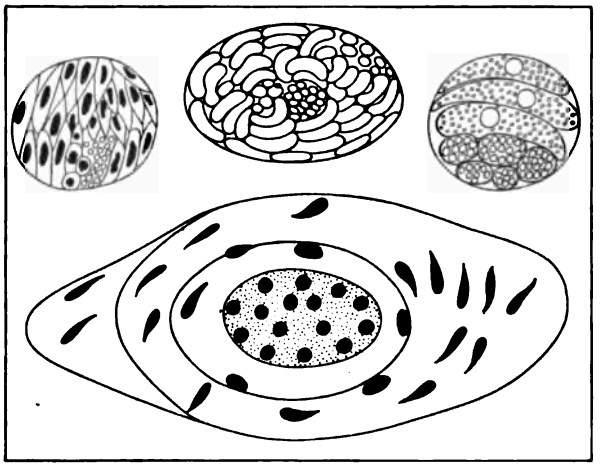

Hæmogregarina serpentium, segmenting schizonts. (After Lutz.)

containing from thirty-eight to three hundred small hyaline "germs" with rod-shaped nucleus.

Observations.—Lutz proposed the name *Drepanidium serpentium* for the hæmogregarines he found in over twelve species of snakes, believing that they probably belonged to one species. The name is here retained for the parasite found in *Eunectes murinus*, not only because this is the snake first mentioned in his list, but because the cytocysts figured in his paper and later examined and described by Laveran were those of the hæmogregarine found in this snake.

The only tick so far known to occur on the Anaconda is *Amblyomma fulvum*.

8. **Hæmogregarina cantliei** Sambon, 1907.

Bibliography.—Manson (32).

Hosts.—Schizogony in erythrocytes of the Conical Eryx, *Eryx conicus* (Schneider).

Description.—Adult sporonts enclosed within thick sausage-shaped capsules measuring 15 μ to 16 μ in length by 4·5 μ to 5 μ in breadth. Organism within club-shaped, presenting a rounded anterior third, at times almost globular, and the rest of the body tapering to a slender tail 2 μ to 3 μ long and invariably recurved. Nucleus median or situated nearer posterior extremity, usually 4 μ long by 3 μ broad, oval or irregular in outline, and with

FIG. 47.

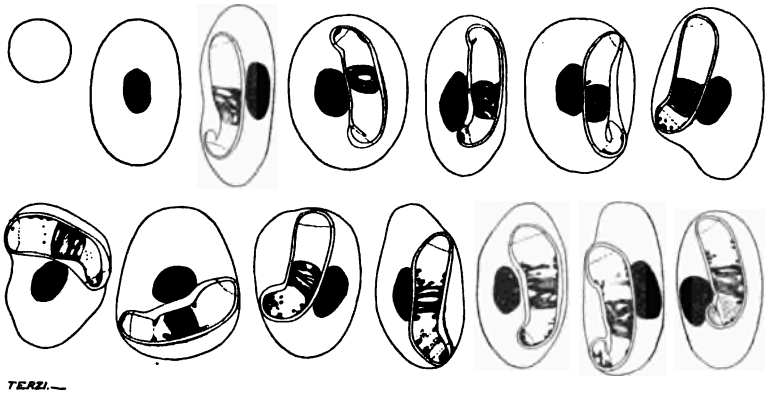

Hæmogregarina cantliei.

chromatin frequently arranged in cross strands. Free sporonts 16 μ to 18 μ long by about 3·5 μ broad.

Observations.—*Eryx conicus* inhabits India. It has been reported from Scinde, Gwalior, the Deccan, Madras, Anamalai Mountains, and Sikkim. No ticks found.

The hæmogregarine-infected snake had numerous specimens of *Kalicephalus* in its stomach and intestines. No ticks were found on any of the specimens examined.

9. **Hæmogregarina bradfordi** n. sp.

Hosts.—Schizogony in erythrocytes of Mocassin Snake, *Tropidonotus fasciatus* (L.)

Description.—Only adult forms seen. They are enclosed within long, conical, slightly arched capsules measuring 18 μ to 20 μ in length by about 4 μ in breadth. The capsules stain deeply with Giemsa's method and present numerous coarse and

FIG. 48.

Hæmogregarina bradfordi, n. sp.

darkly staining granules, especially along their contour line. The parasite within is not clearly visible; it does not appear to fold or coil within its capsule. Its nucleus measures as a rule 4 μ in length by 3 μ in width. The host-cell is dehæmoglobinised and enlarged; it usually measures 21 μ to 22 μ in length by 11 μ to 12 μ in breadth instead of the normal 18 μ by 10 μ. Its nucleus is elongated and stains deeply, it is invariably attached to the capsule of the parasite. Both are surrounded by a condensed portion of the host-cell protoplasm.

Observations.—The Mocassin Snake inhabits North America.

10. **Hæmogregarina mirabilis** Castellani and Willey, 1904.

Bibliography.—Castellani and Willey (7).

Hosts.—Schizogony in erythrocytes of *Tropidonotus asperrimus*, Boulenger.

FIG. 49.

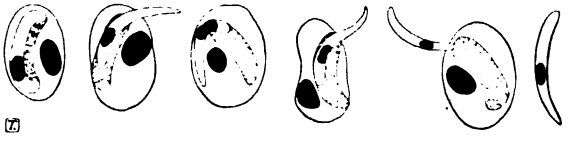

Hæmogregarina mirabilis. (After Castellani and Willey.)

Description.—The full-grown, doubled-up parasite is enclosed in a delicate capsule about 12 μ long, speckled by rows of red-stained granules. The nucleus, situated behind the middle of

the body, stains reddish blue; the cytoplasm takes a pale blue colour. Sometimes the capsule is difficult to distinguish, and the parasite appears to lie within the corpuscle without sheath. The authors do not state whether it has any action on the host-cell.

11. **Hæmogregarina viperina** Billet, 1904, *emend.*

Bibliography.—Billet (2), Lühe (30).

Synonymy.—*Hæmogregarina viperini* Billet, 1904. *Karyolysus viperini* Lühe, 1906.

FIG. 50.

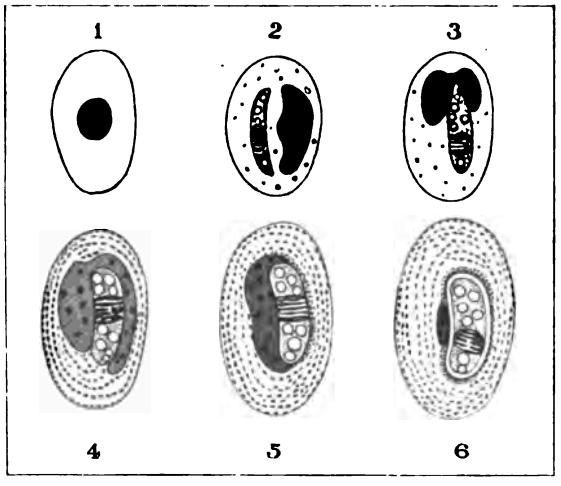

Hæmogregarina viperina. (After Billet.)

Hosts.—Schizogony in erythrocyte of the Viperine Snake, *Tropidonotus viperinus* Latr., in Algeria.

Description.—The youngest form is represented by an elongated vermicule presenting a nucleus more or less central and large round vacuoles in its cytoplasm. It attacks the nucleus of the host-cell, which becomes considerably hypertrophied and deformed. The hæmogregarine penetrates the nucleus and encysts within it. The erythrocyte becomes enlarged and dehæmoglobinised, and whilst the nucleus is being destroyed becomes speckled with red-staining granulations which arrange

themselves in concentric circles round the parasite and the remains of the nucleus. These granules are brought out by Romanowsky's method of staining, and, according to Billet, present an affinity with Schüffner's dots.

Observations.—The Viperine Snake inhabits Europe and North Africa.

12. **Hæmogregarina refringens** Sambon and Seligmann, 1907.

(Pl. XII, figs. 8–10.)

Bibliography.—Sambon and Seligmann (41), Manson (32).

Hosts.—Schizogony in erythrocytes of Hoary Snake, *Pseudaspis cana* L.

Fig. 51.

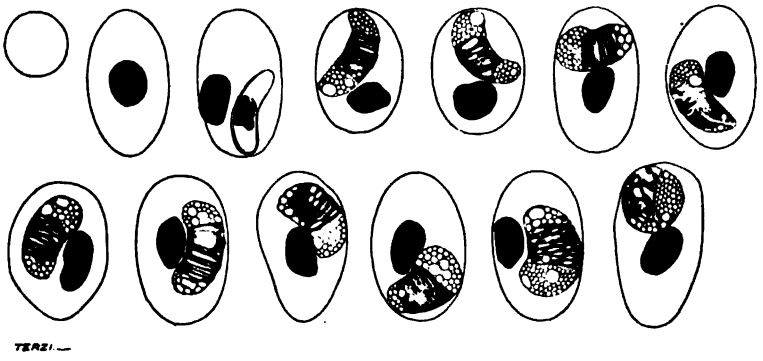

Hæmogregarina refringens.

Description.—Crescentic, bean-shaped, and discoidal forms occur. The slender crescentic forms have a long, oval, and more or less central nucleus. The bean-shaped forms measure 10 to 12 μ in length by 5 to 6 μ in width; they have a wide central nucleus, and their cytoplasm is literally crammed with rounded, highly refractive granules. Host-cell unaltered beyond occasional displacement of the nucleus.

Observations.—*Pseudaspis cana* is a South African snake. No ticks were found on any of the specimens examined. The one containing hæmogregarines presented also a few eelworms in its stomach.

13. **Hæmogregarina mansoni** Sambon and Seligmann, 1907.

(Pl. XIV, figs. 30–36).

Bibliography.—Sambon and Seligmann (41), Manson (32).

Hosts.—Schizogony in erythrocytes of testaceous snake, *Zamenis flagelliformis* L.

FIG. 52.

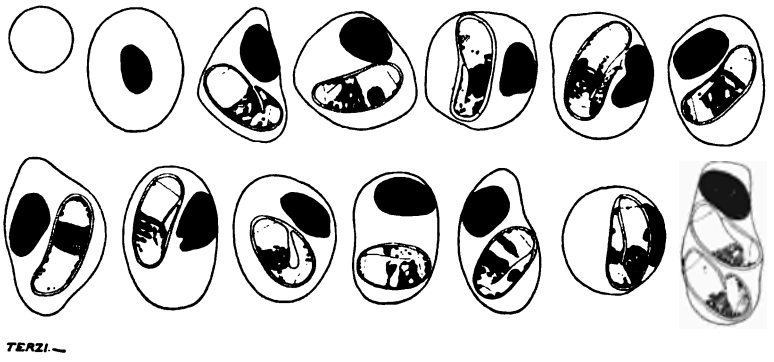

Hæmogregarina mansoni.

Description.—At first sight the hæmogregarines of the testaceous snake appear as oval or bean-shaped bodies, 12μ to 13μ long by 5μ to 6μ broad, surrounded by a thin clear zone.

FIG. 53.

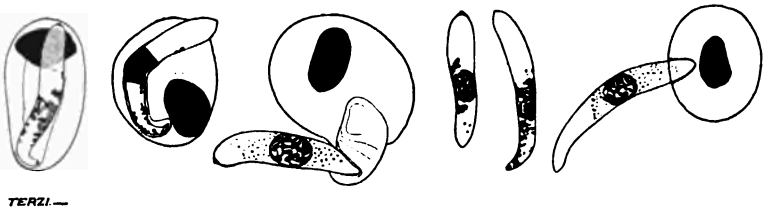

Hæmogregarina mansoni.—Sporonts escaping from their capsules and host-cells.

A more careful examination shows that the parasite is club-shaped and doubled-up in its capsule in the form of a loop, with both limbs of about equal length and closely applied. The nucleus, which appears to be placed at one end of the parasite, is really usually median, and situated at or near the bend.

The chromatin granules may be arranged in transverse parallel lines or in concentric circles. A characteristic of this hæmogregarine is the almost constant presence of two, rarely three or more, large cytoplasmic granules, which stain a deep blue with Leishman's stain and are placed one on each side of the nucleus.

The host-cell appears to be uninfluenced by the presence of the parasite. The nucleus may be slightly displaced.

Observations.—*Zamenis flagelliformis* inhabits the Southern United States and New Mexico. No ticks were found.

14. **Hæmogregarina zamenis** Laveran, 1902.

Bibliography.—Laveran (25).

Hosts.—Schizogony in erythrocytes of Horseshoe Snake, *Zamenis hippocrepis* (L.).

Description.—Laveran describes an early form in the develop-

FIG. 54.

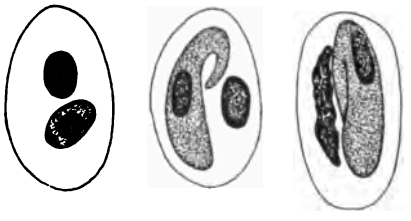

Hæmogregarina zamenis. (After Laveran.)

ment of this hæmogregarine. It is an ovalish body of about the size or slightly larger than the normal erythrocyte nucleus. In stained preparations it shows a central nucleus composed of chromatin granules. At this stage the parasite seems to have little or no action on its host-cell. Sometimes the erythrocyte nucleus may be slightly displaced.

The full-grown sporont is club-shaped, and measures, when doubled up, 18 μ in length, when free and extended 25 μ to 26 μ in length by 4 μ in breadth. Its long axis is usually parallel to the long axis of the erythrocyte, but the parasite may be placed obliquely or perpendicularly to the long axis of its host-cell. The nucleus of the hæmogregarine is always in the thicker

portion. The cytoplasm contains few chromatin granules. The host-cell is usually elongated, its nucleus is displaced and enlarged. It stains more deeply than the nuclei of normal erythrocytes.

Observations.—The Horseshoe Snake inhabits South Europe and North Africa.

15. **Hæmogregarina brumpti** Sambon, 1907.

Bibliography.—Manson (32).

Hosts.—Schizogony in erythrocytes of Mexican Snake, *Coluber melanoleucus*, Daud.

FIG. 55.

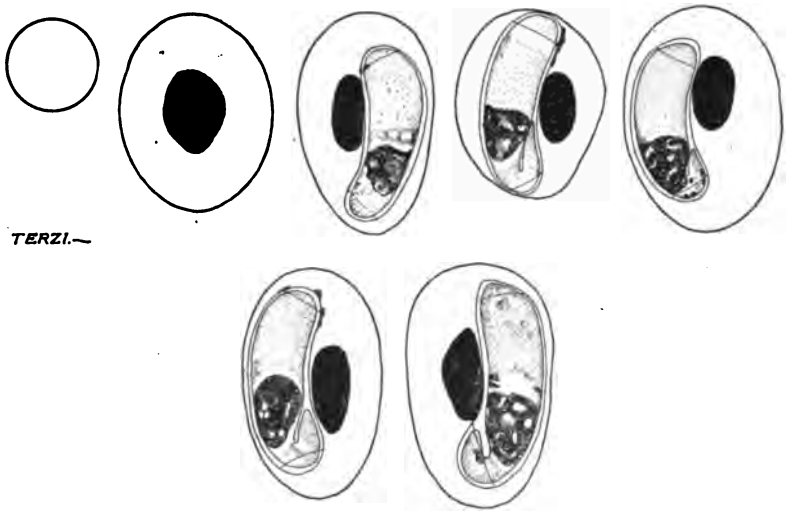

Hæmogregarina brumpti.

Description.—Only adult sporonts seen. They are enclosed within thick sausage-shaped capsules measuring 14 μ to 15 μ in length by 4 μ to 4·5 μ in breadth. The parasite within is distinctly club-shaped; its attenuated posterior extremity is recurved for a length of about 4 μ. The nucleus is situated anteriorly to the bend and measures 4 μ to 5 μ in length by 3·5 μ to 4 μ in breadth; its chromatin is frequently arranged in cross strands. The host cell never shows any signs of degeneration. Its nucleus is more or less displaced.

Observations.—The Mexican Snake inhabits North America and Mexico.

16. **Hæmogregarina colubri** Börner, 1901.

Bibliography.—Börner (4).

Hosts.—Schizogony both in erythrocytes and leucocytes of the Æsculapian Snake, *Coluber æsculapii,* Sturm. = *C. longissimus* Laur.

Description.—Youngest non-encapsuled forms 5·6 μ to 9·5 μ in length by about 1 μ in breadth. Encapsuled doubled-up forms about 18 μ in length. Both ends usually enlarge considerably,

FIG. 56.

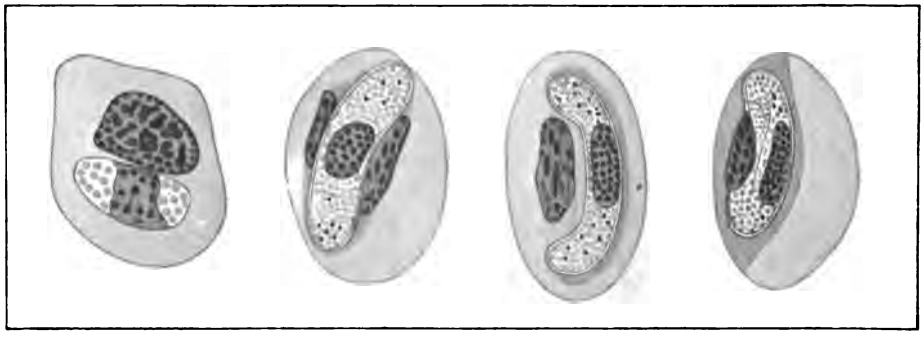

Hæmogregarina colubri. (After Börner.)

and the parasite thus assumes a characteristic haltere form. Sometimes only one extremity enlarges. The parasite is always closely adherent to the nucleus of the host-cell, which it ultimately fragments and destroys.

Observations.—The Æsculapian Snake inhabits Central Europe.

17. **Hæmogregarina rarefaciens** Sambon and Seligmann, 1907.

(Pl. XIII, figs. 17–21.)

Bibliography.—Sambon and Seligmann (41), Manson (32).

Hosts.—Schizogony in erythrocytes and leucocytes of Couper's snake, *Coluber corais* var. *couperi* Holbr.

Description.—The youngest forms observed are crescent-

shaped and measure from 10 μ to 11 μ in length by 1·5 μ to 3 μ in breadth. The nucleus is median and measures 3 μ to 5 μ in

FIG. 57.

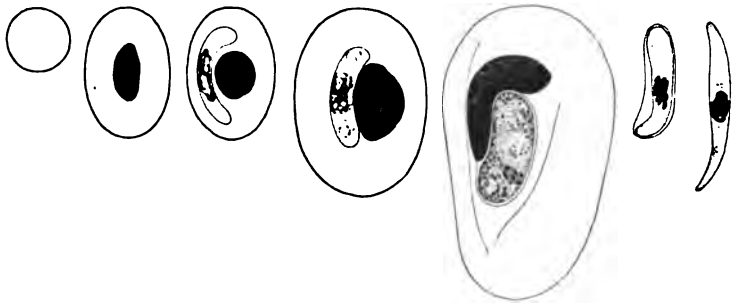

Hæmogregarina rarefaciens.

length by 1·5 μ to 3 μ in width. The host-cells containing them appear unaltered. A few adult sporonts were seen after escape

FIG. 58.

Hæmogregarina rarefaciens.

from their capsules and host-cells; they are slender, fusiform organisms measuring 20 μ to 23 μ in length by 2 μ to 2·5 μ in

width; their nucleus is median and measures 4 μ to 6 μ in length by 2 μ to 2·5 μ in breadth. The chromatin is usually broken up into about twelve granules. Only very few adult sporonts were seen within their capsules. The host-cells containing them show no signs of degeneration.

FIG. 59.

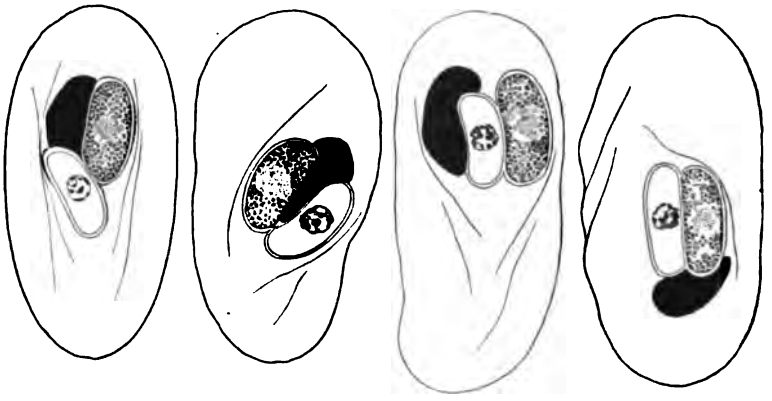

Hæmogregarina rarefaciens.—Double inclusions of forms presenting sex differentiation.

The full grown schizonts are large bean-shaped bodies measuring from 13 μ to 17 μ in length by 4 μ to 6 μ in width, they are enclosed in capsules somewhat larger and occupy as a rule erythrocytes which are enormously enlarged, completely dehæmoglobinised, and thinned out like wafers. These rarefied host-

FIG. 60.

Hæmogregarina rarefaciens developing within leucocyte.

FIG. 61.

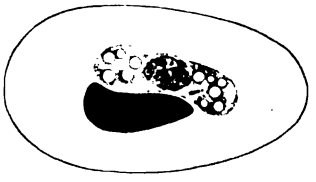

Hæmogregarina rarefaciens, vacuolated male schizont.

cells may attain in certain cases more than three times their normal size; as a rule they measure from 32 μ to 42 μ in length by 12 μ to 18 μ in width instead of the normal 16 μ by 11 μ. They stain a light pink colour with Giemsa's stain. The host-cell nucleus is greatly hypertrophied and stains a bright crimson

colour. It is always closely adherent to the parasite. Two forms are noticeable, one with dark staining granular cytoplasm and nucleus hardly visible, the other with pale cytoplasm and deeply staining nucleus. These two forms are very frequently associated within the same host-cell, and therefore are not merely due to differences in staining, but suggest sexual differentiation. The larger forms with pale staining cytoplasm frequently present round unstained areas or vacuoles, and round these or between them numerous deeply staining granules which probably represent the nuclei of future young merozoites. In some the nucleus is entirely broken up into very numerous minute granules. Occasionally the various forms occur in leucocytes, in which they seem to develop quite normally like the leucocyte-inhabiting hæmogregarines of the dog (*H. canis*), of the cat (*H. felis*), and of the rat (*H. muris*).

Observations.—The snake examined presented a most severe

FIG. 62.

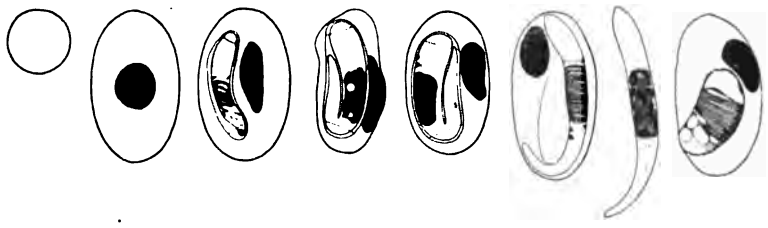

Hæmogregarina wardi.

infection; quite 80 per cent. of the erythrocytes were affected. The majority of parasites were schizonts, and double infections with these large forms were as numerous as single ones. No ticks were found.

Couper's snake is found over a wide area in America from the Southern United States to Brazil and Bolivia.

18. **Hæmogregarina wardi** Sambon, 1907.

Bibliography.—Manson (32).

Hosts.—Schizogony in erythrocytes of King Snake, *Coronella getula* (L.).

Description.—The full grown sporonts are folded into a U-shaped loop and enclosed within elongated capsules measuring 16 μ in length by 5 μ in breadth. The host-cell shows no sign

of degeneration either in the protoplasm or in the nucleus, which is usually pushed to one side. Out of their capsules the parasites measure from 24 μ to 25 μ in length by about 2 μ in width. Their nucleus, measuring 6 μ to 7 μ in length by 2 μ in breadth, is situated about the middle of the body, sometimes nearer to the anterior extremity, and stains very deeply.

Observations.—The hæmogregarine-infected specimen of King Snake examined was brought to the prosectorium a considerable time after death; its blood was literally teeming with putrefactive bacteria, and yet the hæmogregarines, the majority of which had escaped from their capsules and host-cells, were moving freely and actively in the blood plasma. A *Porocephalus* was found in

FIG. 63.

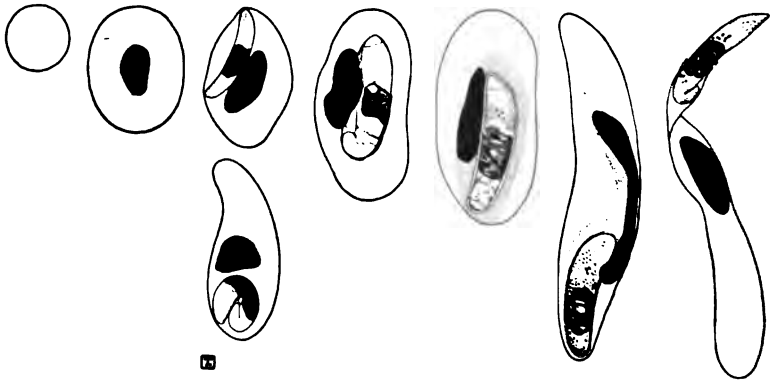

Hæmogregarina brendæ.

its body cavity. No ticks were found on any of the specimens examined. The King Snake inhabits North America.

19. **Hæmogregarina brendæ** Sambon and Seligmann, 1907.

Bibliography.—Manson (32).

Hosts.—Schizogony in erythrocytes of Hissing Sand Snake, *Psammophis sibilans* (L.).

Description.—Full grown forms more or less crescent-shaped and measuring 16 μ to 17 μ in length by 3 μ to 4 μ in breadth; their cytoplasm is granular and stains pale blue with Leishman's method. The nucleus is usually oval and placed about the middle of the body or nearer to the posterior extremity; it measures from 5 μ to 6 μ in length by 3 μ to 4 μ in breadth.

In specimens deeply coloured with Giemsa's stain the capsule can be seen very clearly, its contour and the opercular lines usually staining a deep crimson. The erythrocytes inhabited by this parasite become dehæmoglobinised and greatly elongated, their long diameter often attaining more than twice the normal length. The majority measure from 24 μ to 30 μ in length by 10 μ to 12 μ in breadth, whilst the normal corpuscles are from 15 μ to 16 μ long by 11 μ to 12 μ wide. The host-cell nucleus also becomes greatly elongated, and may measure 9 μ or even 12 μ instead of the normal 5 μ to 6 μ.

Observations.—The Hissing Sand Snake inhabits Tropical Africa and Egypt. No ticks were found. A *Kalicephalus* was present in the stomach of both specimens examined.

20. **Hæmogregarina joannoni** (Hagenmüller, 1898), Laveran, 1901.

Bibliography.—Hagenmüller (17), Laveran (27).

Synonymy.—*Danilewskya joannoni* Hagenmüller, 1898.

Hosts.—Schizogony in erythrocytes of *Macroprotodon cucullatus* Geoffroy.

Description.—The earliest or least developed forms measure about 8 μ and are slightly arched. They present an elongated nucleus 3·5 μ long, and two unequal extremities, one larger, rounded, the other attenuated and tapering. The host-cell is unaltered beyond a slight displacement of its nucleus. The parasite lies free in the stroma.

The fully-grown parasite is doubled up and enclosed in a transparent capsule. Its nucleus is situated in the wider portion, close to the bend. The host-cell presents profound alterations. It is greatly enlarged, especially in length. It may attain 23 μ to 24 μ in length by 12 μ to 13 μ in breadth, instead of the normal 18 μ by 13 μ. It becomes entirely dehæmoglobinised, its nucleus becomes elongated, attenuated, and frequently fragmented.

The fully-grown sporonts escape out of their capsules and fully outstretched measure 12 μ to 18 μ in length.

Hagenmüller also describes certain rarer forms which represent the cytocysts of the schizogonic stage. They have an elongated ovoid form, and fill the erythrocyte almost entirely. Their cytoplasm is one mass of granulations, and their nuclei present appearances indicative of segmentation.

Observations.—*Macroprotodon cucullatus* is found in South Europe and North Africa.

21. **Hæmogregarina bungari** (Billet, 1895) Labbé.

Bibliography.—A. Billet (1), Labbé (21).

Synonymy.—*Laverania bungari* Billet, 1895.

Hosts. — Schizogony erythrocytes of *Bungarus fasciatus* Schneider.

Description.—According to Billet, the most frequent form of this parasite is that of a crescent closely applied by its concave surface to the nucleus of the erythrocyte. Its length

FIG. 64.

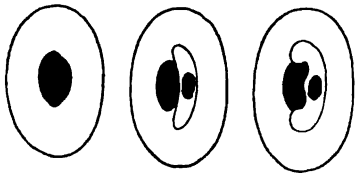

Hæmogregarina bungari. (After Billet.)

is about half that of the host-cell. Sometimes the parasite assumes a haltere shape similar to that of the avian parasites belonging to the genus *Hæmoproteus.*

Observations.—Billet found this hæmogregarine in two out of four specimens of *Bungarus fasciatus* examined at Cao-Bang, Upper Tongking, and states that the erythrocytes containing parasites were in the proportion of 1 in 30 or 40.

22. **Hæmogregarina najæ** Laveran, 1902.

Bibliography.—Laveran (25).

Hosts.—Schizogony in the erythrocytes of the Indian Cobra, *Naja tripudians* (Merr.).

Description.—According to Laveran, the hæmogregarine of *Naja tripudians* is club-shaped and presents an ovoid more or less elongated nucleus about the middle of its body. The doubled-up endo-corpuscular parasite measures about 14 μ in length, when free and fully outstretched it is 21 μ to 22 μ long by 3 μ broad at the wider, rounded end. The host-cell is, as a rule, somewhat enlarged, measuring 18 μ to 19 μ in its long diameter instead of the normal 17 μ. Its nucleus is displaced by the

enclosed parasite, but does not seem to undergo any alteration save perhaps a slight enlargement in some cases.

Having had the opportunity of examining the hæmogregarine-infected blood of an Indian cobra, one of us (L. W. S.) found not only the forms described by Laveran but also the reproductive forms of the schizogonic stage.

The doubled-up parasites vary in length between 13 μ and 17 μ and measure about 4 μ in breadth. Their nucleus is not exactly median, but nearer the posterior extremity. It is not really oval, but more or less cone-shaped with base anterior and extending the whole breadth of the parasite. In length it varies between 3·5 μ and 6 μ. The posterior end of the parasite tapers to a point and is recurved. The recurved attenuated portion is closely applied to the body. The parasite is enclosed

FIG. 65.

Hæmogregarina najæ. (After Laveran.)

in a thin, transparent capsule, which seems to have escaped Laveran's notice. The host-cell is at times slightly enlarged; its nucleus, always displaced by the parasite, appears to undergo no change.

The other form, not described by Laveran, is enclosed within a capsule more or less bean-shaped measuring 14 μ to 15 μ in length by 6 μ to 7·5 μ in breadth. The capsule is thick and prevents a clear view of the enclosed parasite. The only thing visible is the nucleus, which in stained specimens shows at one end of the capsule as a small roundish skein of chromatin stained a light pink. A few chromatic granules may be seen scattered through the cytoplasm. The host-cell enclosing this form is greatly altered. It is always enlarged and may attain 25 μ in length by 14 μ in breadth. It is completely dehæmoglobinised and often takes a pale pink coloration in stained specimens. Its nucleus, always closely adherent to the parasite, is elongated,

attenuated, and frequently fragmented. It stains a deeper colour than normal.

Observations.—The Indian cobra is found in Southern Asia from Transcaspia to China and the Malay Archipelago. No ticks

FIG. 66.

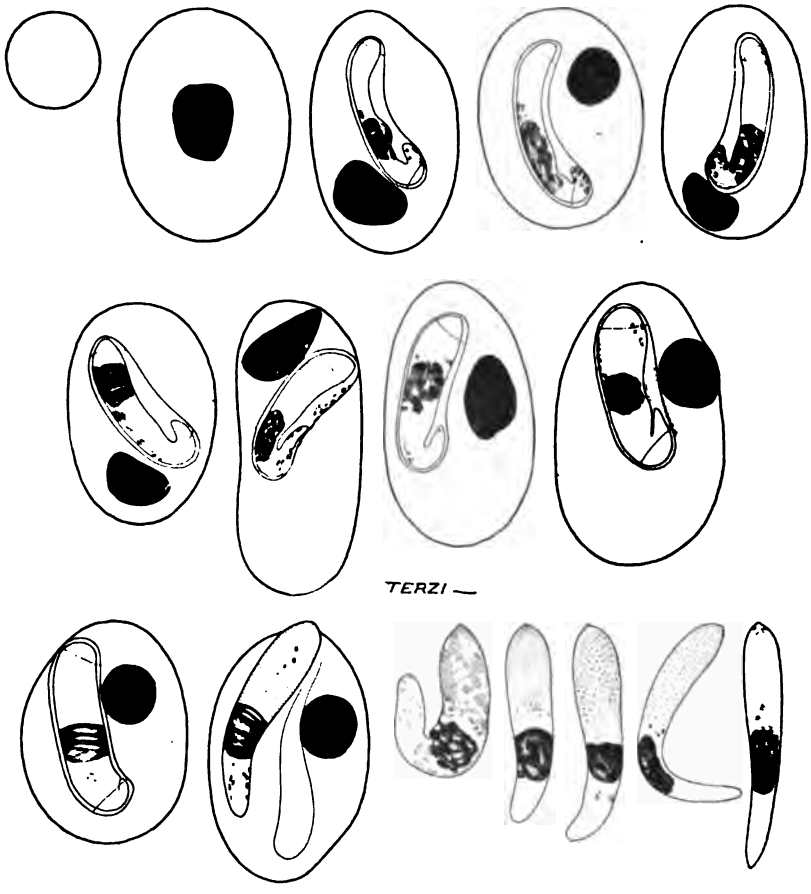

Hæmogregarina samboni. (After Giordano.)

were found on the two specimens examined, but *Aponomima gervaisi* is known to occur.

23. **Hæmogregarina samboni** Giordano, 1907.

Bibliography.—Manson (32).

Hosts.—Schizogony in erythrocytes of Black Viper, *Vipera aspis* (L.).

Descriptions.—The full grown sporonts are enclosed within sausage-shaped capsules measuring 14 μ to 15 μ in length by 4 μ to 6 μ in breadth. Parasite within, club-shaped, with anterior extremity rounded and blunt and the posterior narrow, tapering, and re-curved for a length of 3 μ to 4 μ. The nucleus varies considerably in its position and in the arrangement of its chromatin. As a rule it is median, but sometimes it is nearer to the posterior extremity about the region of bend; in rare cases it approaches the anterior extremity. The capsule is thick and quite visible, its contour stains a bright crimson by the Giemsa method. Not infrequently one or both opercular lines take the stain. The host-cell shows no signs of degeneration. The position of the parasite within varies considerably.

After escape from their capsules, the sporonts measure 18 μ to

FIG. 67.

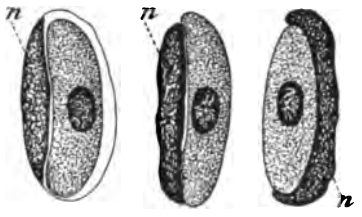

Hæmogregarina mocassini. *n.* Host-cell nucleus. (After Laveran.)

22 μ in length by 3·5 μ to 4 μ in maximum width. Their posterior extremity tapers to a blunt point. The nucleus is usually in the posterior half of the body whilst the anterior extremity presents, in stained specimens, a stippling of minute pink granules.

Observations.—The black viper occurs in southern Europe and Sicily. *Hæmaphysalis punctata* is so far the only tick recorded from this snake.

24. **Hæmogregarina mocassini** Laveran, 1902.

Bibliography.—Laveran (25).

Hosts.—Schizogony in erythrocytes of the Water Viper, *Ancistrodon piscivorus* (Lacép.).

Description.—Young forms slender, none re-curved. The fully grown endoglobular forms are folded and measure 12 μ to 17 μ in length. When free and fully outstretched they measure 20 μ to 25 μ. Not infrequently two parasites may be found in the

same host-cell. The affected erythrocyte is frequently elongated; its nucleus is displaced and may be flattened, but is rarely hypertrophied.

Observations.—The Water Viper inhabits North America.

25. **Hæmogregarina seligmanni** Sambon, 1907.

(Pl. XIV, figs. 24–28.)

Bibliography.—Manson (32).

Hosts.—Schizogony in erythrocytes of Bushmaster, *Lachesis mutus* (L.).

Description.—The youngest forms seen in the blood of the general circulation are already encapsuled and measure from 14 μ to 17 μ in length by 2 μ to 4 μ in maximum breadth; they are slender, slightly arched, conical bodies with a central nucleus

FIG. 68.

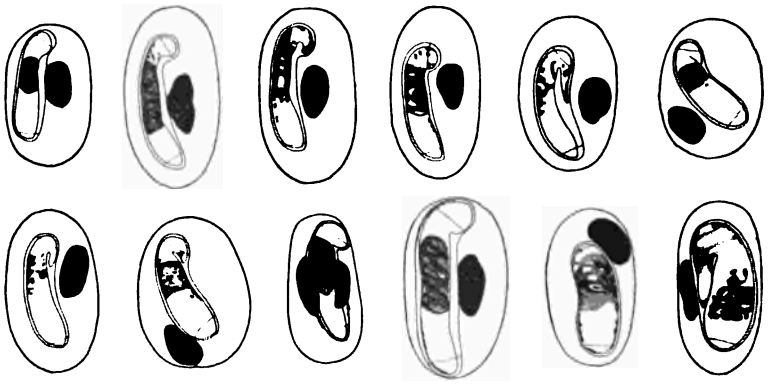

Hæmogregarina seligmanni, young sporonts.

measuring 6 μ to 8 μ in length by 2 μ to 4 μ in width. The host-cells containing them are in no way altered, their nuclei retain the normal position, the parasite usually lying on one side with its long axis parallel to that of the corpuscle.

The adult sporonts are enclosed within capsules of very uniform size, measuring about 16 μ in length by 6 μ in width. The capsules are quite transparent but plainly visible, especially in specimens stained by the Giemsa method, in which both contour and cleavage lines assume a bright crimson colour. The opercular lines are usually at from 1·5 μ to 2 μ from the

extremities of the capsule. The parasite within forms a U-shaped loop with branches of unequal thickness. The posterior more slender limb is either as long or longer than the thicker anterior one; in the latter case the exceeding portion is bent back and interposed between the two branches. The nucleus is always in the anterior limb at about the seat of bend and measures 5 μ in length by 3 μ in width. A few deeply staining granules may be seen scattered about in the cytoplasm, usually in the posterior half of the body. The host-cell shows

FIG. 69.



Hæmogregarina seligmanni, full grown sporonts.

no signs of degeneration, but its nucleus is displaced, being pushed to one side by the large encapsulated parasite.

After escaping from their capsules and host-cells, the free sporonts appear as graceful, elongated, conical organisms measuring from 40 μ to 52 μ in length by 3 μ to 4 μ in maximum width. Their nucleus is usually median and measures 5 μ to 8 μ in length by 3 μ to 4 μ in width; it stains deeply, and its chromatin is usually broken up into rods or granules. Numerous dark-staining granules may be seen in the posterior half of the body. No sex differentiation is to be observed, all the sporonts are exactly alike. The capsules burst as a rule longitudinally,

and their two halves roll up exactly like the seed-pods of certain plants, forming rod-shaped scrolls which may be seen in the plasma lying either parallel or crosswise with remains of the disintegrated host-cell nucleus about them.

The fully grown schizonts are large, bean-shaped bodies measuring 16 μ to 17 μ in length by 6 μ to 7 μ in width; they are enclosed within large tough capsules measuring 18 μ to 21 μ in length by 7 μ to 9 μ in width. Their cytoplasm is literally crammed with plastin spherules, and they are provided with a large central nucleus measuring 4 μ to 4·5 μ in length by 6 μ to

Fig. 70.

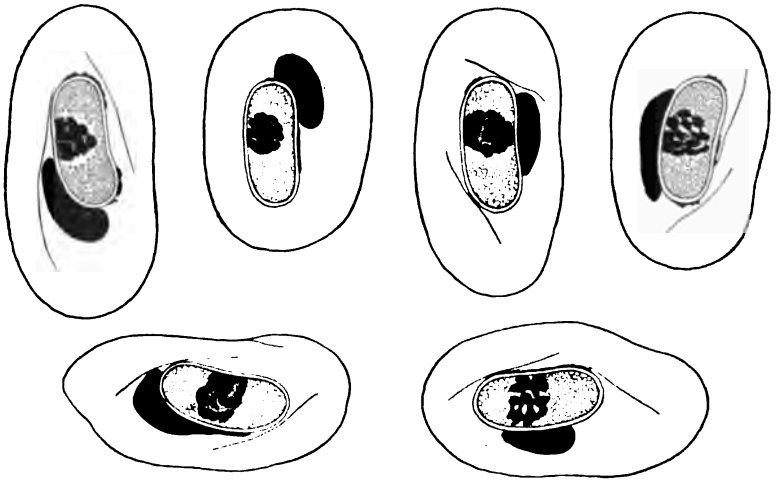

Hæmogregarina seligmanni. Schizonts in pre-segmenting stage.

7 μ in width. Its chromatin is usually divided into twelve or eighteen roundish masses. The host-cell is always greatly enlarged and rarefied, measuring 30 μ to 42 μ in length by 16 μ to 20 μ in width; it is completely dehæmoglobinised, and is of a light crimson colour in specimens stained by the Giemsa method. Its nucleus is greatly hypertrophied and is adherent to the capsule of the parasite.

Observations.—The snake examined presented a very heavy infection. The majority of the forms were adult sporonts and readily escaped from their capsules and host-cells in all those preparations which were not immediately fixed or dried. In blood kept for some time *in vitro*, many of the free sporonts

were seen to associate two by two; in several cases the posterior extremities of the coupled organisms seemed fused and during movement described together the same curves. Nuclear fusion was not seen and it is doubtful whether true plastogamy occurred. Numerous double inclusions were observed, the parasites being either in the same or in different stages of development. Occa-

FIG. 71.

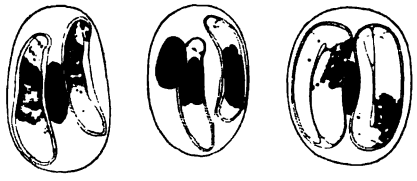

Hæmogregarina seligmanni, double inclusions.

sionally three parasites were found within the same host-cell. Notwithstanding the heaviness of the infection comparatively few schizonts were found and in every case only one in each host-cell.

The examination of the organs revealed nothing further. Numerous specimens of *Porocephalus crotali* were found in the lungs and body-cavity.

The Bushmaster inhabits Central and Tropical America.

26. **Hæmogregarina plimmeri**, n. sp.

Hosts.—Schizogony in erythrocytes of the Rat-tailed Snake, *Lachesis lanceolatus* (Lacép.).

FIG. 72.

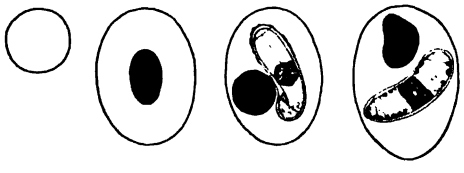

Hæmogregarina plimmeri.

Description.—The full grown sporonts are enclosed within thick sausage-shaped capsules, measuring 14 μ to 15 μ in length by 4 μ to 4·5 μ in breadth, and presenting dark coarse granules when stained by the Giemsa method. The parasite within is distinctly club-shaped and presents a thicker rounded anterior extremity and a conical posterior extremity, re-curved for a

length of about 4 μ. Its nucleus is more or less median and measures 4 μ in length by 3·5 μ to 4 μ in breadth; it stains deeply and its chromatin may be either arranged in cross strands or broken up into granules. The host-cell shows no signs of degeneration, its nucleus is usually displaced.

Observations.—The Rat-Tailed Serpent or Fer-de-lance inhabits Tropical America.

27. **Hæmogregarina crotali** Laveran, 1902.

Bibliography.—Laveran (25), Lühe (30).

Synonymy.—*Karyolysus crotali* Lühe, 1906.

Hosts.—Schizogony in erythrocytes of the Pacific Rattlesnake, *Crotalus confluentus.*

FIG. 73.

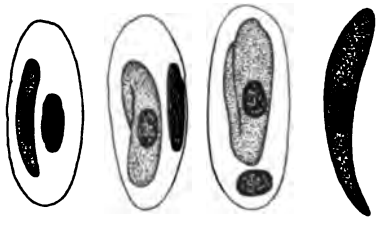

Hæmogregarina crotali. (After Laveran.)

Description.—According to Laveran, *H. crotali* does not appear to fold itself up within its host-cell. The largest forms measure 15 μ to 16 μ in length by 5 μ to 6 μ in breadth. Their nucleus, so far as can be judged from the figures, is small, oval, and median. The nucleus of the host-cell becomes greatly hypertrophied; it may attain 16 μ and even 18 μ in length. It is closely applied to the parasite and remains attached to it even after complete disruption of the erythrocyte. It stains more deeply than the nuclei of normal erythrocytes.

Observations.—The Pacific Rattlesnake inhabits Western North America from British Columbia to the South of California, Dakota, Nebraska, Kansas, West and South Texas, North Mexico.

LITERATURE.

1. *Billet, A.*—"Sur les Hématozoaires des Ophidiens du Haut Tonkin," 'C. R. d. l. Soc. Biol.,' Paris, January 19th, 1895.
2. *Billet, A.*—"Sur une Hémogrégarine Karyolysante de la Couleuvre vipérine," *loc. cit.*, Paris, 1904, T. 56, pp. 484, 485.

3. *Billet, A.*—"*Trypanosoma inopinatum* de la Grenouille Verte d'Algeria et sa relation possible avec les *Drepanidium*," *loc. cit.*, Paris, 1904, vol. lvii, pp. 161–165.
4. *Börner, C.*—"Untersuchungen über Hämosporidien, I Ein Beitrag zur Kenntniss des genus *Hæmogregarina* Danilewsky," 'Zeitschr. f. wiss. Zool.,' Bd. lxix, Hft. 3, pp. 398–416.
5. *Brumpt, E.*—"Contribution à l'étude de l'Évolution des Hémogrégarines et des Trypanosomes," 'C. R. Soc. Biol.,' Paris, 1904, vol. lvii, pp. 165–167.
6. *Brumpt, E.*—"De l'Hérédite des infections à trypanosomes et a trypanoplasmes chez les hôtes intermédiaires," *loc. cit.*, Paris, 1907.
7. *Castellani, A., and Willey, A.*—"Observations on the Hæmatozoa of Vertebrates of Ceylon," 'Spolia zeylanica,' vol. ii, part 6, pp. 78–92.
8. *Celli, A., and Sanfelice, F.*—"Sui parassiti del globulo rosso nell'uomo e negli animali contributo all'emoparassitologia comparata," 'Annali di Agricoltura Roma,' 1891.
9. *Chaussat*, J. B.—"Des Hematozoaires," 'Thèse,' Paris, 1850.
10. *Christophers, S. R.*—"*Hæmogregarina gerbilli*," 'Scientific Mem. India,' 1905, No. 18.
11. *Christophers, S. R.*—"The Sexual Cycle of *Leucocytozoon canis* in the Tick," *loc. cit.*, 1907, No. 28.
12. *Danilewsky, B.*—"Die Hematozoen der Kaltblüter," 'Arch. f. Mikr. Anat.,' 1885, vol. xxiv.
13. *Danilewsky, B.*—"La Parasitologie comparée du Sang," II, 'Recherches sur les Hematozoaires des tortues,' Kharkoff, 1889.
14. *Durham, H. E.*—'Report of the Yellow Fever Expedition to Parà of the Liverpool School of Tropical Medicine and Medical Parasitology,' Liverpool, 1902, pp. 78, 79.
15. *Dutton, J. E., Todd, J. L., and Tobey, E. N.*—"Concerning certain Parasitic Protozoa observed in Africa," 'Annals of Trop. Med. and Parasitology,' Liverpool, 1907.
16. *Gaule, J.*—"Ueber Würmchen, welche aus den Froschblut-Korperchen auswandern," 'Arch. f. Anat. u. Phys.,' Phys. absts., 1880, pp. 57–64.
17. *Hagenmüller, P.*—"Sur les hémosporidies d'un ophidien du système Européen," 'Arch. de zool. expér. et génér.,' sér. 3, t. vi; 'Notes et Revue,' No. 4, pp. 51–56.
18. *James, S. P.*—"On a Parasite found in the White Corpuscles of the Blood of Dogs," 'Scientific Mem. India,' 1905, No. 14.
19. *Johnson, H. P.*—"A New Sporozoan Parasite of Anopheles," 'The Journal of Medical Research,' Boston, 1902, vol. vii, pp. 213–219.
20. *Labbé, A.*—"Recherches zoologiques et biologiques sur les parasites endoglobulaires du sang des vertébrés," 'Arch. de Zool. expér.,' 1894, third series, vol. ii, pp. 55–258.
21. *Labbé, A.*—"Sporozoa," 'Das Tierreich,' Berlin, 1899, vol. xx, p. 180.
22. *Langmann, G.*—"On Hæmosporidia in American Reptiles and Batrachians," 'New York Medical Journal,' 1892.
23. *Lankester, E. Ray.*—"On Undulina, the Type of a New Group of Infusoria," 'Quart. Journ. of Micr. Sci.,' 1871, pp. 387–389.
24. *Lankester, E. Ray.*—"On *Drepanidium ranarum*, the Cell-parasite of the Frog's Blood and Spleen," *loc. cit.*, January, 1882, New Series, pp. 53–65.

25. *Laveran, A.*—"Sur quelques Hémogrégarines des Ophidiens," 'C. R. de l'Acad. des Sci.,' Paris, t. 135, No. 23, pp. 1036–1040.

26. *Laveran, A.*—"Contribution à l'étude de *Hæmogregarina stepanovi* Danilewsky," 'C. R. d. l. Soc. Biol.,' Paris, 1898, vol. v, pp. 885–889 and 912–921.

27. *Laveran, A.*—"Essai de Classification des Hématozaires endoglobulaires," *loc. cit.*, 1901, vol. liii, pp. 798–801.

28. *Laveran, A., and Nègre.*—"Sur un Protozoaire Parasite de *Hyalomma ægyptium*," *loc. cit.*, 1905, vol. lviii, pp. 964–966.

29. *Lebailly, C.*—"Recherches sur les Hématozoaires Parasites des Téléostiéns Marins," 'Arch. de Parasitologie,' Paris, 1906, t. x, pp. 348–403.

30. *Lühe, Max.*—"Die in Blute schmarotzenden Protozoen und ihre nächsten verwandten," in Mense's 'Handbuch der Tropenkrankheiten,' vol. iii, Leipzig, 1906.

31. *Lutz, A.*—"Üeber die Drepanidien der Schlangen, Ein Beitrag. zur Kenntnis der Hämosporidien," 'Centralbl. f. Bakter., etc., I Abtlg.,' Bd. xxix, No. 9, pp. 390–398.

32. *Manson, Sir Patrick.*—'Tropical Diseases,' 4th edition, London, 1907; see appendix on "Classification of the Blood-inhabiting Protozoa," by Sambon.

33. *Marceau, F.*—"Note sur le *Karyolysus lacertarum*, parasite endoglobulaire du sang des Lézards," 'Arch. de parasit.,' Paris, 1901, vol. iv, pp. 135–142.

34. *Neveu-Lemaire, M.*—'Les Hématozoaires du Paludism,' Paris, 1901.

35. *Nicolle, C., and Comte, C.*—"Sur le Rôle possible de *Hyalomma ægyptium* dans l'infection hæmogrégarinienne de *Testudo mauritanica*," 'C. R. d. l. Soc. Biol.,' Paris, 1905, vol. lviii, pp. 1045, 1046.

36. *Patton, W. S.*—"On a Parasite found in the White Corpuscles of the Blood of Palm Squirrels," 'Scientific Mem. India,' Calcutta, 1906, No. 24.

37. *Pfeiffer, L.*—"Beitrage zur Kenntniss der Pathogenen gregarinen; IV, Gregarinen formen innerhalb der Blutzellen bei Schildkroten, Eidechsen, Vogeln, und von Malaria-krankheiten," 'Zeitschr. f. Hyg.,' viii, 1890.

38. *Prowazeck, V.*—"Untersuchungen über Hämogregarinen," 'Arb. a. d. Kaiserl. Gesundheitsamte,' vol. xxvi, part i, 1907, pp. 32–36.

39. *Robertson, M.*—"Notes on certain Blood-Inhabiting Protozoa," 'Proc. R. Phys. Soc. Edinburgh,' 1906, vol. xvi, pp. 232–247.

40. *Sambon, C. W., and Low, G. C.*—"Report on Two Experiments on the Mosquito-Malaria Theory, instituted by the Colonial Office and the London School of Tropical Medicine," 'Medico-Chirurgical Trans.,' London, 1901, vol. lxxxiv, pp. 497–552.

41. *Sambon, L. W., and Seligmann, C. G.*—"Description of Five New Species of Hæmogregarines from Snakes," 'Proc. Zool. Soc.,' 1907.

42. *Schaudinn, F.*—"Generations- und Wirtswechsel bei *Trypanosoma* und *Spirochæte*," 'Arb. a. d. Kaiserl. Gesundheitsamte,' 1904, vol. xx, pp. 387–439.

43. *Siegel.*—"Die geschlechtliche Entwicklung von *Hæmogregarina stepanovi* im Rüsselegel *Placobdella catenigera*," 'Arch. f. Protistenkunde,' 1903, vol. ii, pp. 339–342, with note by F. Schaudinn.

44. *Simond, P. L.*—"Contribution à l'étude des hématozoaires endoglobulaires des reptiles," 'Ann. de l'Inst. Pasteur,' vol. xv, pp. 319–351.

July, 1908.

EXPLANATION OF PLATE XII,

Illustrating the communication on "The Hæmogregarines of Snakes," by Dr. L. W. Sambon and Dr. C. G. Seligmann. (P. 310.)

FIGS. 1–7.—Sporonts of *Hæmogregarina pococki*. Parasite of the Indian Python, *Python molurus*, L.

FIGS. 8–10.—Schizonts of *Hæmogregarina refringens*. Parasite of the Hoary Snake, *Pseudaspis cana*, L.

FIGS. 11–16.—Sporonts of *Hæmogregarina shattocki*. Parasite of the Diamond Snake, *Python spilotes* (Lacép).

EXPLANATION OF PLATE XII,

[illegible]ing the communication [illegible] "The Haemogregarines of [illegible]kes," by Dr. L. W. S[illegible]on and Dr. C. G. Schgmann. [illegible]. 310.)

[illegible] 1–7.—S[illegible]nts of *H[illegible]rina po[illegible]ki*. Parasite of the Indian [illegible]a, *Python m[illegible]ticus*, L[illegible]

[illegible] 8–1[illegible] [illegible]ments of [illegible] *[illegible]ation refringens*. Parasite of the Heavy [illegible], *P[illegible] spe[illegible]ana*, [illegible]

[illegible] 11–16. Sporoz[illegible] [illegible]*mogregarina sh[illegible]ki*. Parasite of the Diamond [illegible]ake, *Python sebae*, [illegible]

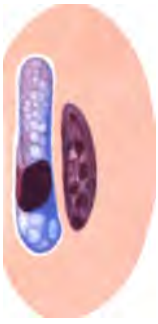

Fig 1

Fig 2

Fig 3

Fig 4

Fig 5.

Fig 6

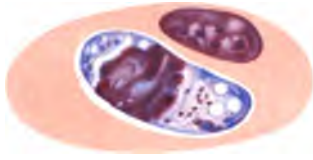

Fig 7

Fig 8.

Fig 9

Fig 10

Fig 11

Fig 12.

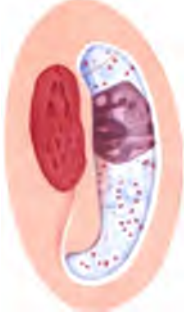

Fig 13

Fig 14.

Fig 15

Fig 16

EXPLANATION OF PLATE XIII,

Illustrating the communication on "The Hæmogregarines of Snakes," by Dr. L. W. Sambon and Dr. C. G. Seligmann. (P. 310.)

FIGS. 17–21.—*Hæmogregarina rarefaciens.* Parasite of Couper's snake, *Coluber corais* var. *couperi*, Holbr. 17. Young sporont. 18 and 19. Male schizonts. 20. Two male schizonts in the same erythrocyte. 21. Double inclusion of male and female forms.

FIGS. 22, 23.—*Hæmogregarina seligmanni.* (See also Plate XIV.) Parasite of Bushmaster, *Lachesis mutus.* 22. Sporont with spireme arrangement of chromatin. 23. Sporont with extremities apparently fusing.

EXPLANATION OF PLATE XIII,

Illustrating the communication on "The Haemogregarines of Snakes," by Dr. [illegible] W. Sambon and Dr. C. G. Schermann. (P. 310.)

FIGS. 17–21. - *Haemogregarina coronatus*. Parasite of Cooper's snake, *Coluber [illegible]* var. *[illegible]*. 17. Young sporont. 18 and 19. Male schizonts. 20. Two male s[illegible] in the same erythrocyte. 21. Double inclusion of male and fem[illegible].

FIGS. 22, 23. [illegible] *Haemogregarina schigmanni*. (See also Plate XIV.) Parasite of Bushm[illegible] *Lachesis mutus*. 22. Sporont with spireme arrangement of chromatin. [illegible] Sporont with extremities apparently fusing.

Fig 17

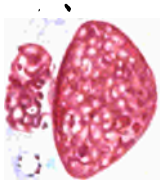

Fig. 18

Fig 19

Fig 20

Fig 21

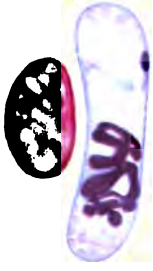

Fig 22

Fig 23

A. Bloch Photo.

Tuth Anst. W.H.A. Fraser Edinburgh.

EXPLANATION OF PLATE XIV,

Illustrating the communication on "The Hæmogregarines of Snakes," by Dr. L. W. Sambon and Dr. C. G. Seligmann. (P. 310.)

FIGS. 24–29.—*Hæmogregarina seligmanni* (and Plate XIII, figs. 22, 23). Parasite of Bushmaster, *Lachesis mutus*. 24. Full-grown sporont. 25 and 26. Double inclusions. 27. Sporont escaping from host-cell. 28. Free sporont.

FIGS. 30–36.—*Hæmogregarina mansoni*. Parasite of testaceous snake, *Zamensis flagelliformis*, L. 30–35. Full-grown sporont. 36. Free sporont.

EXPLANATION OF PLATE XV,

Illustrating the communication on "The Hæmogregarines of Snakes," by Dr. L. W. Sambon and Dr. C. G. Seligmann. (P. 310.)

FIGS. 37–42.—*Hæmogregarina terzii.* Parasite of Common Boa, *Boa constrictor*, L. 37 and 38. Young forms. 39–41. Full-grown sporonts. 42. Long slender form within erythroblast.

FIGS. 43–50.—*Hæmogregarina cantliei.* Parasite of Conical Eryx, *Eryx conicus.* 43–47. Sporonts. 48. Double inclusion. 49 and 50. Free sporonts.

EXPLANATION OF PLATE XV,

Illustrating the communication on "The Haemogregarines of Snakes," by Dr. L. W. Sambon and Dr. C. G. Seligmann. (P. 310.)

FIGS. 37–42.—*H. [illegible] [illegible]*. Parasite of Common Boa, *Boa constrictor*, E. 37 and 38. Young forms. 39–41. Full-grown sporonts. 42. Long slender form within erythroblast.

FIGS. 43–50.—*Haemogregarina [illegible]*. Parasite of Conical Eryx, *Eryx conicus*. 43–47. Sporonts. 48. Double inclusion. 49 and 50. Free sporonts.

Fig. 37.

Fig. 38.

Fig. 39.

Fig. 40.

Fig. 41.

Fig. 42.

Fig. 43.

Fig. 44.

Fig. 45.

Fig. 46.

Fig. 47.

Fig. 48.

Fig. 49.

Fig. 50.

INDEX.

SUBJECTS.

(*For List of Authors see p. 372.*)

PAGE

ADRENALS, the activity of, in relation to blood-pressure (P. R. Parkinson) 187
AXIS, lateral fractures of (E. M. Corner) 78

BLOOD-CORPUSCLES, red, of mammals, origin of (C. E. Walker) . . 99
BLOOD-CORPUSCLES, red, centrosomes and other structures in (R. Ross, F.R.S., J. E. S. Moore, and C. E. Walker) . . . 107
BLOOD, fatty degeneration of (S. G. Shattock and L. S. Dudgeon) . 227
BONE disease, fœtal (F. S. Dawe) 59
BRAIN, osteo-lipoma of base of (F. P. Weber and P. Daser) . . 219

CARCINOMA, primary, of male urethra (S. G. Shattock) . . 199
CHORION-EPITHELIOMA of testis (T. W. P. Lawrence) . . 1
CHORION-EPITHELIOMA of testis (J. M. Bernstein) . . . 4
CHORION-EPITHELIOMA of congenital origin (V. Bonney) . . 9
CYSTINURIA, with diamines (F. H. Thiele) . . . 255

DEGENERATION, fatty, of blood (S. G. Shattock and L. S. Dudgeon) . 227
DIAMINES, with cystinuria (F. H. Thiele) 255

EMBRYOMA, ovarian; with remarks on the pathogenesis of the so-called dermoid cyst of the ovary (S. G. Shattock) . . . 267
ENDOCARDITIS, influenzal, diagnosed by blood culture (T. J. Horder) . 265

FRACTURES, lateral, of the axis (E. M. Corner) . . . 78

HÆMOGREGARINOSIS IN SNAKES (L. W. Sambon and C. G. Seligmann) . 311

JENSEN'S MOUSE-TUMOUR (W. R. Williams) . . . 38

MOUSE-TUMOUR, Jensen's (W. R. Williams) 38
MYOCARDIUM, calcareous change in (W. O. Meek) . . . 183

OSTEO-LIPOMA of base of brain (F. P. Weber and P. Daser) . . 219
OVARY, so-called dermoid cyst of, remarks upon the pathogenesis of (S. G. Shattock) 267

PARATHYROID GLANDS in man (W. L. Harnett) . . . 128
PARATHYROID GLANDS in man (D. Forsyth) . . . 154
PLEURISY, eosinophilic (J. J. Perkins and L. S. Dudgeon) . . 119

SARCOMA, round-celled, of stomach (N. Dalton) . . . 61
SPHINCTERS, pathology of (E. M. Corner) 42
STOMACH, round-celled sarcoma of (N. Dalton) . . . 61
SULPH-HÆMOGLOBINÆMIA, (A. E. Russell) 177

TESTIS, chorion-epithelioma of (J. M. Bernstein) . . . 4

PAGE

TYPHOID FEVER, a case of, diagnosed on the eighth day by blood culture in the absence of the agglutination reaction (T. J. Horder) . . 263

URETHRA, male, primary carcinoma of (S. G. Shattock) . . 199

WEEVER FISH, the poison of (H. M. Evans) 63

AUTHORS.

BERNSTEIN (J. M.), chorion-epithelioma of testis . . . 4

BONNEY (V.), chorion-epithelioma of congenital origin. . . 9

CORNER (E. M.), pathology of the sphincters 42

„ „ lateral fractures of the axis 78

DALTON (N.), round-celled sarcoma of stomach . . . 61

DASER (P.) : see *Weber* (*F. P.*).

DAWE (F. S.), fœtal bone disease 59

DUDGEON (L. S.) : see *Perkins* (*J. J.*).

„ „ see *Shattock* (*S. G.*).

EVANS (H. M.), the poison of the weever fish 63

FORSYTH (D.), the parathyroid glands in man . . . 154

HARNETT (W. L.), a histological study of the human parathyroid glands 128

HORDER (T. J.), a case of typhoid fever diagnosed by blood culture in the absence of the agglutination reaction 263

„ „ a third case of influenzal endocarditis diagnosed by blood culture 265

LAWRENCE (T. W. P.), chorion-epithelioma of testis . . . 1

MEEK (W. O.), calcareous change in the myocardium . . . 183

MOORE (J. E. S.) : see *Ross* (*R.*).

PARKINSON (P. R.), the activity of the adrenals in relation to blood-pressure 187

PERKINS (J. J.) and **DUDGEON** (L. S.), a case of eosinophilic pleurisy . 119

ROSS (R.), (F.R.S.), **MOORE** (J. E. S.), and **WALKER** (C. E.), centrosomes and other structures in red blood-corpuscles of vertebrates . . 107

RUSSELL (A. E), a case of sulph-hæmoglobinæmia . . . 177

SAMBON (L. W.), and **SELIGMANN** (C. G.), hæmogregarinosis in snakes . 311

SELIGMANN (C. G.) : see *Sambon* (*L. W.*).

SHATTOCK (S. G.), primary carcinoma of the male urethra . . 199

„ „ and **DUDGEON** (L. S.), fatty degeneration of the blood . 227

„ „ ovarian embryoma, with remarks on the pathogenesis of the so-called dermoid cyst of the ovary . . . 267

THIELE (F. H.), cystinuria with diamines 255

WALKER (C. E.), origin of the red blood-corpuscles in mammals . 99

„ „ see *Ross* (*R.*).

WEBER (F. P.) and **DASER** (P.), osteo-lipoma of base of brain . . 219

WILLIAMS (W. R.), Jensen's mouse-tumour 38

ADLARD AND SON, IMPR., LONDON AND DORKING.